

Epidemiology, Treatment, and Prevention of Lumbar Spine Injuries in Major League Baseball Players

Christopher L. Camp, MD, Matthew S. Conti, BS, Terrance Sgroi, PT, Frank P. Cammisa, MD, and Joshua S. Dines, MD

Abstract

In recent years, increased attention has been paid to injuries occurring in Major League Baseball (MLB) players. Although most of the current orthopedic literature regarding baseball injuries pertains to the shoulder and elbow, lumbar spine injuries are another common reason for time out of play. Back and core injuries may represent as many as 12% of all injuries that result in time out of play from MLB. This high rate of injury is likely related to the critical role that the spine plays in every major baseball-related movement. Linking the upper extremities to the hips and lower extremities, a healthy, strong, and stable spine and core is a prerequisite for performance in all levels of baseball. It has been well documented that baseball players with poor spinal control and stabilization are at increased risk for future injury. Common etiologies of lumbar injuries include stress fractures, muscle injury, annular tears with or without disc herniation, facet joint pain, sacroiliac joint pain, and stenosis. This review discusses the epidemiology of spinal injuries in baseball. Special attention is paid to the role of the spine in baseball-related activities, common injuries, tips for making the correct diagnosis, treatment options, outcomes, rehabilitation, and injury prevention.

For the last 20 years, injuries resulting in time out of play have been on the rise in Major League Baseball (MLB), and those affecting the back are no exception.^{1,2} In the first comprehensive report on injuries in MLB players, back injuries

resulted in a mean of 1016 disabled list days per season from 1995 to 1999.¹ Similarly, core and back injuries were responsible for 359 disabled list designations from 2002 to 2008. This represented 11.7% of all injuries resulting in time out of play during that time span.² During that time, back injury prevalence ranked 6th highest of all possible body regions (out of 17), and both position players and pitchers were similarly affected (7.8% and 7.4% of all injuries, respectively).² These injuries often result in a significant time out of play and can have a tremendous impact on player health. A healthy, stable, and well-functioning lumbar spine is a prerequisite for nearly all baseball-related activities, including pitching, throwing, batting, and running. Accordingly, even minor lumbar spine injuries may profoundly influence baseball performance. Despite this, less is currently known about the true epidemiology and impact of back injuries in professional baseball compared to other professional sporting organizations.³

The most common causes of low back pain and injury in elite baseball players include muscle strains, stress fractures (spondylolysis), annular tears, disc herniation, stenosis, transverse process fractures, facetogenic pain, and sacroiliac (SI) joint arthropathy.⁴⁻⁸ These injuries present in a variety of ways with varying symptomatology. Accordingly, a thorough understanding and comprehensive approach to the diagnosis and treatment of these in-



Authors' Disclosure Statement: The authors report no actual or potential conflict of interest in relation to this article.

juries is necessary. The purpose of this article is to discuss the current state of lumbar spine injuries in professional baseball players. Specifically, we will discuss the critical role of the spine in baseball activities, common causes of injury, tips for making the diagnosis, treatment options, outcomes, and injury prevention and rehabilitation strategies.

Role of the Spine in Baseball

The spine and core musculature are responsible for positioning the head, shoulders, and upper extremities in space over the hips and lower extremities. Proper maintenance of this relationship is required during all phases of throwing, pitching, running, and hitting. During these activities, the spine may dynamically flex, extend, rotate, and laterally bend as needed to keep the body balanced with the head centered over the trunk.

Pitching and Throwing

Whether pitching from the wind-up or the stretch, the head begins centered over the hips and pelvis. As the pitching motion progresses, the hips undergo rotation, flexion, extension, abduction, and circumduction. While this is occurring, the shoulders and upper trunk must bend, rotate, and translate toward home plate with the body. Just prior to front foot contact, trunk rotation averages $55 \pm 6^\circ$ with a maximal mean angular acceleration of $11,600 \pm 3100^\circ/s^2$.⁹ In order for the body to remain balanced, controlled, and synchronized throughout this delivery, the lumbar spine and core musculature must

work diligently to stabilize the entire kinetic chain. Of all the trunk muscles (paraspinal, rectus abdominis, obliques, and glutei), the lumbar paraspinal muscles often work the hardest during the pitching motion, demonstrating activity increases ranging from 100% to 400%.¹⁰ Accordingly, it is not uncommon for pitchers to develop SI joint or lumbar facet joint pain due to this high degree of torsional strain exerted on the low back.⁴ Poor lumbopelvic control has been shown to be a predictor of subsequent injury, and the degree of lumbopelvic dysfunction is proportional to injury severity in MLB pitchers.⁵

Hitting

Similar to pitching, hitting involves a complex combination of movements from the upper and lower extremities that must be balanced by the core and spine. Although numerous movements occur simultaneously, rotational motion is primarily responsible for generating power. The trunk rotates an average of $46 \pm 9^\circ$ during the swing and reaches a maximal angular acceleration of $7200 \pm 2800^\circ/s^2$ just after contact.⁹ During this period of rapid torsion, the spine must rotate in conjunction with the hips and shoulders to create a stable cylinder and axis of rotation. The spine and core are responsible for synchronizing rotation to ensure that hip and shoulder parallelism is maintained from swing initiation to ball contact. If the body does not rotate as a unit, the position of the head is affected and the batter's ability to see the ball may be compromised. Additionally, if delivery of the shoulders

lags too far behind that of the hips, the position of the hands (and bat) in space is adversely affected. The entire kinetic chain must remain balanced, coordinated, precisely timed, and standardized throughout the entire swing from initial trigger to final follow-through. The lumbar spine plays a critical role in each of these steps. If lumbar spine mechanics are not sound, this can have significant adverse effects on batting performance and may predispose hitters to injury.⁴

Common Etiologies for Spinal Injury

The vast majority of baseball players who experience lumbar

Table. Common Lumbar Injuries in Baseball

Etiology	Typical Features
Stress fracture/spondylolysis	Common in athletes undergoing repetitive back extension Present in up to one-third of athletes with low back pain Best diagnosed with bone scan
Muscle injury	Generally follows acute, inciting event May have history of prior, similar injuries
Annular tears/disc herniation	Result from combined compressive and rotatory forces Pain can be severe and radiating If disc protrusion progresses, radicular symptoms may follow
Facet joint pain	Facet joints are typically injured during rotation of the extended back Pain often reproduced by loading facet joint (back extension)
Sacroiliac joint pain	Presents with deep pain localized to sacroiliac joint Often associated with ankylosing spondylitis and human leukocyte antigen B27
Stenosis	Often presents with slowly progressive pain +/- radicular symptoms Athletes with congenital stenosis may be at increased risk for injury

pain will have injuries that can be classified as mechanical back pain (ie, spondylolysis, annular tears, facetogenic pain, SI joint arthropathy, or muscle injuries) (**Table**). Although less likely to occur, nerve entrapment or impingement syndromes (ie, disc herniation, stenosis, and peripheral nerve entrapment) have been observed in professional baseball players. Finally, more concerning pathologies such as infection and tumor are extremely rare, but they must not be overlooked in this high-demand patient population.

Stress Fracture or Spondylolysis

In young athletic patients, up to one-third of those with low back pain may have evidence of a lumbar stress fracture on bone scan.^{11,12} This is particularly true for athletes who undergo repetitive lumbar extension and rotation, such as linemen, gymnasts, wrestlers, weight lifters, and baseball players.^{4,13} Although the majority of lumbar stress fractures occur at the pars interarticularis, they can occur in the pedicle or articular process (**Figure 1**). Most spondylolytic lesions do not progress to spondylolisthesis, especially once patients reach skeletal maturity. Because the fifth lumbar vertebra represents the transition from the lumbar to the sacral spine, most stress fractures occur at L5. These typically present as localized low back pain that worsens with flexion, extension, and rotation.

Muscle Injury

One of the most common causes of low back pain in athletes is muscle strains and spasms. Because the lumbar paraspinal muscles are extremely active during throwing and hitting,¹⁰ they are particularly susceptible to injury. This is particularly true in deconditioned athletes or those who report to spring training having not adequately maintained strength and flexibility through the off-season.^{4,5} These injuries typically present in an acute fashion with an obvious inciting incident. Players may have a history of similar muscle injuries in the past. On examination, they tend to have difficulty maintaining normal posture or ranging the spine through a full arc of motion. Localized, superficial tenderness to palpation in the injured muscle is a key component of the diagnosis.

Annular Tears and Disc Herniation

These injuries typically occur as the result of a combination of compressive and rotary forces on the lumbar spine that overcome the ability of the annulus fibrosus to resist hoop stresses. Patients with annular tears typically present with severe

lower back pain that may be accompanied by spasm and pain radiation into the buttock or lower extremities. Pain is usually worsened by valsalva, coughing, sneezing, or bearing down.⁴ Although annular tears can occur in isolation, they can also lead to herniation of the nucleus pulposus into the spinal canal (**Figure 2**). Depending on the location and severity of the herniation, nerve entrapment or impingement can occur. This may initially present as pain that radiates into the lower extremities in a dermatomal fashion. As the herniation progresses, decreased sensation and weakness may develop.

Facet Joint Pain

Facetogenic pain can occur as the result of degenerative changes, trauma, or joint inflammation. Facet injury typically occurs during rotation while the back is extended.⁴ This results in localized pain and tenderness that can be reproduced by loading the facet joint (lumbar extension) during the examination, and patients will often demonstrate discomfort and altered motion when extending the flexed back.

Sacroiliac Joint Pain

Although pain in the region of the SI joint is very common, much of this may actually be referred from more centrally located neuromotion segments.⁴ SI joint pathology can occur as a result of trauma, degeneration, or inflammatory processes as is seen in ankylosing spondylitis (AS). Patients with AS typically present with a gradual onset of progressive stiffness and pain in the low back and hips that is worse in the morning or following periods of inactivity. It is most common in Caucasian males in their second to fourth decades.¹⁴ Although 80% to 95% of patients with AS

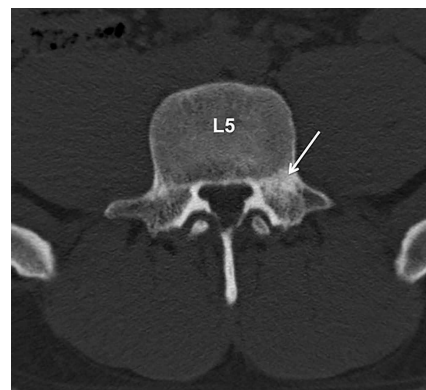


Figure 1. Axial computed tomography scan of a professional baseball player with low back pain. This imaging confirms a stress fracture of the left L5 pedicle (white arrow).

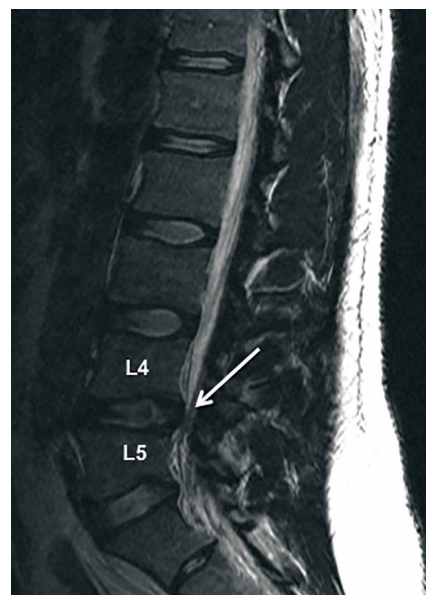


Figure 2. Magnetic resonance imaging of a professional baseball player with low back pain and radicular symptoms into the left leg. Herniation of the L4-5 disc is evident, resulting in significant stenosis at that level (white arrow).

will test positive for human leukocyte antigen B27 (HLA-B27), it is important to note that the vast majority of people with HLA-B27 do not go on to develop AS.¹⁴ Regardless of the cause, SI joint pain can be very debilitating and negatively impact all baseball-related activities.

Stenosis

Lumbar stenosis may develop from arthritic changes, disc protrusion, facet hypertrophy, or ligament ossification. In this young, athletic population, congenital stenosis should also be a consideration. Patients with congenital stenosis at baseline are at increased risk for developing neurologic symptoms from disc protrusion or other acquired spinal pathology. Lumbar stenosis generally manifests as a gradual onset of progressive low back pain with radicular symptoms or neurogenic claudication.⁴

Making the Diagnosis

History

When identifying the cause of any musculoskeletal complaint, the diagnosis begins with a thorough history. In addition to the standard components of the history, such as timing, severity, relation to activity, exacerbating factors, associated symptoms, and prior treatments, Watkins and colleagues⁴ have outlined a number of key factors that should be determined when specifically evaluating the athlete with low back pain. These include quantification of the morbidity, identification of contributing psychosocial factors, ruling out of urgent diagnoses (ie, neoplasm, infection, rapidly progressive neurologic deficits, cauda equina, and paralysis), determination of injury type and duration, identification of the clinical syndrome/etiology, pinpointing the location of the pathology (what nerve at what level?), and quantification of back versus leg symptoms. Answers to these questions will set the framework for an appropriately directed physical examination, imaging, and diagnostic tests.

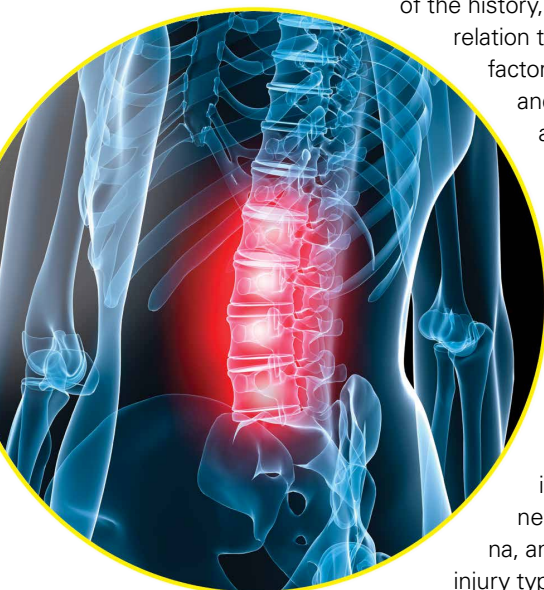Physical Examination

The physical examination begins by observing the patient or player walk across the playing field, train-

ing room, or examination room, paying attention to posture, gait, and overall body movement. Many patients with lumbar injuries will demonstrate adaptive patterns of motion in an attempt to accommodate their pain. This may be seen during baseball-related activities such as throwing, batting, or running. The spine should be visualized and palpated for malalignment while standing erect and during forward bending. If possible, motion should be assessed in rotation, lateral bending, and the flexion and extension planes. Special attention should be paid to any positions or maneuvers that reproduce pain or neurologic symptoms. Areas of tenderness and radiating pain should be fully palpated. A full neurologic examination consisting of manual muscle testing, sensory examination, and reflex evaluation of both the upper and lower extremities should be performed. Numerous special tests and neurologic stretch maneuvers that assess specific lumbar nerve roots have been described.¹⁵

Imaging and Diagnostic Tests

Depending on the history and physical examination, imaging of the lumbar spine is not always warranted in the acute setting. This is especially the case if muscle injury, herniation, or annular tears are suspected. In cases of persistent pain, trauma, or suspected neoplasia, imaging is generally warranted. When x-rays are negative and spondylolysis is suspected, bone scan with lumbar single photon emission computed tomography (SPECT) is the most sensitive test.¹⁶ SPECT scans are positive in active spondylolysis because the radio-nucleotide is taken up by active, bone-forming osteoblasts. Quiescent stress fractures that are not apparent on SPECT scans are generally chronic and painless.⁴ If the SPECT scan is positive, the injury can be further characterized by computed tomography (CT) (Figure 1), which can distinguish between spondylolysis, osteoid osteoma, osteoblastoma, acute fracture, or arthritic degeneration. When the SPECT is negative, or if neural impingement is suspected, magnetic resonance imaging (MRI) (Figure 2) is likely the best diagnostic imaging tool. MRI allows identification of bone edema, disc herniation, annular disruption, disc desiccation, stenosis, and nerve entrapment. Finally, when attempting to distinguish between central and peripheral nerve entrapment syndromes, an electromyogram (EMG) or nerve conduction study (NCS) is a reliable way to identify the location of injury.



Treatment and Outcomes

The approach to a patient with low back pain begins with identification of the etiology and discontinuation of the activities that reproduce pain.⁴ Trunk stabilization exercises and anti-inflammatory medications are the mainstays of treatment regardless of the cause of the lumbar spinal injury in the baseball player.⁴

Stress Fracture or Spondylolysis

Management of symptomatic spondylolysis or spondylolisthesis in the athlete initially consists of conservative treatment, which achieves good to excellent long-term outcomes and return to play in 70% to 90% of athletes, especially for acute injuries.¹⁷⁻¹⁹

After stopping the activity that causes the pain, trunk stabilization exercises should be started as soon as tolerated with the use of non-steroidal anti-inflammatory medications (NSAIDs), oral steroids, and spinal injections to control symptoms and permit initiation of the rehabilitation program.⁴ Although bracing is a commonly used adjunctive treatment, a recent meta-analysis did not demonstrate any difference in clinical outcomes between patients treated with a brace compared to non-braced controls.²⁰

Surgical indications for the treatment of spondylolysis or spondylolisthesis are limited; however, failure of nonoperative treatment after 6 months is a reasonable time to consider surgery.¹⁷ The spondylolytic defect can often be repaired directly using hook screws, translaminar screws, wiring, pedicle screws, or image-guided lag screws across the lesion with grafting.⁴ Lumbar spinal fusion is less successful in professional athletes due to the high demands placed on adjacent levels as well as the time required for the fusion to heal.⁴ Bony union can be determined by a CT scan at 6 months postoperatively if the patient has met appropriate return to play criteria.⁴

Muscle Injury

Management of lumbar sprains and strains typically includes restricting painful postures and a rehabilitation program that focuses on core strengthening within a pain-free arc of motion.²¹ Because acute injuries typically resolve quickly and spontaneously, a short interval of decreased activity, icing, NSAIDs, and stretching followed by focused strength training is appropriate before return to sports activity.²²

Annular Tears and Disc Herniation

Initial management of baseball players with acute lumbar disc herniation and/or annular tears con-

sists of rest for up to 5 days followed by physical therapy and NSAIDs, Medrol Dose pak, or epidural injections.⁴ Professional baseball players return to play at high rates following a herniated lumbar disc.⁶ Earhart and colleagues⁶ found that 97.1% of players returned to play at an average time of 6.6 months from the time of injury. When stratified by position, all pitchers (29 of 29) returned to competitive play after operative or nonoperative management, while 38 of 40 hitters returned.⁶ The average career length after lumbar disc herniation in the professional baseball player is between 4.1 and 5.3 years or between 256 and 471 games.^{6,23} Other work has suggested that players undergoing operative treatment for lumbar herniation had shorter career lengths; however, patients in the operative group tended to be older at the time of injury.²³

Emphasis should be placed on nonoperative management of baseball players with disc pathology except in cases of cauda equina syndrome.⁴ Hitters and pitchers who require surgery have demonstrated decreased 1-year and 3-year postoperative statistical performance compared to preinjury levels.⁶ No significant changes in any performance statistic were seen in baseball following nonoperative management.⁶ Consequently, indications for surgery in the baseball player with lumbar disc pathology includes cauda equina syndrome, progressive neurologic deficit, sufficient morbidity, failure of conservative care, a lesion that can be corrected safely with surgery, and the ability for the patient to comply with a comprehensive postoperative rehabilitation program.⁴ Operative treatment typically consists of a lumbar microdiscectomy and/or laminotomy.^{4,6}

Facet Joint Pain

The mainstay of therapy in patients with facet joint pain consists of analgesia and a trunk stabilization program.²⁴ Lumbar zygapophysial joint injections and radiofrequency denervation can be considered if the patient fails 4 weeks of directed conservative treatment.^{24,25} Injections may be useful in select patients; however, the literature supporting the use of lumbar facet joint injections or radiofrequency denervation for facetogenic pain is limited.^{24,25}

Sacroiliac Joint Pain

Acute injury of the SI joint can be treated with NSAIDs, icing, and relative rest.²⁶ Mobilization of the SI joint in addition to correcting any asymmetries in muscle length or stiffness should be started and progressed as soon as tolerated within

a pain-free range of motion.²⁶ Rehabilitation should correct biomechanical deficits and maladaptation with a special focus on agonist and antagonist muscle groups across the sacrum and ilium.²⁶ Treatment of AS in the athlete should emphasize symptom control, as there is no definite treatment. For patients with AS, other long-term therapeutic options include sulfasalazine, methotrexate, thalidomide, and anti-tumor necrosis factor therapies.¹⁴

Stenosis

Lumbar spinal stenosis, whether congenital or acquired, should initially be managed conservatively.²⁷ Although they do not alter the progression of the disease, epidural steroids and local injections may temporarily decrease symptoms in approximately 40% of cases.²⁷ Those who fail conservative therapy after 3 months may be candidates for surgical decompression and/or fusion.^{27,28} However, surgical treatment for lumbar spinal stenosis in elite baseball players has not been thoroughly studied, so the long-term prognosis is not well documented.²⁷

Rehabilitation and Prevention of Injuries

After an appropriate diagnosis has been made, a structured rehabilitation process should commence. During rehabilitation, it is of primary importance that deep core stabilization is established. As an initial step in this process, athletes are trained to initiate deep core stabilization with breathing techniques in a static, supine position.²⁹ Proper diaphragm activation with co-contractions of the transverse abdominis (TA) and pelvic floor has been shown to increase lumbar spine stability.³⁰ This will allow for an increase in intra-abdominal pressure (IAP) and improved stabilization of the lumbar spine, creating a muscular cylinder between the bottom of the rib cage and top of the pelvis. These activities are initiated in the supine position but are soon advanced as upper and lower extremity movement against resistance is added. It is important to make sure IAP and contraction of the TA is maintained throughout this sequence of progression.

Once deep core stabilization has been established, athletes are progressed to global muscle training and kinetic linking in all 3 planes of movement. This is an important phase, as lumbar stability is a result of coordinated muscle activation involving many muscles.³¹ This program progresses from supine breathing exercises to a modified

side bridge position to enhance core activation along with frontal plane stability. Next, athletes are progressed to a half kneeling position and then on to standing. Rotational activities are introduced starting with isometric holds progressing to chops/lifts and rotational medicine ball toss. During these tasks, focus should be on quality of movement and maintenance of core activation. Endurance of these muscles should be trained during this process. Appropriate pain-free and safe cardiovascular exercise, such as walking, biking, swimming, and jogging, should be performed throughout each stage in the rehabilitation process. Activities should be halted with any increase in pain. At the completion of the rehabilitation process, it is important to observe the athlete while performing sport-specific tasks. Spinal stabilization must be translational and monitored by observing maintenance of the "cylinder" from the training room to sports specific movements.

Since poor lumbar control has been associated with increased amount of time on the disabled list,⁵ it would be ideal to identify those at risk of injury before problems arise. Conte and colleagues³² have shown that core muscle strains could be a result of muscle imbalance or improper pitching or hitting technique. Other work has demonstrated that pitchers with poor lumbopelvic control did not perform as well as those with superior control.³³ By assessing spinal stability and biomechanics at baseline, we may be able to identify those at risk. Pitchers with suboptimal spinal stabilization can present with an unstable balance phase, increased amounts of hyperextension of the lumbar spine from the moment of max cocking through ball release, as well as increased lateral trunk tilt at ball release. Correcting these flaws and increasing deep core stabilization can prevent injuries and improve performance.

Summary

A stable, well-functioning lumbar spine is vital to nearly every baseball-related activity, including pitching, throwing, batting, fielding, and running. The spine serves as a critical link in the kinetic chain between the upper and lower extremities. Due to the high demand on the lumbar spine, injuries to this area represent a significant amount of time out of play in MLB. Initial treatment typically consists of a comprehensive nonoperative rehabilitation process involving analgesics, rest, and therapy focusing on core stabilization. Because poor lumbopelvic control and mechanics have been demonstrated to increase injury risk,

preemptive spinal and core stabilization is likely an appropriate step towards injury prevention.

Dr. Camp is Sports Medicine Fellow, Sports Medicine and Shoulder Service, Hospital for Special Surgery, New York, New York. Mr. Conti is a medical student, Weill Cornell Medical College, New York, New York. Mr. Sgroi is a Physical Therapist, Sports Medicine and Shoulder Service, Hospital for Special Surgery, New York, New York. Dr. Cammisa is Attending Orthopedic Surgeon, Spine Service, Hospital for Special Surgery, New York, New York. Dr. Dines is Associate Professor of Orthopedic Surgery, Weill Cornell Medical College, Sports Medicine and Shoulder Service, Hospital for Special Surgery, New York, New York.

Address correspondence to: Joshua S. Dines, MD, Hospital for Special Surgery, 535 East 70th Street, New York, NY 10021 (tel, 516-482-1037; fax, 516-482-9217; email, dinesj@hss.edu).

Am J Orthop. 2016;45(3):137-143. Copyright Frontline Medical Communications Inc. 2016. All rights reserved.

References

- Conte S, Requa RK, Garrick JG. Disability days in major league baseball. *Am J Sports Med.* 2001;29(4):431-436.
- Posner M, Cameron KL, Wolf JM, Belmont PJ, Owens BD. Epidemiology of Major League Baseball injuries. *Am J Sports Med.* 2011;39(8):1676-1680.
- Makhni EC, Buza JA, Byram I, Ahmad CS. Sports reporting: a comprehensive review of the medical literature regarding North American professional sports. *Phys Sportsmed.* 2014;42(2):154-162.
- Watkins RG III, Watkins RG IV. Chapter 36: Lumbar injuries. In: *Sports Medicine of Baseball.* Dines JS, Altchek DW, Andrews JR, ElAttrache NS, Wilk KE, Yocum LA, eds. Philadelphia, PA: Lippincott Williams & Wilkins; 2012; 383-398.
- Chaudhari AMW, McKenzie CS, Pan X, Oñate JA. Lumbopelvic control and days missed because of injury in professional baseball pitchers. *Am J Sports Med.* 2014;42(11):2734-2740.
- Earhart JS, Roberts D, Roc G, Gryzlo S, Hsu W. Effects of lumbar disk herniation on the careers of professional baseball players. *Orthopedics.* 2012;35(1):43-49.
- Hamid KS, Nwachukwu BU, Hsu E, Edgerton CA, Hobson DR, Lang JE. Orthopedic resident work-shift analysis: Are we making the best use of resident work hours? *J Surg Educ.* 2014;71(2):205-210.
- Nair R, Kahlenberg CA, Hsu WK. Outcomes of lumbar discectomy in elite athletes: the need for high-level evidence. *Clin Orthop Relat Res.* 2015;473(6):1971-1977.
- Fleisig GS, Hsu WK, Fortenbaugh D, Cordover A, Press JM. Trunk axial rotation in baseball pitching and batting. *Sports Biomech.* 2013;12(4):324-333.
- Watkins RG, Dennis S, Dillin WH, et al. Dynamic EMG analysis of torque transfer in professional baseball pitchers. *Spine (Phila Pa 1976).* 1989;14(4):404-408.
- Micheli LJ. Back injuries in gymnastics. *Clin Sports Med.* 1985;4(1):85-93.
- Papanicolaou N, Wilkinson RH, Emans JB, Treves S, Micheli LJ. Bone scintigraphy and radiography in young athletes with low back pain. *AJR Am J Roentgenol.* 1985;145(5):1039-1044.
- Elliott S, Hutson MA, Wastie ML. Bone scintigraphy in the assessment of spondylolysis in patients attending a sports injury clinic. *Clin Radiol.* 1988;39(3):269-272.
- Kubiak EN, Moskovich R, Errico TJ, Di Cesare PE. Orthopaedic management of ankylosing spondylitis. *J Am Acad Orthop Surg.* 2005;13(4):267-278.
- Miller KJ. Physical assessment of lower extremity radiculopathy and sciatica. *J Chiropr Med.* 2007;6(2):75-82.
- Bellah RD, Summerville DA, Treves ST, Micheli LJ. Low-back pain in adolescent athletes: detection of stress injury to the pars interarticularis with SPECT. *Radiology.* 1991;180(2):509-512.
- Radcliff KE, Kalantar SB, Reitman CA. Surgical management of spondylolysis and spondylolisthesis in athletes: indications and return to play. *Curr Sports Med Rep.* 8(1):35-40.
- Morita T, Ikata T, Katoh S, Miyake R. Lumbar spondylolysis in children and adolescents. *J Bone Joint Surg Br.* 1995;77(4):620-625.
- Hu SS, Tribus CB, Diab M, Ghanayem AJ. Spondylolisthesis and spondylolysis. *J Bone Joint Surg Am.* 2008;90(3):656-671.
- Klein G, Mehlman CT, McCarty M. Nonoperative treatment of spondylolysis and grade I spondylolisthesis in children and young adults: a meta-analysis of observational studies. *J Pediatr Orthop.* 2009;29(2):146-156.
- Bono CM. Low-back pain in athletes. *J Bone Joint Surg Am.* 2004;86-A(2):382-396.
- Dreisinger TE, Nelson B. Management of back pain in athletes. *Sports Med.* 1996;21(4):313-320.
- Hsu WK, McCarthy KJ, Savage JW, et al. The Professional Athlete Spine Initiative: outcomes after lumbar disc herniation in 342 elite professional athletes. *Spine J.* 2011;11(3):180-186.
- Dreyfuss PH, Dreyer SJ; NASS. Lumbar zygapophysial (facet) joint injections. *Spine J.* 2003;3(3 Suppl):50S-59S.
- Slipman CV, Bhat AL, Gilchrist R V, Issac Z, Chou L, Lenrow DA. A critical review of the evidence for the use of zygapophysial injections and radiofrequency denervation in the treatment of low back pain. *Spine J.* 2003;3(4):310-316.
- Prather H. Sacroiliac joint pain: practical management. *Clin J Sport Med.* 2003;13(4):252-255.
- Graw BP, Wiesel SW. Low back pain in the aging athlete. *Sports Med Arthrosc.* 2008;16(1):39-46.
- Melancia JL, Francisco AF, Antunes JL. Spinal stenosis. *Handb Clin Neurol.* 2014;119:541-549.
- Frank C, Kobesova A, Kolar P. Dynamic neuromuscular stabilization & sports rehabilitation. *Int J Sports Phys Ther.* 2013;8(1):62-73.
- Cholewicki J, Juluru K, McGill SM. Intra-abdominal pressure mechanism for stabilizing the lumbar spine. *J Biomech.* 1999;32(1):13-17.
- McGill SM, Grenier S, Kavcic N, Cholewicki J. Coordination of muscle activity to assure stability of the lumbar spine. *J Electromyogr Kinesiol.* 2003;13(4):353-359.
- Conte SA, Thompson MM, Marks MA, Dines JS. Abdominal muscle strains in professional baseball: 1991-2010. *Am J Sports Med.* 2012;40(3):650-656.
- Chaudhari AMW, McKenzie CS, Borchers JR, Best TM. Lumbopelvic control and pitching performance of professional baseball pitchers. *J Strength Cond Res.* 2011;25(8):2127-2132.