

Medical management of abnormal uterine bleeding in reproductive-age women

Appropriate clinical evaluation, laboratory assessment, and management can make the difference for many women with AUB, and avoid surgery in most cases

Andrew M. Kaunitz, MD, NCMP; Deanna C. McCullough, MD; and Erin H. Burnett, MD

IN THIS ARTICLE

Clinical evaluation

page 32

Transvaginal ultrasonography

page 33

Medical treatment options

page 34

CASE 1 Multiparous woman presents with heavy regular menses

Over the past several years, a 34-year-old woman has noted increasing intensity and duration of menstrual flow, which now persists for 8 days and includes clots “the size of quarters” and soaks a pad within 1 hour. Sometimes she misses or leaves work on her heaviest days

of flow. She reports that menstrual cramps prior to and during flow are increasingly bothersome and do not respond adequately to ibuprofen. She intermittently uses condoms for contraception. She does not wish to be pregnant currently; however, she recently entered into a new relationship and may wish to conceive in the future.

On bimanual examination, the uterus appears bulky. Her hemoglobin is 10.9 g/dL with low mean corpuscular volume and a serum ferritin level indicating iron depletion. Pelvic ultrasonography suggests uterine adenomyosis; no fibroids are imaged (FIGURE 1).



Dr. Kaunitz is University of Florida Term Professor and Associate Chairman, Department of Obstetrics and Gynecology, University of Florida College of Medicine-Jacksonville; Medical Director and Director of Menopause and Gynecologic Ultrasound Services, UF Women’s Health Specialists at Emerson, Jacksonville. He serves on the OBG MANAGEMENT Board of Editors.



Dr. McCullough is Assistant Professor, Department of Obstetrics and Gynecology, University of Florida College of Medicine-Jacksonville.



Dr. Burnett is Assistant Professor, Department of Obstetrics and Gynecology; Chief, Maternal Fetal Medicine; Program Director, Ultrasound and Prenatal Diagnosis; and Clerkship Director, University of Florida College of Medicine-Jacksonville.

Dr. Kaunitz reports receiving grant or research support from Allergan, Bayer, and Medicines360 and being a consultant to Pfizer. Drs. McCullough and Burnett report no financial relationships relevant to this article.

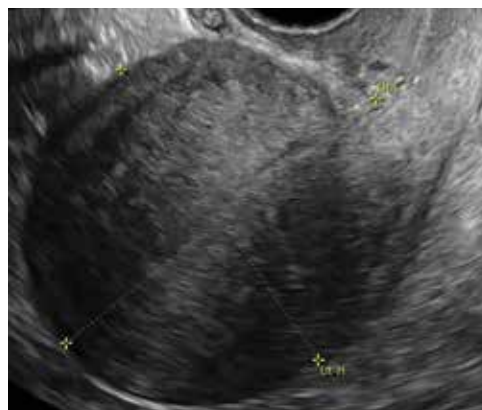

FIGURE 1 Sagittal view of anterior uterus with hyperechoic changes extending anteriorly and posteriorly from the endometrial echo, suggesting adenomyosis. Image courtesy of Andrew Kaunitz.

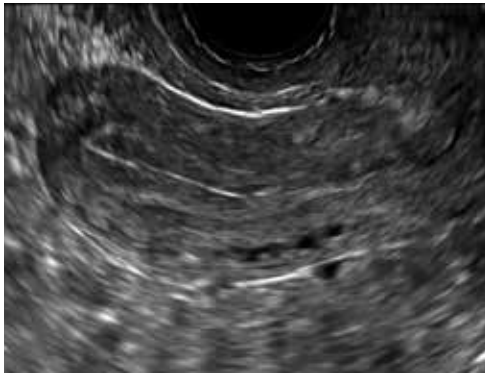


FIGURE 2 Sagittal view of anterior uterus with multiplanar (“trilaminar”) endometrium, consistent with proliferative changes. *Image courtesy of Andrew Kaunitz.*

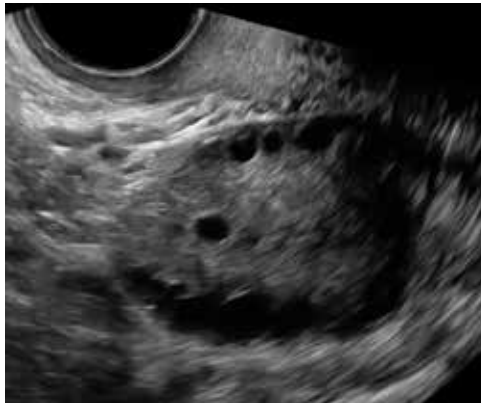


FIGURE 3 Ovary with numerous crowded-appearing cortical follicles, consistent with PCOS. *Image courtesy of Andrew Kaunitz.*

You advise the patient to take ferrous sulfate 325 mg every other day. After discussion with the patient regarding different treatment options, she chooses to proceed with placement of a 52-mg levonorgestrel (LNG) intrauterine device (IUD; Mirena or Liletta).

CASE 2 Older adolescent presents with irregular bleeding

A 19-year-old patient reports approximately 6 bleeding episodes each year. She reports the duration of her bleeding as variable, and sometimes the bleeding is heavy with small clots passed. She has been previously diagnosed with polycystic ovary syndrome (PCOS). Combination estrogen-progestin oral contraceptives have been prescribed several times in the past, but she always has discontinued them due to nausea. The patient is in a same-sex relationship and does not anticipate being sexually active with a male. She reports having to shave her mustache and chin twice weekly for the past 1 to 2 years.

On physical examination, the patient is obese (body mass index [BMI], 32 kg/m²), facial acne and hirsutism are present, and hair extends from the mons toward the umbilicus. Bimanual examination reveals a normal size, mobile, nontender uterus without obvious adnexal pathology. Pelvic ultrasonography demonstrates a normal-appearing uterus with multiplanar endometrium (consistent with proliferative changes) (**FIGURE 2**). Ovarian imaging demonstrates ≥ 12 follicles per image (**FIGURE 3**).

After reviewing various treatment options, you prescribe oral medroxyprogesterone acetate 20 mg (two 10-mg tablets) daily in a continuous fashion. You counsel her that she should not be surprised or concerned if frequent or even continuous bleeding occurs initially, and that she should continue this medication despite the occurrence of such.

About one-third of all women experience abnormal uterine bleeding (AUB) sometime during their lifetime and AUB can impair quality of life.¹ Surgical management, including hysterectomy and endometrial ablation, plays an important role in the management of AUB in patients who do not desire future pregnancies. However, many cases of AUB occur in women who may not have completed childbearing or in women who prefer to avoid surgery.² AUB can be managed effectively medically in most cases.¹ Accordingly, in this review, we focus on nonsurgical management of AUB.

Because previously used terms, including menorrhagia and meno-metrorrhagia were inconsistently defined and confusing, the International Federation of Gynecology and Obstetrics introduced updated terminology in 2011 to better describe and characterize AUB in nonpregnant women. Heavy menstrual bleeding (HMB) refers to ovulatory (cyclic) bleeding that is more than 8 days' duration, or sufficiently heavy to impair a woman's quality of life. HMB is a

FAST TRACK

Although surgical options are important for managing AUB, heavy bleeding occurs in many women who have not completed childbearing or in those who prefer medical management

pattern of AUB distinct from the irregular bleeding pattern typically caused by ovulatory dysfunction (AUB-O).¹

Clinical evaluation

Obtain menstrual history. In addition to a medical, surgical, and gynecologic history, a thorough menstrual history should be obtained to further characterize the patient's bleeding pattern. In contrast to the cyclical or ovulatory bleeding seen with HMB, bleeding associated with inconsistent ovulation (AUB-O) is unpredictable or irregular, and is commonly associated with PCOS. AUB-O is also encountered in recently menarchal girls (secondary to immaturity of the hypothalamic-pituitary-gonadal axis) and in those who are perimenopausal. In addition, medications that can induce hyperprolactinemia (such as certain antipsychotics) can cause AUB-O.

Evaluate for all sources of bleeding. Be sure to evaluate for extrauterine causes of bleeding, including the cervix, vagina, vulva, or the urinary or gastrointestinal tracts for bleeding. Intermenstrual bleeding occurring between normal regular menses may be caused by an endometrial polyp, submucosal fibroid, endometritis, or an IUD. The patient report of postcoital bleeding suggests that cervical disease (cervicitis, polyp, or malignancy) may be present. Uterine leiomyoma or adenomyosis represent common causes of HMB. However, HMB also may be caused by a copper IUD, coagulation disorders (including von Willebrand disease), or use of anticoagulant medications. Hormonal contraceptives also can cause irregular bleeding.

Perform a pelvic examination and measure vital signs. The presence of fever suggests the possible presence of pelvic inflammatory disease (PID), while orthostatic hypotension raises the possibility of hypovolemia. When vaginal speculum examination is performed, a cervical cause of abnormal bleeding may be noted. The presence of fresh or old blood or finding clots in the vaginal vault or at the cervical os are all consistent with AUB. A bimanual exami-

nation that reveals an enlarged or lobular uterus suggests leiomyoma or adenomyosis. Cervical or adnexal tenderness is often noted in women with PID, which itself may be associated with endometritis. The presence of hyperandrogenic signs on physical examination (eg, acne, hirsutism, or clitoromegaly) suggests PCOS. The finding of galactorrhea suggests that hyperprolactinemia may be present.

Laboratory assessment

Test for pregnancy, cervical disease, and sexually transmitted infection when appropriate. Pregnancy testing is appropriate for women with AUB aged 55 years or younger. If patients with AUB are not up to date with normal cervical cancer screening results, cervical cytology and/or human papillomavirus testing should be performed. Testing for *Chlamydia trachomatis*, *Neisseria gonorrhoeae*, and *Trichomonas vaginalis* should be performed in patients:

- younger than 25 years
- when the history indicates new or multiple sexual partners, or
- when vaginal discharge, cervicitis, cervical motion, or adnexal tenderness is present.

Obtain a complete blood count and serum ferritin levels. In women presenting with HMB, iron depletion and iron deficiency anemia are common. The finding of leukocytosis raises the possibility of PID or postpartum endometritis. In women with presumptive AUB-O, checking the levels of thyroid-stimulating hormone, free T₄, and prolactin should be performed.

Screen for a hemostasis disorder. Women with excessive menstrual bleeding should be clinically screened for an underlying disorder of hemostasis (TABLE 1).³ When a hemostasis disorder is suspected, initial laboratory evaluation includes a partial thromboplastin time, prothrombin time, activated partial thromboplastin time, and fibrinogen. Women who have a positive clinical screen for a possible bleeding disorder or abnormal initial laboratory test results for disorders of hemostasis should undergo further labora-

FAST TRACK

For women with HMB, screen for iron deficiency by obtaining serum ferritin levels

tory evaluation, including von Willebrand factor antigen, ristocetin cofactor assay, and factor VIII. Consultation with a hematologist should be considered in these cases.

Perform endometrial biopsy when indicated

After excluding pregnancy, endometrial biopsy (through pipelle biopsy or brush sampling; **FIGURE 4**) should be performed in women with AUB who are at increased risk for endometrial neoplasia. The prevalence of endometrial neoplasia is substantially higher among women ≥ 45 years of age⁴ and among patients with AUB who are also obese (BMI, ≥ 30 kg/m²).⁵ In addition, AUB patients with unopposed estrogen exposure (presumed anovulation/PCOS), as well as those with persistent AUB or failed medical management, should undergo endometrial biopsy.⁶

Utilize transvaginal ultrasonography

Transvaginal ultrasonography is often useful in the evaluation of patients with AUB, as it may identify uterine fibroids or adenomyosis, suggest intracavitary pathology (such as an endometrial polyp or submucosal fibroid), or raise the possibility of PCOS. In virginal patients or those in whom vaginal ultrasound is not appropriate, abdominal pelvic ultrasonography represents appropriate imaging. If unenhanced ultrasound suggests endometrial polyps or fibroids within the endometrial cavity, an office-based saline infusion sonogram (sonohysterogram) (**FIGURE 5**) or

TABLE 1 Clinical screening for an underlying disorder of hemostasis in the patient with excessive menstrual bleeding³

Initial screening should be structured by the medical history. A positive screening result^a comprises the following circumstances:

- Heavy menstrual bleeding since menarche
- One of the following conditions:
 - Postpartum hemorrhage
 - Surgery-related bleeding
 - Bleeding associated with dental work
- Two or more of the following conditions:
 - Bruising, 1 to 2 times per month
 - Epistaxis, 1 to 2 times per month
 - Frequent gum bleeding
 - Family history of bleeding symptoms

^aPatients with a positive screening result should be considered for further evaluation, including consultation with a hematologist and testing for von Willebrand factor and ristocetin cofactor.

hysteroscopy should be performed. Targeted endometrial sampling and biopsy of intracavitary pathology can be performed at the time of hysteroscopy.

Treatment

When HMB impairs quality of life, is bothersome to the patient, or results in anemia, treatment is appropriate. Although bleeding episodes in women with AUB-O may be infrequent (as with Case 2), treatment prevents heavy or prolonged bleeding episodes as well as endometrial neoplasia that may otherwise occur in anovulatory women.

CONTINUED ON PAGE 34

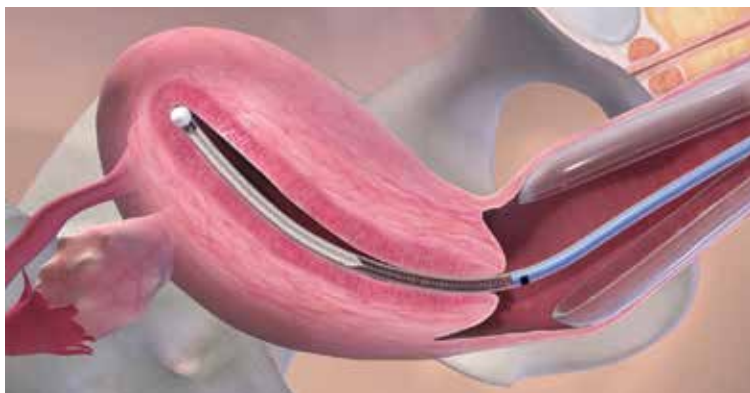

FIGURE 4 Endometrial brush sampling. Copyright Cook Medical. Used with permission.

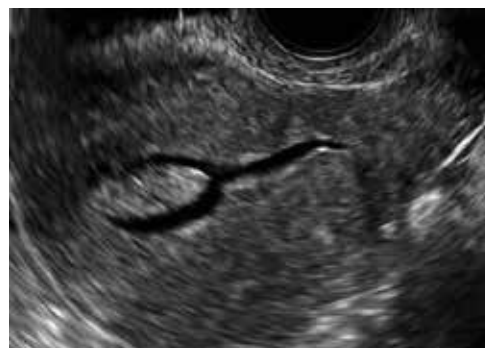

FIGURE 5 Sagittal view of uterus with endometrial cavity distended by saline (sonohysterogram or saline-infusion sonogram), demonstrating fundal endometrial polyp. Image courtesy of Andrew Kaunitz.

TABLE 2 Medical treatment options for management of abnormal uterine bleeding in reproductive-age women⁷⁻¹⁴

- Combination estrogen-progestin contraceptives (oral, vaginal ring, transdermal)
- If use of combination contraceptives are not appropriate due to cardiovascular risk factors, consider continuous (off-label) oral menopausal estrogen-progestin formulations, or oral high-dose progestin therapy:
 - ethinyl estradiol 5 µg + norethindrone acetate 1 mg (Jinteli 1/5 and other generics)
 - estradiol 1 mg + norethindrone acetate 0.5 mg (Mimvey and other generics)
- High-dose oral progestin therapy (in contrast to package labeling, continuous therapy preferred to cyclical therapy):
 - norethindrone acetate 5-mg tablets once daily
 - medroxyprogesterone acetate 10-mg tablets 1–3 tablets daily
- Levonorgestrel 52 mg IUD (Mirena or Liletta)
- Off-label use of nonsteroidal anti-inflammatory drugs daily for 5 days beginning at the onset of menstrual flow
- Tranexamic acid two 650-mg tablets 3 times daily for up to 5 days during menstrual flow

Many women with AUB can be managed medically. However, treatment choices will vary with respect to the patient’s desire for future fertility, medical comorbidities, personal preferences, and financial barriers. While many women may prefer outpatient medical management (**TABLE 2**),⁷⁻¹⁴ others might desire surgical therapy, including endometrial ablation or hysterectomy.

Oral contraceptives

Combination estrogen-progestin oral contraceptives represent appropriate initial therapy for many women in the reproductive-age group with AUB, whether women have HMB or AUB-O. However, contraceptive doses of estrogen are not appropriate for some women with risk factors for cardiovascular disease, including those who smoke cigarettes and are age ≥35 years or those who have hypertension (**TABLE 3**).^{15,16}

Menopausal dosages of HT

If use of contraceptive doses of estrogen is not appropriate, continuous off-label use

of menopausal combination formulations (physiologic dosage) of hormonal therapy (HT; ie, lower doses of estrogen than contraceptives) may be effective in reducing or eliminating AUB. Options for menopausal combination formulations include generic ethinyl estradiol 5 µg/norethindrone acetate 1 mg or estradiol 1 mg/norethindrone acetate 0.5 mg.⁷ High-dose oral progestin therapy (norethindrone acetate 5 mg tablet once daily or medroxyprogesterone acetate 10 mg tablets 1–3 times daily) also can be used when combination contraceptives are contraindicated and may be more effective than lower-dose combination formulations.

Package labeling, as well as some guidelines, indicate that oral progestins used to treat AUB should be taken cyclically.⁸ However, continuous daily use is easier for many patients and may be more effective in reducing bleeding. Accordingly, we counsel patients with AUB who are using progestins and who do not wish to conceive to take these medications continuously. High-dose oral progestin therapy may cause bloating, dysphoria, and increased appetite/weight gain. Women initiating hormonal management (including the progestin IUDs detailed below) for AUB should be counseled that irregular or even continuous light bleeding/spotting is common initially, but this bleeding pattern typically decreases with continued use.

IUDs

The LNG 52 mg IUD (Mirena or Liletta) effectively treats HMB, reducing bleeding in a manner comparable to that of endometrial ablation.^{9,10} The Mirena IUD is approved for treatment of HMB in women desiring intrauterine contraception. In contrast to oral medications, use of progestin IUDs does not involve daily administration and may represent an attractive option for women with HMB who would like to avoid surgery or preserve fertility. With ongoing use, continuous oral or intrauterine hormonal management may result in amenorrhea in some women with AUB.

When the LNG 52 mg IUD is used to treat HMB, the menstrual suppression impact

may begin to attenuate after approximately 4 years of use; in this setting, replacing the IUD often restores effective menstrual suppression.¹¹ The LNG 52 mg IUD effectively suppresses menses in women with coagulation disorders; if menstrual suppression with the progestin IUD is not adequate in this setting, it may be appropriate to add an oral combination estrogen-progestin contraceptive or high-dose oral progestin.^{11,12}

NSAIDs and tranexamic acid

Off-label use of nonsteroidal anti-inflammatory drugs (naproxen 500–1,000 mg daily for 5 days beginning at the onset of menstrual flow or tranexamic acid two 650-mg tablets 3 times daily for up to 5 days during episodes of heavy flow) can suppress HMB and is useful for women who prefer to avoid or have contraindications to hormonal treatments.^{13,14} Unfortunately, these agents are not as effective as hormonal management in treating AUB.

Iron supplementation is often needed

Iron depletion commonly results from HMB, often resulting in iron deficiency anemia. When iron depletion (readily identified by checking a serum ferritin level) or iron deficiency anemia is identified, iron supplementation should be recommended. Every-other-day administration of iron supplements maximizes iron absorption while minimizing the adverse effects of unabsorbed iron, such as nausea. Sixty mg of elemental iron (ferrous sulfate 325 mg) administered every other day represents an inexpensive and effective treatment for iron deficiency/anemia.¹⁷ In patients who cannot tolerate oral iron supplementation or for those in whom oral therapy is not appropriate or effective, newer intravenous iron formulations are safe and effective.¹⁸

CASE 1 Follow-up

The patient noted marked improvement in her menstrual cramps following LNG-containing IUD placement. Although she also reported that she no longer experienced heavy menstrual flow or cramps, she was bothered by frequent, unpredictable light bleeding/spotting. You

TABLE 3 Cardiovascular-related contraindications^a to combination estrogen-progestin contraceptives^{b,15,16}

- History of deep vein thrombosis (DVT)/pulmonary embolism (PE) or acute DVT/PE
- Major surgery with prolonged immobilization
- Diabetes:
 - Nephropathy/retinopathy/neuropathy present
 - Other vascular disease or diabetes of >20 years duration
- Migraines with aura
- Hypertension
- Ischemic heart disease (current or history of)
- Multiple risk factors for cardiovascular disease (older age, smoking, diabetes, hyperlipidemia, and hypertension)
- Peripartum cardiomyopathy
- Smoking (age ≥35)
- History of stroke
- Systemic lupus erythematosus with positive (or unknown) antiphospholipid antibodies
- Thrombogenic mutations
- Valvular heart disease that is complicated:
 - Pulmonary hypertension, risk for atrial fibrillation, history of subacute bacterial endocarditis

^aAll listed contraindications are associated with Category 3 (Theoretic or proven risks of specific contraceptive use outweigh the advantages) or Category 4 (Unacceptable health risks [specific contraceptive method not to be used]) in the US Medical Eligibility Criteria for Contraceptive Use, 2016. This information is also available in a free app (CDC Contraception 2016).

^bOral contraceptives, ethinyl estradiol etonogestrel vaginal ring, ethinyl estradiol norelgestromin patch.

prescribed norethindrone acetate (NETA) 5-mg tablet orally once daily, to be used in addition to her IUD. After using the IUD with concomitant NETA for 2 months' duration, she noted that her bleeding/spotting almost completely resolved; however, she did report feeling irritable with use of the progestin tablets. She subsequently stopped the NETA tablets and, after 6 months of additional follow-up, reported only minimal spotting and no cramps.

At this later follow-up visit, you noted that her hemoglobin level increased to 12.6 g/dL, and the ferritin level no longer indicated iron depletion. After the IUD had been in place for 4 years, she reported that she was beginning to experience frequent light bleeding again. A follow-up vaginal sonogram noted a well-positioned IUD,

there was no suggestion of intracavitary pathology, and adenomyosis continued to be imaged. She underwent IUD removal and placement of a new LNG 52 mg IUD. This resulted in marked reduction in her bleeding.

CASE 2 Follow-up

Two weeks after beginning continuous oral progestin therapy, the patient called reporting

frequent irregular bleeding. She was reassured that this was not unexpected and encouraged to continue oral progestin therapy. During a 3-month follow-up visit, the patient noted little, if any, bleeding over the previous 2 months and was pleased with this result. She continued to note acne and hirsutism and asked about the possibility of adding spironolactone to her oral progestin regimen. ●

References

1. Munro MG, Critchley HOD, Fraser IS; FIGO Menstrual Disorders Committee. The two FIGO systems for normal and abnormal uterine bleeding symptoms and classification of causes of abnormal uterine bleeding in the reproductive years: 2018 revisions. *Int J Gynecol Obstet.* 2018;143:393-408.
2. Kaunitz AM. Abnormal uterine bleeding in reproductive-age women. *JAMA.* 2019;321:2126-2127.
3. American College of Obstetricians and Gynecologists. ACOG committee opinion no. 557: management of acute abnormal uterine bleeding in nonpregnant reproductive-aged women. *Obstet Gynecol.* 2013;121:891-896.
4. National Cancer Institute Surveillance, Epidemiology, and End Results Program. Cancer Stat Facts: Uterine Cancer. <http://seer.cancer.gov/statfacts/html/corp.html>. Accessed October 10, 2019.
5. Wise MR, Gill P, Lensen S, et al. Body mass index trumps age in decision for endometrial biopsy: cohort study of symptomatic premenopausal women. *Am J Obstet Gynecol.* 2016;215:598.e1-598.e8.
6. American College of Obstetricians and Gynecologists Committee on Practice Bulletins—Gynecology. Practice bulletin no. 128: diagnosis of abnormal uterine bleeding in reproductive-aged women. *Obstet Gynecol.* 2012;120:197-206.
7. The North American Menopause Society. *Menopause Practice—A Clinician's Guide.* 5th ed. NAMS: Mayfield Heights, OH; 2014.
8. National Institute for Health and Care Excellence. Heavy menstrual bleeding: assessment and management. <https://www.nice.org.uk/guidance/ng88>. Accessed October 10, 2019.
9. Kaunitz AM, Bissonnette F, Monteiro I, et al. Levonorgestrel-releasing intrauterine system or medroxyprogesterone for heavy menstrual bleeding: a randomized controlled trial. *Obstet Gynecol.* 2010;116:625-632.
10. Kaunitz AM, Meredith S, Inki P, et al. Levonorgestrel-releasing intrauterine system and endometrial ablation in heavy menstrual bleeding: a systematic review and meta-analysis. *Obstet Gynecol.* 2009;113:1104-1116.
11. Kaunitz AM, Inki P. The levonorgestrel-releasing intrauterine system in heavy menstrual bleeding: a benefit-risk review. *Drugs.* 2012;72:193-215.
12. James AH, Kouides PA, Abdul-Kadir R, et al. Von Willebrand disease and other bleeding disorders in women: consensus on diagnosis and management from an international expert panel. *Am J Obstet Gynecol.* 2009;201:12.e1-8.
13. Ylikorkala O, Pekonen F. Naproxen reduces idiopathic but not fibromyoma-induced menorrhagia. *Obstet Gynecol.* 1986;68:10-12.
14. Lukes AS, Moore KA, Muse KN, et al. Tranexamic acid treatment for heavy menstrual bleeding: a randomized controlled trial. *Obstet Gynecol.* 2010;116:865-875.
15. Curtis KM, Tepper NK, Jatlaoui TC, et al. U.S. Medical Eligibility Criteria for Contraceptive Use, 2016. *MMWR Recomm Rep.* 2016;65:1-103.
16. ACOG Practice Bulletin no. 206: use of hormonal contraception in women with coexisting medical conditions. *Obstet Gynecol.* 2019;133:e128-e150.
17. Stoffel NU, Cercamondi CI, Brittenham G, et al. Iron absorption from oral iron supplements given on consecutive versus alternate days and as single morning doses versus twice-daily split dosing in iron-depleted women: two open-label, randomised controlled trials. *Lancet Haematol.* 2017;4:e524-e533.
18. Auerbach M, Adamson JW. How we diagnose and treat iron deficiency anemia. *Am J Hematol.* 2016;91:31-38.