

Retained placenta after vaginal birth: How long should you wait to manually remove the placenta?

For a woman with a neuraxial anesthetic, 20 minutes post-birth of the newborn may be the best time to diagnose retained placenta and consider manual removal



Robert L. Barbieri, MD

Editor in Chief, OBG MANAGEMENT
 Chair, Obstetrics and Gynecology
 Brigham and Women's Hospital
 Boston, Massachusetts
 Kate Macy Ladd Professor of Obstetrics,
 Gynecology and Reproductive Biology
 Harvard Medical School

You have just safely delivered the baby who is quietly resting on her mother's chest. You begin active management of the third stage of labor, administering oxytocin, performing uterine massage and applying controlled tension on the umbilical cord. There is no evidence of excess postpartum bleeding.

How long will you wait to deliver the placenta?

Active management of the third stage of labor

Most authorities recommend active management of the third stage of labor because active management reduces the risk of maternal hemorrhage >1,000 mL (relative risk [RR], 0.34), postpartum hemoglobin levels < 9 g/dL (RR, 0.50), and maternal blood transfusion (RR, 0.35) compared with expectant management.¹

The most important component of active management of the third stage of labor is the administration of

a uterotonic after delivery of the newborn. In the United States, oxytocin is the uterotonic most often utilized for the active management of the third stage of labor. Authors of a recent randomized clinical trial reported that intravenous oxytocin is superior to intramuscular oxytocin for reducing postpartum blood loss (385 vs 445 mL), the frequency of blood loss greater than 1,000 mL (4.6% vs 8.1%), and the rate of maternal blood transfusion (1.5% vs 4.4%).²

In addition to administering oxytocin, the active management of the third stage often involves maneuvers to accelerate placental delivery, including the Crede and Brandt-Andrews maneuvers and controlled tension on the umbilical cord. The Crede maneuver, described in 1853, involves placing a hand on the abdominal wall near the uterine fundus and squeezing the uterine fundus between the thumb and fingers.^{3,4}

The Brandt-Andrews maneuver, described in 1933, involves placing a clamp on the umbilical cord close

to the vulva.⁵ The clamp is used to apply judicious tension on the cord with one hand, while the other hand is placed on the mother's abdomen with the palm and fingers overlying the junction between the uterine corpus and the lower segment. With judicious tension on the cord, the abdominal hand pushes the uterus upward toward the umbilicus. Placental separation is indicated when lengthening of the umbilical cord occurs. The Brandt-Andrews maneuver may be associated with fewer cases of uterine inversion than the Crede maneuver.⁵⁻⁷

Of note, umbilical cord traction has not been demonstrated to reduce the need for blood transfusion or the incidence of postpartum hemorrhage (PPH) >1,000 mL, and it is commonly utilized by obstetricians and midwives.^{8,9} Hence, in the third stage, the delivering clinician should routinely administer a uterotonic, but use of judicious tension on the cord can be deferred if the woman prefers a non-interventional approach to delivery.

CONTINUED ON PAGE 10

Beware of placenta accreta spectrum disorder, and be ready to recognize and treat uterine inversion

The retained placenta may prevent the uterine muscle from effectively contracting around penetrating veins and arteries, thereby increasing the risk of postpartum hemorrhage. The placenta that has separated from the uterine wall but is trapped inside the uterine cavity can be removed easily with manual extraction. If the placenta is physiologically adherent to the uterine wall, a gentle sweeping motion with an intrauterine hand usually can separate the placenta from the uterus in preparation for manual extraction. However, if a placenta accreta spectrum disorder is contributing to a retained placenta, it may be difficult to separate the densely adherent portion of the uterus from the uterine wall. In the presence of placenta accreta spectrum disorder, vigorous attempts to remove the placenta may precipitate massive bleeding. In

some cases, the accoucheur/midwife may recognize the presence of a focal accreta and cease attempts to remove the placenta in order to organize the personnel and equipment needed to effectively treat a potential case of placenta accreta. In one study, when a placenta accreta was recognized or suspected, immediately ceasing attempts at manually removing the placenta resulted in better case outcomes than continued attempts to remove the placenta.¹

Uterine inversion may occur during an attempt to manually remove the placenta. There is universal agreement that once a uterine inversion is recognized it is critically important to immediately restore normal uterine anatomy to avoid massive hemorrhage and maternal shock. The initial management of uterine inversion includes:

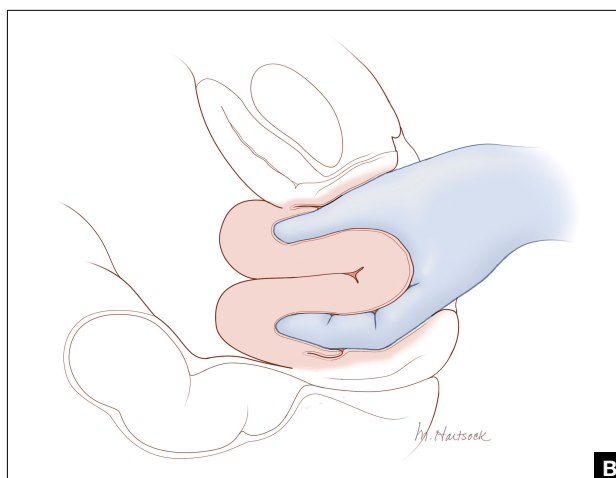
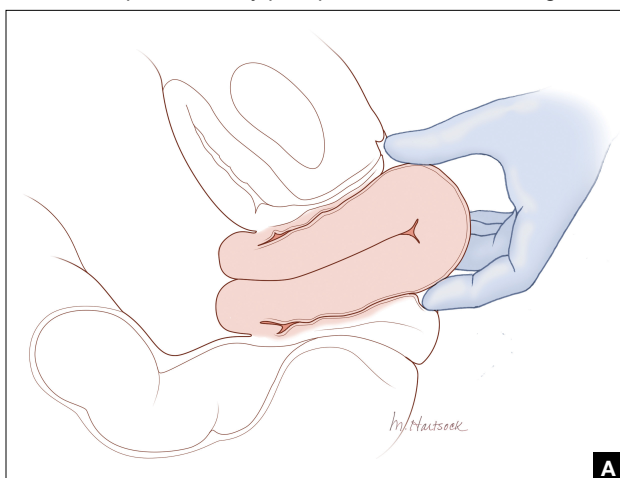


FIGURE 1 Use of the finger tips to guide the uterine wall back to normal anatomy.

Following a vaginal birth, when should the diagnosis of retained placenta be made?

The historic definition of retained placenta is nonexpulsion of the placenta 30 minutes after delivery of the newborn. However, many observational studies report that, when active management of the third stage is utilized, 90%, 95%, and 99% of placentas deliver by 9 minutes, 13 minutes, and 28 minutes, respectively.¹⁰ In addition, many observational studies report that the incidence of PPH increases significantly with longer intervals between

birth of the newborn and delivery of the placenta. In one study the rate of blood loss >500 mL was 8.5% when the placenta delivered between 5 and 9 minutes and 35.1% when the placenta delivered ≥30 minutes following birth of the baby.¹⁰ In another observational study, compared with women delivering the placenta < 10 minutes after birth, women delivering the placenta ≥30 minutes after birth had a 3-fold increased risk of PPH.¹¹ Similar findings have been reported in other studies.¹²⁻¹⁴

Based on the association between a delay in delivery of the placenta and an increased risk of PPH, some

authorities recommend that, in term pregnancy, the diagnosis of retained placenta should be made at 20 minutes following birth and consideration should be given to removing the placenta at this time. For women with effective neuraxial anesthesia, manual removal of the placenta 20 minutes following birth may be the best decision for balancing the benefit of preventing PPH with the risk of unnecessary intervention. For women with no anesthesia, delaying manual removal of the placenta to 30 minutes or more following birth may permit more time for the placenta to deliver prior to performing an intervention

- stopping oxytocin infusion
- initiating high volume fluid resuscitation
- considering a dose of a uterine relaxant, such as nitroglycerin or terbutaline
- preparing for blood product replacement.

In my experience, when uterine inversion is immediately recognized and successfully treated, blood product replacement is not usually necessary. However, if uterine inversion has not been immediately recognized or treated, massive hemorrhage and shock may occur.

Two approaches to the vaginal restoration of uterine anatomy involve using the tips of the fingers and palm of the hand to guide the wall of the uterus back to its normal position (**FIGURE 1**) or to forcefully use a fist to force the uterine wall back to its normal position (**FIGURE 2**). If these maneuvers are unsuccessful, a laparotomy may be necessary.

At laparotomy, the Huntington or Haultain procedures may help restore normal uterine anatomy. The Huntington

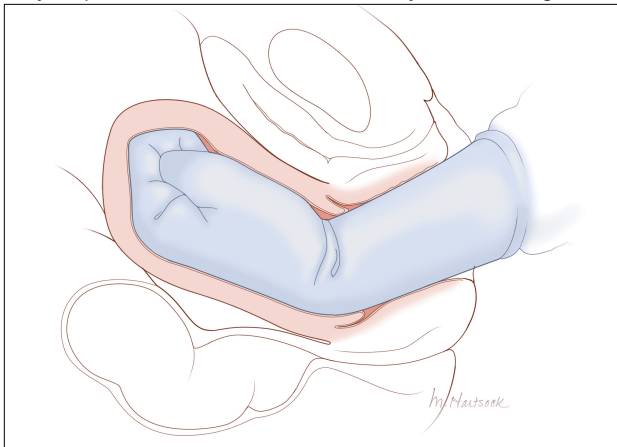


FIGURE 2 Use of the fist to force the uterine wall back to its normal position.

procedure involves using clamps to apply symmetrical tension to the left and right round ligaments and/or uterine serosa to sequentially tease the uterus back to normal anatomy.^{2,3} The Haultain procedure involves a vertical incision on the posterior wall of the uterus to release the uterine constriction ring that is preventing the return of the uterine fundus to its normal position (**FIGURE 3**).^{4,5}

References

1. Kayem G, Anselem O, Schmitz T, et al. Conservative versus radical management in cases of placenta accreta: a historical study. *J Gynecol Obstet Biol Reprod (Paris)*. 2007;36:680-687.
2. Huntington JL. Acute inversion of the uterus. *Boston Med Surg J*. 1921;184:376-378.
3. Huntington JL, Irving FC, Kellogg FS. Abdominal reposition in acute inversion of the puerperal uterus. *Am J Obstet Gynecol*. 1928;15:34-40.
4. Haultain FW. Abdominal hysterotomy for chronic uterine inversion: a record of 3 cases. *Proc Roy Soc Med*. 1908;1:528-535.
5. Easterday CL, Reid DE. Inversion of the puerperal uterus managed by the Haultain technique; A case report. *Am J Obstet Gynecol*. 1959;78:1224-1226.

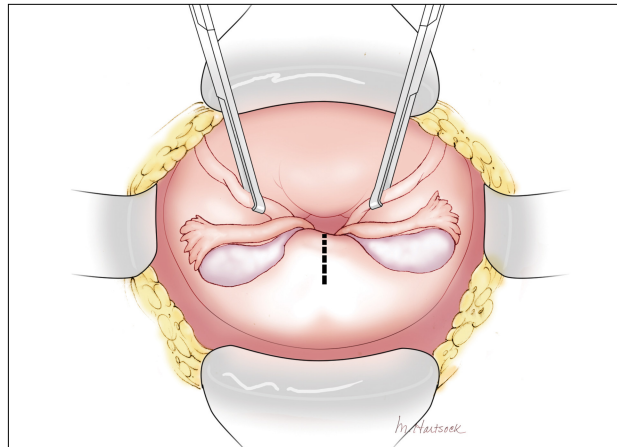


FIGURE 3 The Haultain procedure for correction of inversion of the uterus.

that might cause pain, but the delay increases the risk of PPH.

Manual extraction of the placenta

Prior to performing manual extraction of the placenta, a decision should be made regarding the approach to anesthesia and perioperative antibiotics. Manual extraction of the placenta is performed by placing one hand on the uterine fundus to stabilize the uterus and using the other hand to follow the umbilical cord into the uterine cavity. The intrauterine hand is used to separate the uter-

ine-placental interface with a gentle sweeping motion. The placental mass is grasped and gently teased through the cervix and vagina. Inspection of the placenta to ensure complete removal is necessary.

An alternative to manual extraction of the placenta is the use of Bierer forceps and ultrasound guidance to tease the placenta through the cervical os. This technique involves the following steps¹⁵:

1. use ultrasound to locate the placenta
2. place a ring forceps on the anterior lip of the cervix
3. introduce the Bierer forcep into the uterus

4. use the forceps to grasp the placenta and pull it toward the vagina
5. stop frequently to re-grasp placental tissue that is deeper in the uterine cavity
6. once the placenta is extracted, examine the placenta to ensure complete removal.

Of note when manual extraction is used to deliver a retained placenta, randomized clinical trials report no benefit for the following interventions:

- perioperative antibiotics¹⁶
- nitroglycerin to relax the uterus¹⁷
- ultrasound to detect retained placental tissue.¹⁸

CONTINUED ON PAGE 12

Best timing for manual extraction of the placenta

The timing for the diagnosis of retained placenta, and the risks and benefits of manual extraction would be best evaluated in a large, randomized clinical trial. However, based on

observational studies, in a term pregnancy, the diagnosis of retained placenta is best made using a 20-minute interval. In women with effective neuraxial anesthesia, consideration should be given to manual removal of the placenta at that time. ●



RBARBIERI@MDEDGE.COM

Dr. Barbieri reports no financial relationships relevant to this article.

References

- Begley CM, Gyte GM, Devane D, et al. Active versus expectant management for women in the third stage of labor. *Cochrane Database Syst Rev.* 2019;2:CD007412.
- Adnan N, Conlan-Trant R, McCormick C, et al. Intramuscular versus intravenous oxytocin to prevent postpartum haemorrhage at vaginal delivery: randomized controlled trial. *BMJ.* 2018;362:k3546.
- Gülmezoglu AM, Souza JP. The evolving management of the third stage of labour. *BJOG.* 2009;116(suppl 1):26-28.
- Ebert AD, David M. Meilensteine der Präventionsmedizin. Carl Siegmund Franz Credé (1819-1882), der Credesche Handgriff und die Credesche Augenprophylaxe. *Geburtshilfe Frauenheilkd.* 2016;76:675-678.
- Brandt ML. The mechanism and management of the third stage of labor. *Am J Obstet Gynecol.* 1933;25:662-667.
- Kimbell N. Brandt-Andrews technique of delivery of the placenta. *Br Med J.* 1958;1:203-204.
- De Lee JB, Greenhill JP. *Principles and Practice of Obstetrics.* 9th ed. Philadelphia, PA: Saunders; 1947:275.
- Du Y, Ye M, Zheng F. Active management of the third stage of labor with and without controlled cord traction: a systematic review and meta-analysis of randomized controlled trials. *Acta Obstet Gynecol Scand.* 2014;93:626-633.
- Hofmeyr GJ, Mshweshwe NT, Gülmezoglu AM. Controlled cord traction for the third stage of labor. *Cochrane Database Syst Rev.* 2015;1:CD008020.
- Frolova AI, Stout MJ, Tuuli MG, et al. Duration of the third stage of labor and risk of postpartum hemorrhage. *Obstet Gynecol.* 2016;127:951-956.
- Shinar S, Schwartz A, Maslovitz S, et al. How long is safe? Setting the cutoff for uncomplicated third stage length: a retrospective case-control study. *Birth.* 2016;43:36-41.
- Magann EF, Evans S, Chauhan SP, et al. The length of the third stage of labor and the risk of postpartum hemorrhage. *Obstet Gynecol.* 2005;105:290-293.
- Cummings K, Doherty DA, Magann EF, et al. Timing of manual placenta removal to prevent postpartum hemorrhage: is it time to act? *J Matern Fetal Neonatal Med.* 2016;29:3930-3933.
- Rabie NZ, Ounpraseuth S, Hughes D, et al. Association of the length of the third stage of labor and blood loss following vaginal delivery. *South Med J.* 2018;111:178-182.
- Rosenstein MG, Vargas JE, Drey EA. Ultrasound-guided instrumental removal of the retained placenta after vaginal delivery. *Am J Obstet Gynecol.* 2014;211:180.e1-e3.
- Chibueze EC, Parsons AJ, Ota E, et al. Prophylactic antibiotics for manual removal of retained placenta during vaginal birth: a systematic review of observational studies and meta-analysis. *BMC Pregnancy Childbirth.* 2015;15:313.
- Abdel-Aleem H, Abdel-Aleem MA, Shaaban OM. Nitroglycerin for management of retained placenta. *Cochrane Database Syst Rev.* 2015;(11):CD007708.
- Weissback T, Haikin-Herzberger E, Bacchi-Hugger K, et al. Immediate postpartum ultrasound evaluation for suspected retained placental tissue in patients undergoing manual removal of placenta. *Eur J Obstet Gynecol Reprod Biol.* 2015;192:37-40.