



ELSEVIER

Fractional Photothermolysis: A Review and Update

Ming H. Jih, MD, PhD, and Arash Kimyai-Asadi, MD

Fractional resurfacing is a new laser treatment modality that creates numerous microscopic thermal injury zones of controlled width, depth, and density that are surrounded by a reservoir of spared epidermal and dermal tissue, allowing for rapid repair of laser-induced thermal injury. This unique modality, if implemented with proper laser-delivery systems, enables high-energy treatments while minimizing risks. In this article, we review the various fractional laser devices, including the new fractional ablative devices, as well as the results of studies on the clinical efficacy of fractional photothermolysis. This technology offers patients significant clinical improvement in photodamage, melasma, and scarring with modest treatment-related downtime and minimal risk of complications.

Semin Cutan Med Surg 27:63-71 © 2008 Elsevier Inc. All rights reserved.

KEYWORDS fractional photothermolysis, non-ablative, ablative, review, scarring, photodamage

The theory of selective photothermolysis made laser treatments significantly safer by allowing for selective irradiation of specific target chromophores while minimizing damage to adjacent structures.¹ However, true containment of heat generated through laser absorption within target structures has been tempered by bulk heating effects of surrounding tissue, which have limited the treatment parameters for both ablative and nonablative lasers.

Ablative lasers remain the gold standard in skin resurfacing and provide the greatest clinical improvements with the least number of treatments. However, because of the complete vaporization of the epidermis and variable coagulative damage to the dermis, healing time is prolonged and treatments carry significant associated risks.²⁻⁵ Indeed, only very superficial ablation is possible because of the risk of permanent hypopigmentation and scarring with deeper thermal damage. In contrast, nonablative lasers minimize these risks by leaving the epidermis intact while delivering dermal laser irradiation with concomitant surface cooling measures. However, the absence of epidermal damage also appears to be associated with the absence of a true wound healing response and therefore minimal resurfacing efficacy. Multiple treatment sessions are required and there is variable and modest clinical improvement.⁶⁻⁹ Overall, both ablative and nonablative lasers create large macroscopic zones of thermal damage,

with the smallest area of thermal damage defined by the laser spot size.

Fractional resurfacing is a novel variation on the theory of selective photothermolysis wherein microscopic treatment zones (MTZs) of controlled width, depth, and densities are created (Fig. 1).^{10,11} These controlled zones of thermal heating and tissue damage are surrounded by spared areas of viable epidermis and dermis that allow for rapid repair of the microscopic treatment zones (Fig. 2). A detailed histologic study on the effects of fractional resurfacing was performed by Laubach and coworkers using a prototype diode laser.¹² Within 1 hour after laser irradiation, well-defined columns of both epidermal and dermal thermal damage are seen with an intact overlying stratum corneum. Within 24 hours, there is migration of viable cells from the periphery of the MTZs along with formation of microscopic epidermal necrotic debris (MENDs). MENDs comprise epidermal and dermal thermally damaged cells along with melanin and elastin.¹³ The MENDs undergo transepidermal extrusion between 3 and 7 days. Cellular markers of dermal wound healing and neocollagenesis such as heat shock protein 70, collagen III, proliferating cell nuclear antigen, and alpha-smooth muscle actin were expressed within the treatment areas.

Clinically, fractional resurfacing with fractional microscopic delivery of high energies to targeted depths in the dermis has made possible significant clinical improvements often approaching that of ablative lasers without any reports of permanent hypopigmentation or scarring.¹⁰⁻¹² More recent developments in the area of fractional photothermolysis involve the combination of ablative resurfacing with fractional delivery.

DermSurgery Associates, Houston, TX.

Address correspondence to Ming H. Jih, MD, PhD, DermSurgery Associates, 7515 Main, Suite 240, Houston, TX, 77030. E-mail: ming_jih@yahoo.com

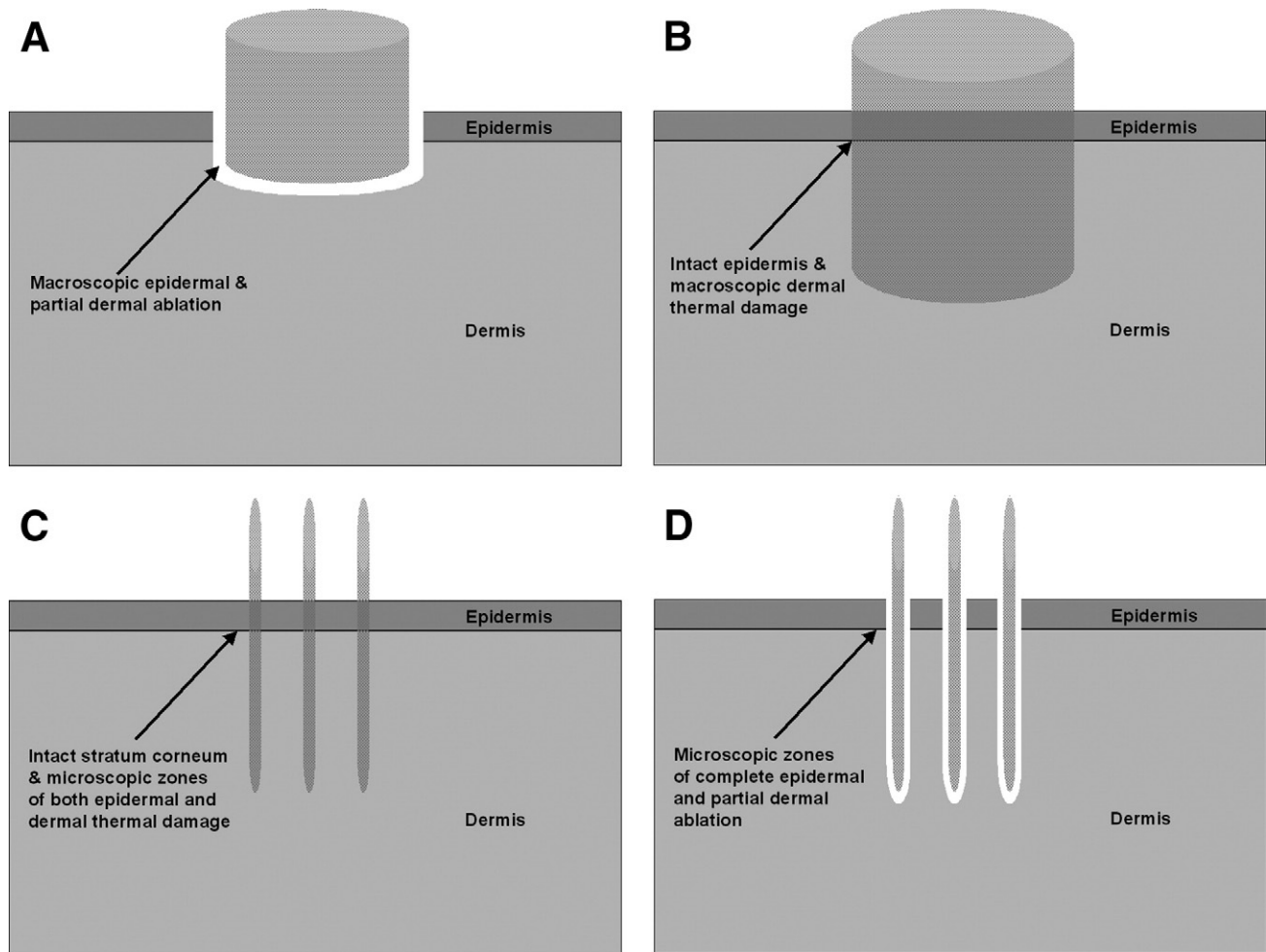


Figure 1 Comparative zones of tissue damage for various laser systems. A, Conventional ablative lasers form macroscopic regions of complete epidermal vaporization and variable superficial dermal damage with accompanying risk of delayed healing and scarring. B, Conventional nonablative lasers leave the epidermis completely intact and cause macroscopic regions of dermal thermal damage at varying depths, but the lack of epidermal damage is associated with modest clinical outcomes. C, Fractional resurfacing leaves an intact stratum corneum and creates microscopic zones of epidermal and deep dermal thermal damage. D, Ablative fractional resurfacing creates microscopic zones of complete epidermal ablation as well as microscopic zones of deep dermal ablation.

Laser Technology

Nonablative Fractional Photothermolysis

The first fractional device approved for clinical use was the Fraxel® SR750 laser (Reliant Technologies, Mountain View, CA), which consisted of an erbium-doped fiber laser operating at a wavelength of 1550 nm targeting water as a chromophore.¹¹ Disposable tips are available in 7- and 15-mm sizes. The laser is operated using a scanning mode wherein the handpiece is glided across the skin facilitated by application of an ointment to the skin before treatment. This avoids the occurrence of gaps in treatment areas and also avoids formation of Moire artifacts which occur in areas of inadvertent overlap when multiple passes are performed with a traditional stamping mode of treatment. MTZs are deposited in the skin in random patterns by means of a high-speed, beam-deflecting system. In addition, an Intelligent Optical Tracking® System (IOTS) monitors and adjusts for variable hand

speed and further aids in deposition of uniform MTZs. Previously, the IOTS detected handpiece motion with the aid of a water-soluble blue tint. However, a new roller tip has just become available that can be used without any tint and will allow for easier preparation and clean-up after treatment, as well as faster treatments.

Unlike other nonablative lasers, the Fraxel laser can be safely used without any cooling measures because of the microscopic treatment areas that minimize the risk of bulk heating. However, in practice, because of the moderate and sometimes-significant amount of pain and “heat” sensation associated with treatment, there is often need for cooling measures in addition to pretreatment topical anesthesia. The most commonly used cooling measures are forced cold air devices.^{14,15} Surface cooling has been shown to be associated with a decrease in the size and surface area of the MTZs, but it is unclear whether this has significant clinical effects.¹⁵ In reality, treatments often are performed at much higher flu-

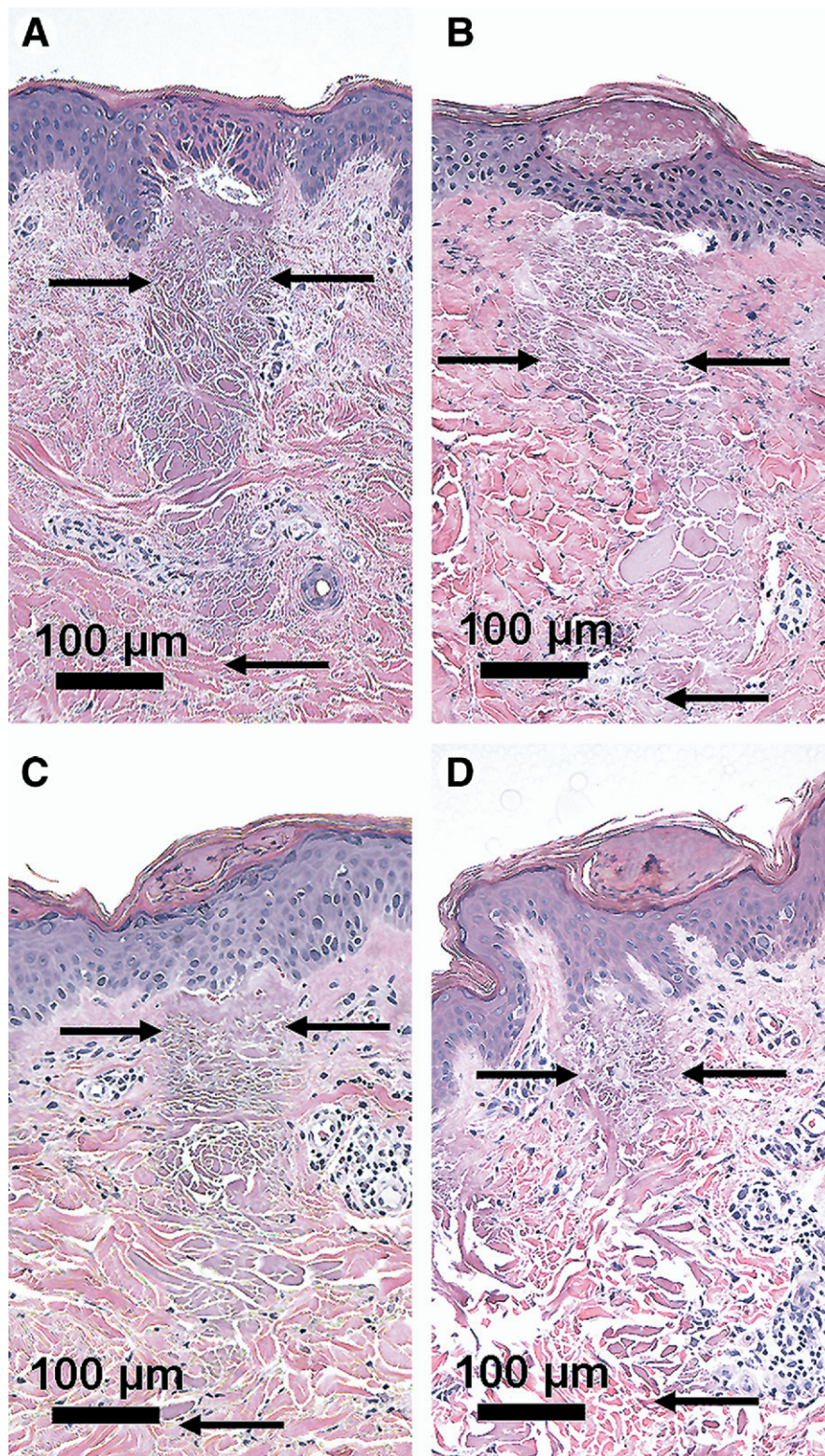


Figure 2 Healing progression following treatment by the Fraxel SR1500 laser at a per pulse energy setting of 15 mJ: A, At 0 days: there are well-defined columns of epidermal and dermal thermal denaturation with epidermal clefting but an intact stratum corneum. B, At 1 day after treatment: there is formation of microscopic epidermal necrotic debris (MENDs) containing thermally damaged epidermal and dermal cells. C, At 3 days after treatment: there is compaction of MENDs overlying an almost completely restored epidermis. D, At 7 days after treatment: the MENDs are intracorneal and beginning to exfoliate and the epidermal clefting has completely resolved. (Courtesy of Reliant Technologies, Mountainview, CA). (Color version of figure is available online.)

ences and densities with the aid of cooling devices due to improved patient tolerance.

The first-generation Fraxel (SR750) laser had 2 different MTZ density settings (125 MTZ/cm² and 250 MTZ/cm²) and the final treatment density, which correlates with the percentage of surface area treated, was determined by both the MTZ setting and number of laser passes. Microscopic treatment zones of 81 to 180 μm in width, and 300 μm to greater than 900 μm in depth are created in the skin depending on the pulse energies used (6 to 30 mJ). The second-generation Fraxel SR1500 laser (most recently renamed the *Fraxel restore*TM laser) has varying treatment setting levels (1 through 12 and advanced levels R1-R3) controlling treatment coverage areas ranging from 5% to 50% of the skin surface area. Initially, the SR1500 achieved pulse energies up to 40 mJ, but a recent software update has allowed pulse energies up to 70 mJ with depth of thermal injury up to 1400 μm .

An alternative infrared laser with fractional delivery is the StarLux[®] fractional handpiece, which can be used with the StarLux laser platform (Palomar Medical Technologies, Burlington, MA). This system delivers laser irradiation at 1550 nm wavelength with a fixed array of microbeams (mb) at up to 1.5 pulses per second. Laser treatment is delivered in a stamping mode so potential gaps in treatment areas and Moire artifacts from inadvertent overlap of treatment sites can occur. The 10-mm spot size delivers fluences up to 70 mJ/mb and creates a 100-mb/cm² array of columns of deep coagulation whereas the 15-mm spot size delivers fluences up to 15 mJ/mb and creates a 320 mb/cm² array of narrower columns for more superficial coagulation. Contact cooling is built into the handpiece, which protects the surface of the skin and decreases treatment-related pain. In addition, unlike the first-generation Fraxel laser, there is no need for topical tinting. The lens array in the StarLux fractional handpiece must be replaced after approximately 4000 pulses, which makes disposable costs comparable for the StarLux and Fraxel systems.

Ablative Fractional Lasers

Fractional delivery systems for both CO₂ and Er:YAG lasers also have been developed in an attempt to achieve the clinical results observed with traditional ablative lasers. Unlike the lasers, which were previously discussed, these devices cause true ablation of the epidermis in addition to variable depths of ablative damage to the dermis. The combination of epidermal and dermal ablation appears to lead to a more robust wound healing response and accompanying dermal fibrosis, which may explain the rapid and significant clinical effects that can be achieved with ablative versus nonablative devices. However, with fractional ablation the microscopic zones of ablated tissue are microscopic, normal skin is preserved in adjacent areas, and healing time as well as scarring risk is minimized compared with conventional ablative lasers. Histologic studies using a prototype 30 W ablative CO₂ laser with pulse energies between 5 and 40 mJ revealed discrete microthermal zones of epidermal and partial-thickness dermal coagulation that increase in both depth and width with increasing pulse energies (Fig. 3). Expression of heat shock

protein 72 was detected as early as 2 days after treatment and diminished significantly by 3 months, whereas increased expression of heat shock protein 47, a collagen-specific molecular chaperone that is required for maturation of various types of collagens, was first detected at 7 days and persisted at 3 months posttreatment indicating persistent collagen remodeling.¹⁶

Several different ablative prototype systems are being studied. One device, the *Fraxel re:pair*TM system (Reliant Technologies, Mountain View, CA), is similar to the nonablative Fraxel lasers in operation with a continuous scanning mode in deposition of arrays of thermal coagulation by means of a precision scanning wheel. Other lasers have fixed arrays of microscopic ablation and operate in an x-y scanning or stamping mode. Varying depths of penetration are possible with these devices, but unlike traditional CO₂ or Er:YAG lasers, deeper coagulation up to 1600 μm can be safely performed due to the fractional delivery of laser irradiation. In early reports, significant clinical improvements can be achieved after only one or two treatments with these devices, and there were no incidents of hypopigmentation or scarring.

Clinical Results

Treatment of Melasma

Some of the earliest clinical reports of fractional photothermolysis were on the treatment of facial melasma, which is oftentimes a combination of both epidermal and deeper dermal pigmentation that has been difficult to treat with both ablative and Q-switched lasers.^{17,18} The unique transepidermal elimination of necrotic epidermal and dermal debris and associated melanin seen in fractional photothermolysis appears to correspond directly with clinical improvement in dyschromia after laser treatment. Histologic studies have shown melanin deprivation from the epidermal basal cell layer one day after fractional photothermolysis.¹²

A case report by Tannous and Astner showed significant clinical improvements in resistant facial melasma after 2 Fraxel (SR750) laser treatments.¹⁹ In a study of 10 patients with skin types III to V with multitreatment resistant melasma, 4 to 6 sessions of the Fraxel laser were performed at fluences from 6 to 12 mJ and final treatment densities of 2000 to 3500 MTZ/cm².²⁰ Sixty percent of patients achieved 75% to 100% clearing. Only one patient with skin type V had hyperpigmentation after treatment.

There has been one report of the StarLux 1540-nm fractional handpiece for the treatment of melasma. In the study, 12 patients with melasma on the face and neck received 4 treatments with 4 passes with a minimum of 320 mb/cm² per pass. Because of contact cooling present in the handpiece, most patients did not require topical numbing. Patients had 40% to 50% improvement in melasma lasting up to 3 months.²¹

Treatment of Rhytides and Photodamage

Fractional resurfacing for the treatment of photodamage and rhytides has been safely and effectively performed not only

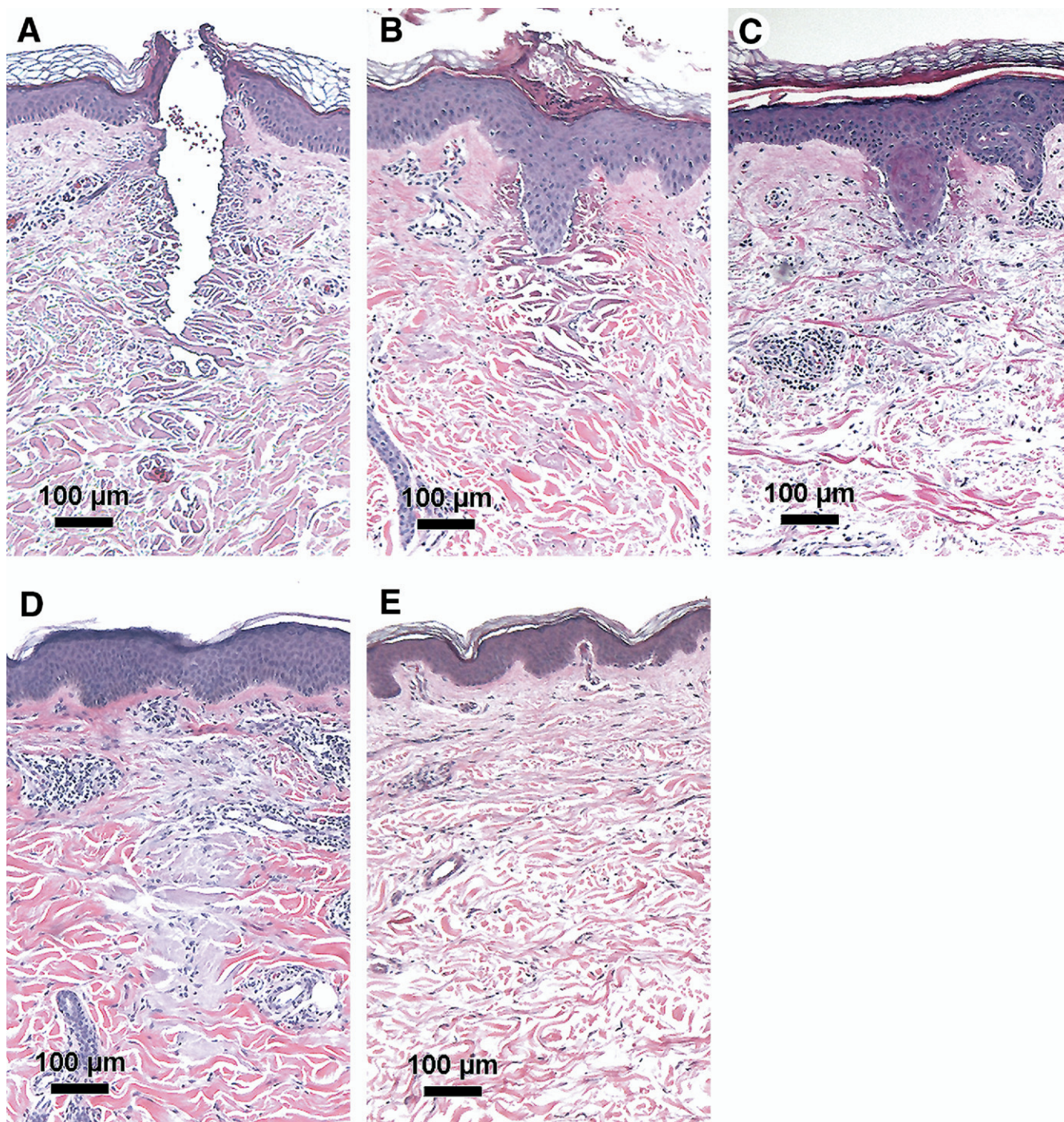


Figure 3 In vivo histology showing the wound healing process after 20 mJ of ablative Fraxel (re:pair) treatment. A, At 0 days: there is a discrete zone of epidermal and dermal ablation. B, At 2 days after treatment: there is invagination of the epidermis into the ablated dermis and necrotic debris beginning formation of MENDs is seen overlying the microscopic treatment zone C, At 1 week after treatment: the epidermis has completely re-epithelialized and the resulting MENDs have been exfoliated. D, 1 month after treatment: the epidermal invagination has regressed but a sustained coagulation zone is still visible in the dermis. E, At 3 months after treatment: newly formed compact collagen is seen in the treated area. (Courtesy of Reliant Technologies, Mountainview, CA). (Color version of figure is available online.)

on facial but also nonfacial areas. Fifty women with mild-to-moderate facial and nonfacial photodamage and rhytides received 3 treatments on the face and neck or chest area with the Fraxel (SR750) laser at a pulse energy of 8 mJ and density

setting of 250 MTZ/cm² for a final treatment density of 1500 to 2000 MTZ/cm². Clinical improvements were greatest at the 3-month follow-up, but at least 51% to 75% improvement in photodamage was maintained up to 9 months after

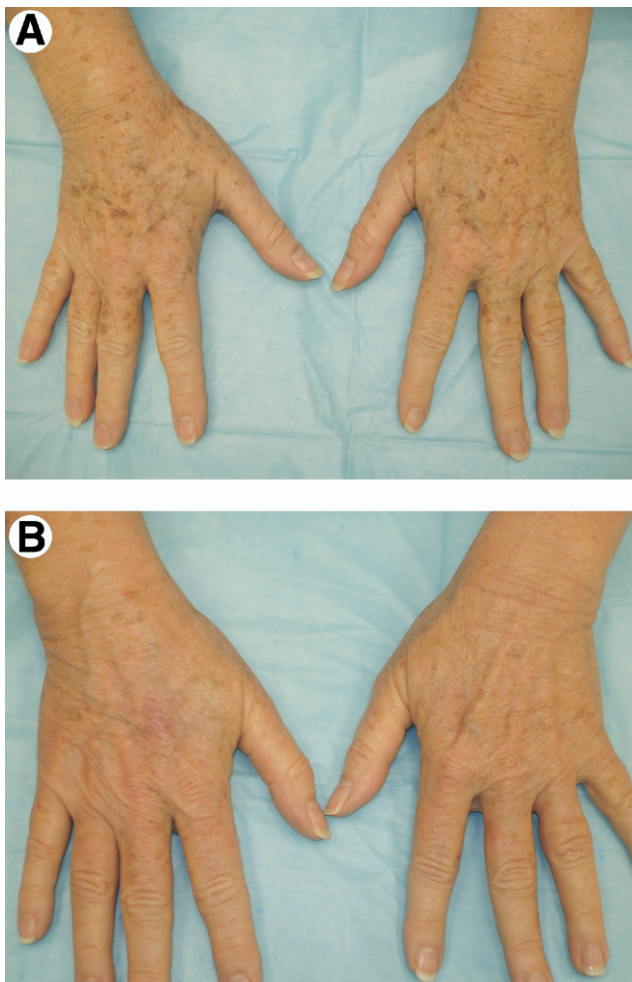


Figure 4 A, Hand photodamage at baseline. B, Hand photodamage after 4 treatments with the Fraxel SR1500 laser at settings of 14 to 16 mJ and treatment level 8 corresponding to 23% of skin surface area treated. (Color version of figure is available online.)

treatment in 73% and 55% of facial and nonfacial treated skin, respectively.²² All patients had transient erythema and edema lasting approximately 2 days with bronzing and desquamation seen in approximately one-third of patients, and 2 patients had acneiform eruptions. In a study of 10 patients with photodamage of the hands, 5 treatments were performed at pulse energies of 8 to 9 mJ and density setting of 250 MTZ/cm² for a final treatment density of 2500 MTZ/cm².²³ Both improvements in pigmentation (51-75%) and improvements in skin texture (25-50%) were achieved and maintained for 3 months (Fig. 4). A case report also showed improvements in the telangiectatic component of poikiloderma of Civatte.²⁴ Safe treatment of the eyelid areas can also be performed. In a recent study, 3 to 7 treatments were performed at 17 to 20 mJ and 125 MTZ/cm² for a final density of 500 to 750 MTZ/cm² on the eyelid area. In addition to reductions in rhytides, tightening of the eyelid skin was seen in the form of objective improvements in eyelid aperture in up to 68% of patients.²⁵ Overall, greater treatment densities appear to be associated with greater improvements in dyspigmentation whereas higher pulse energies affecting deeper dermal structures are

associated with greater improvements in rhytides and skin texture. In a study comparing treatment energy versus density, patient satisfaction was greater in those treated at higher energies but not higher densities, but both higher energy and density were associated with an increase in treatment-related pain and recovery time.²⁶

Treatment of Scarring

Fractional photothermolysis has been particularly well studied for the treatment of acne scars as well as surgical and traumatic scars (Fig. 5). Interestingly although CO₂ and Er:YAG ablative resurfacing produce unparalleled results for the treatment of facial rhytides, both have yielded lesser degrees of improvements for scarring. This may be due to the fact that the depth of macroscopic tissue ablation is limited. Although multiple treatments are still required, the significant depth of penetration achieved with the fractional lasers has led to improvements in scars similar to those achieved with the ablative lasers. The other significant advantage of the fractional lasers is that it can be safely used on all skin types without risk of pigmentary alteration.

Treatment at high energies with deep tissue coagulation appears to be associated with the greatest clinical improvements in scarring. In the largest case series reported to date, 181 patients with skin types I-III and 176 patients with skin types IV-VI and acne scarring received 1 to 5 treatments with the Fraxel (SR750) laser. Treatments were performed at a pulse energy of 25 mJ, 125 MTZ/cm² and 8 nonoverlapping passes, with additional treatment at 25 to 35 mJ and 125 MTZ/cm² for another 4 to 10 passes. Greater than 75% improvement was found in 12% of treated patients, and 50% to 75% improvement was observed in 73% of patients. Only one patient developed postinflammatory hyperpigmentation, and there was one case of localized scarring that resolved with intralesional corticosteroid injection.²⁷ Another study of 53 patients also showed similar clinical improvements of 51% to 75% in nearly 90% of treated patients up to 6 months after 2 to 5 treatments.²⁸ In a smaller study, 29 patients had moderate-to-marked improvements in acne scarring after 3 to 5 treatments with the newer Fraxel SR1500 (Fraxel *re:store*TM) laser at 40 mJ/MTZ and treatment levels of 7 to 10, and advanced level 1, corresponding to 23 to 35% of skin area treated.²⁹

Hypopigmented as well as erythematous scars have shown improvements lasting up to 6 months.^{30,31} Although the excimer laser also has been effective in repigmentation of hypopigmented scars, the results diminished over time and maintenance treatments were required at 1 to 4 months.³² The improvement in hypopigmentation with the Fraxel laser is particularly noteworthy because neither ablative nor nonablative lasers have previously been capable of restoring pigmentation. Long-term follow-up greater than 6 months will be necessary to determine the longevity of repigmentation from fractional resurfacing. In terms of mechanisms of action, epidermal injury is known to stimulate melanocyte proliferation and migration from the periphery of the wound.^{33,34} It is likely that formation of microscopic foci of

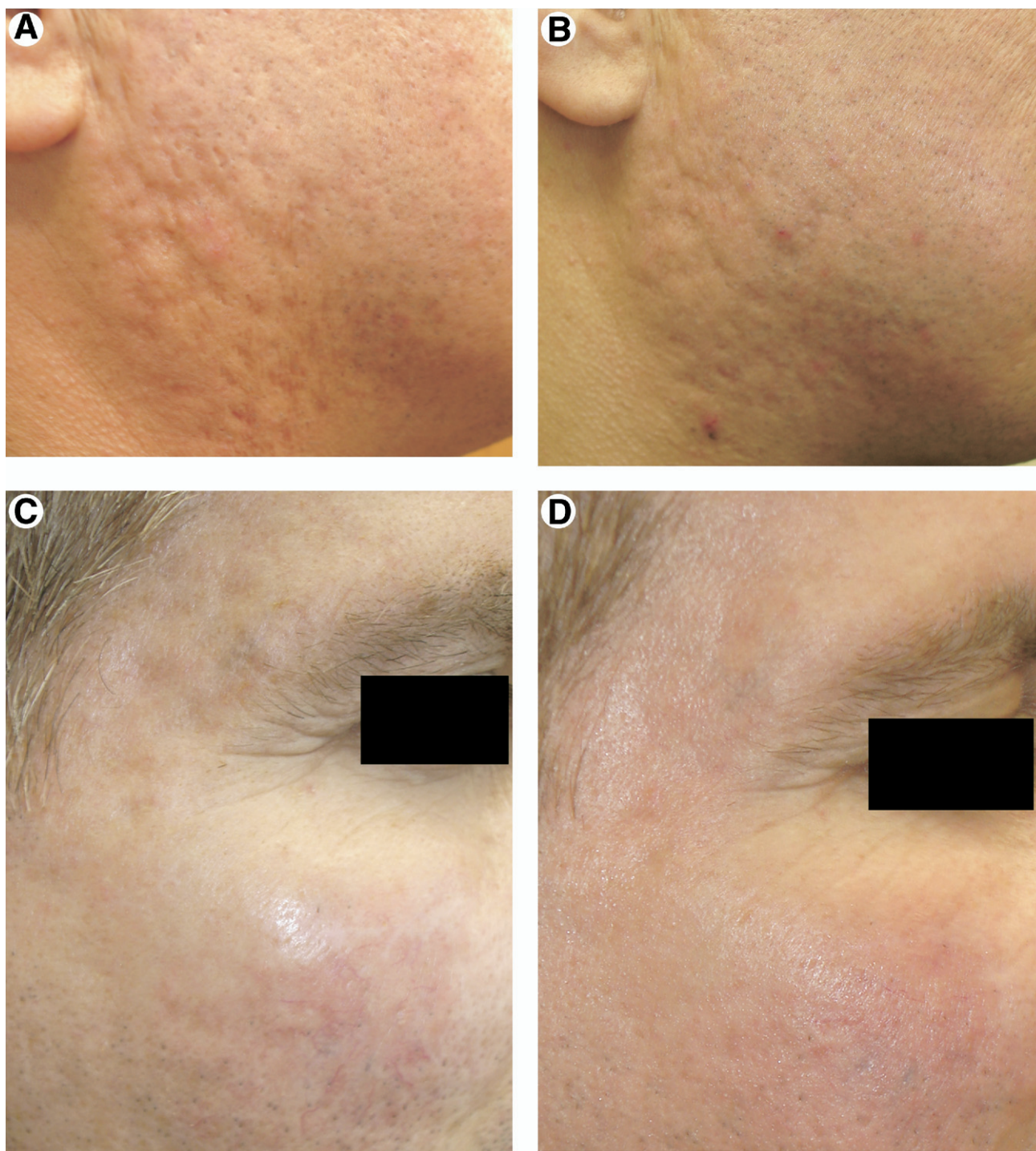


Figure 5 A, Acne scars at baseline. B, Acne scars after 4 treatments with the Fraxel SR1500 laser at settings of 18 to 20 mJ and treatment level 10 corresponding to approximately 29% of skin surface area treated. C: Acne scars at baseline. D: Acne scars following 6 treatments with the Fraxel SR1500 laser at settings of 18 to 20 mJ and treatment level 10 corresponding to approximately 29% of skin surface area treated. (Color version of figure is available online.)

epidermal injury from fractional resurfacing results in stimulation of both melanocyte proliferation and migration. Interestingly, recent studies have shown dormant melanocyte activity in areas of vitiligo that can be reactivated during wound healing.^{35,36} It is possible that hypopigmented scars also contain dormant melanocytes which are stimulated by a controlled wounding process.³⁷

Another reported use of fractional resurfacing is in the treatment of striae rubra and alba. Although striae rubra have been successfully treated with the pulsed dye laser, treatment of striae alba has been disappointing in the past.³⁸ Repigmentation of striae alba has been successfully reported with the excimer laser, however, repeat treatments are needed to sustain results.³² In a study of fractional resurfacing for the treat-

ment of striae rubra and alba, patients received 1 to 4 treatments at energies of 16 to 20 mJ and 125 MTZ/cm² per pass for final densities of 1000 to 1500 MTZ/cm². Both physician and patient evaluation graded improvements greater than 50%.³⁹ Additional uses of fractional resurfacing have been reported for the treatment of biopsy proven adult colloid milium as well as in the treatment of resistant tattoos.^{40,41}

Early Clinical Results With Ablative Fractional Lasers

Although not equaling the results seen after one conventional ablative resurfacing treatment, clinically notable improvements in facial rhytides, photodamage, acne scarring, and even in skin laxity have been reported with the new ablative fractional laser devices after a single treatment. Unlike conventional ablative lasers, treatments can be performed with only topical anesthesia with or without air-cooling. Ablative fractional treatment does result in serosanguinous discharge and there are 1 to 2 days of open wound care that is required. Preoperative antibiotics and antiviral prophylaxis is also recommended. However, since fractionated ablation allows for rapid reepithelialization usually within 2 days, healing time is significantly shorter, and there have not been any cases of hypopigmentation or permanent scarring.

Greater than 75% of patients had moderate-to-significant improvements in rhytides, pigmentation and laxity of the skin and neck after 1 to 2 treatments with a 10,600 nm fractional CO₂ laser (Reliant Technologies, Mountain View, CA) at settings of 10 to 20 mJ and 400 to 1600 MTZ/cm².⁴² In another study in which the authors use this same prototype laser, significant improvements in acne scarring were also seen after only 1 to 2 treatments.⁴³ Uniform treatment coverage, a function of all selectable treatment parameters and techniques, was shown to be essential to achieving successful treatment outcomes with ablative fractional resurfacing. As demonstrated in the 2 studies performed with this device, uniformity was best achieved by administering multiple passes at moderate density per pass settings as opposed to a single higher density treatment pass at the same total density of MTZ/cm². Multiple linear treatment passes are possible only through the use of a scanning handpiece, such as the delivery system introduced in this device. An *ex vivo* study of excised human skin treated with this fractional CO₂ laser showed consistent tissue shrinkage in the range of 37% indicating an effect on skin laxity which may be secondary to dermal fibrosis that occurs after ablative laser treatments.⁴⁴

Another fixed array ablative fractional CO₂ laser (UltraPulse Encore™ laser with Active-FX™, Lumenis, Santa Clara, CA) was used to treat 10 patients in a recent study.⁴⁵ One treatment was performed with an energy of 80 mJ and 30 treatment zones/cm². Overall, 50% to 75% improvements in rhytides were noted at 3 months. In another study, 1 to 3 treatments with a fractional CO₂ laser delivering 300- μ m spots spaced to 2400 μ m (Quantel Medical, France) was used at varying fluences (120-240 mJ). Histologic examination showed coagulated epidermis 120 μ m in width and 500

to 1000 μ m in depth. At 5 days after treatment, the epidermis was restored and dermal fibrosis from 200 to 550 μ m was noted, followed at day 30 by neocollogenesis.⁴⁶ In a clinical study using the same laser, 40 patients received 1 to 3 treatments, and approximately 80% of patients had greater than 50% improvement up to 3 months after treatment.⁴⁷

Fractional delivery of the Er:YAG laser has also been recently investigated. Twenty patients were treated with a prototype fractional handpiece for the Sciton Profile™ Erbium:YAG laser (Sciton, Palo Alto, CA) with spot size of 250 μ m and fluences from 2.5 J/cm² to 25 J/cm² and final treatment density corresponding to 1% to 10% of skin surface area. Open wound care was necessary but there were no other side effects and healing was faster than for traditional Er:YAG laser.⁴⁸ Another prototype Er:YAG system (Palomar Medical Technologies, Burlington, MA) with stamping mode of delivery up to 5 mJ/mb was used to treat porcine skin, demonstrating linear shrinkage of surface area up to 20%. Histology showed well-defined columns of coagulated tissue surrounded by undamaged tissue with the depth of coagulation proportional to microbeam energy and/or number of stacked pulses.⁴⁹

Conclusion

In conclusion, fractional resurfacing appears to be a safe and effective treatment modality for correcting melasma, photodamage, rhytides, and scars with only moderate downtime and significant clinical efficacy. The fractional approach of laser delivery offers significant benefits in terms of rapid tissue healing and enables its use in all skin types and nonfacial areas which greatly expands the treatment capacity for laser resurfacing. The development of the newer ablative fractional devices may further increase clinical efficacy while minimizing the number of treatment sessions required to achieve optimal results.

Acknowledgments

We are grateful to Andrew Heling, Vikramaditya P. Bedi, and Brad Hauser of Reliant Technologies for providing the histologic photographs.

References

1. Anderson RR, Parrish JA: Selective photothermolysis: precise microsurgery by selective absorption of pulsed radiation. *Science* 220:524-527, 1983
2. Nanni CA, Alster TS: Complications of carbon dioxide laser resurfacing. An evaluation of 500 patients. *Dermatol Surg* 24:315-320, 1998
3. Alster TS: Cutaneous resurfacing with CO₂ and erbium:YAG lasers: Preoperative, intraoperative and postoperative considerations. *Plast Reconstr Surg* 103:619-632, 1999
4. Trelles MA: Laser ablative resurfacing for photorejuvenation based on more than a decade's experience and 1200 patients: Personal observations. *J Cosmet Dermatol* 2:2-13, 2000
5. Ruiz-Esparza J, Gomez de la Torre OL, Barba Gomez JM: UltraPulse laser skin resurfacing of the hands. *Dermatol Surg* 24:69-70, 1989
6. Ross EV, Sajben FP, Hsia J, et al. Nonablative skin remodeling: Selective dermal heating with a mid-infrared laser and contact cooling combination. *Lasers Surg Med* 26:186-195, 2000
7. Goldberg DJ: Full-face nonablative dermal remodeling with a 1320 nm Nd:YAG laser. *Dermatol Surg* 26:915-918, 2000

8. Lupton JR, Williams CM, Alster TS: Nonablative laser skin resurfacing using a 1540 nm erbium glass laser: A clinical and histologic analysis. *Dermatol Surg* 28:833-835, 2002
9. Fournier N, Dahan S, Barneon G, et al. Nonablative remodeling: a 14-month clinical ultrasound imaging and profilometric evaluation of a 1540 nm Er:Glass laser. *Dermatol Surg* 28:926-931, 2002
10. Khan MH, Sink RK, Manstein D, et al. Intradermally focused infrared laser pulses: Thermal effects at defined tissue depths. *Lasers Surg Med* 36:270-280, 2005
11. Manstein D, Herron GC, Sink RK, et al. Fractional photothermolysis: A new concept for cutaneous remodeling using microscopic patterns of thermal injury. *Lasers Surg Med* 34:426-438, 2004
12. Laubach H-J, Tannous Z, Anderson RR, et al. Skin responses to fractional photothermolysis. *Lasers Surg Med* 38:142-149, 2006
13. Hantash BM, Bedi VP, Sudireddy V, et al: Laser-induced transepidermal elimination of dermal content by fractional photothermolysis. *J Biomed Opt* 11:041115, 2006
14. Fisher GH, Kim KH, Berstein LJ, et al. Concurrent use of handheld forced cold air device minimized patient discomfort during fractional photothermolysis. *Dermatol Surg* 31:1242-1244, 2005
15. Laubach H, Chan HH, Rius F, et al. Effects of skin temperature on lesion size in fractional photothermolysis. *Lasers Surg Med* 39:14-18, 2007
16. Hantash BM, Bedi VP, Kapadia B, et al. In vivo histological evaluation of a novel ablative fractional resurfacing device. *Lasers Surg Med* 39:96-107, 2007
17. Rusciani A, Motta A, Rusciani L, et al. Q-switched alexandrite laser-assisted treatment of melasma: 2-year follow-up monitoring. *J Drugs Dermatol* 4:770-774, 2005
18. Angsuwarangsee S, Polnikorn N: Combined ultrapulse CO2 laser and Q-switched alexandrite laser compared with Q-switched alexandrite laser alone for refractory melasma: Split-face design. *Dermatol Surg* 29:59-64, 2003
19. Tannous ZS, Astner S: Utilizing fractional resurfacing in the treatment of therapy-resistant melasma. *J Cosmet Laser Ther* 7:39-45, 2005
20. Rokhsar CK, Fitzpatrick RE: The treatment of melasma with fractional photothermolysis: A pilot study. *Dermatol Surg* 31:1645-1650, 2005
21. Vasily DB: Treatment of melasma using the Starlux 1540 nm fractional handpiece. *Lasers Surg Med* 2007 S19:23, 2007 (abstr)
22. Wanner M, Tanzi E, Alster TS: Fractional photothermolysis: treatment of facial and nonfacial cutaneous photodamage with a 1,550-nm erbium-doped fiber laser. *Dermatol Surg* 33:23-28, 2007
23. Jih MH, Goldberg LH, Kimyai-Asadi. Fractional resurfacing for photoaging of hands. *Dermatol Surg* (in press)
24. Behroozan DS, Goldberg LH, Glaich AS, et al: Fractional photothermolysis for treatment of poikiloderma of Civatte. *Dermatol Surg* 32:298-301, 2006
25. Sukal S, Chapas A, Berstein L, et al: Eyelid tightening and improved eyelid aperture through fractional resurfacing. *Lasers Surg Med* S19:20, 2007 (abstr)
26. Kono T, Chan HH, Groff WF, et al: Direct comparison study of fractional resurfacing using difference fluences and densities for skin rejuvenation in Asians. *Lasers Surg Med* S19:16, 2007 (abstr)
27. Weinstein C, Bosnich R: High energy fractional resurfacing for acne scarring. *Lasers Surg Med* S19:34, 2007 (abstr)
28. Alster TS, Tanzi EL, Lazarus M: The use of fractional laser photothermolysis for the treatment of atrophic scars. *Dermatol Surg* 33:295-299, 2007
29. Chrastil B, Glaich A, Goldberg LH, et al: Fraxel SR1500 for the treatment of acne scars. *Lasers Surg Med* S19:34, 2007 (abstr)
30. Glaich AS, Chrastil B, Rahman Z, et al: Fractional photothermolysis for treatment of hypopigmented scars. *Lasers Surg Med* S19:59, 2007 (abstr)
31. Glaich AS, Chrastil B, Goldberg LH, et al: Fractional photothermolysis for the treatment of post-inflammatory erythema resulting from acne vulgaris. *Lasers Surg Med* S19:60, 2007 (abstr)
32. Alexiades-Armenakas MR, Bernstein LJ, Friedman PM, et al: The safety and efficacy of the 308-nm excimer laser for pigment correction of hypopigmented scars and striae alba. *Arch Dermatol* 140:955-960, 2004
33. Hirobe T: Proliferation of epidermal melanocytes during the healing of skin wounds in newborn mice. *J Exp Zool* 227:423-431, 1983
34. Bergamaschi O, Kon S, Doine Ai, et al: Melanin repigmentation after gingivectomy: A 5-year clinical and transmission electron microscopic study in humans. *Int J Periodontics Restorative Dent* 13:85-92, 1993
35. Machado Filho CD, Almeida FA, Proto RS, et al: Vitiligo: Analysis of grafting versus curettage alone, using melanocyte morphology and reverse transcriptase polymerase chain reaction for tyrosinase mRNA. *Sao Paulo Med J* 123:187-191, 2005
36. Rusfianti M, Wirohadidjodjo YW: Dermatological techniques for repigmentation of vitiligo. *Int J Dermatol* 45:411-417, 2006
37. Fulton JE, Rahimi AD, Mansoor S, et al: The treatment of hypopigmentation after skin resurfacing. *Dermatol Surg* 30:95-101, 2004
38. Jimenez GP, Flores F, Berman B, et al: Treatment of striae rubra and striae alba with the 585nm pulsed-dye laser. *Dermatol Surg* 29:362-365, 2003
39. Kawashita MY, Niwa ABM, Alves EV, et al: Treatment of stretch marks with Fraxel laser. *Lasers Surg Med* S19:72, 2007 (abstr)
40. Marra DE, Pourrabbani S, Fincher EF, et al: Fractional photothermolysis for the treatment of adult colloid milium. *Arch Dermatol* 143:572-574, 2007
41. Vasily DB: Treatment of resistant tattoos using the starlux 1540 nm fractional handpiece. *Lasers Surg Med* S19:80, 2007 (abstr)
42. Rahman Z, Tanner H, Tounas J, et al: Ablative fractional resurfacing for the treatment of photodamage and skin laxity. *Lasers Surg Med* S19:15, 2007 (abstr)
43. Hale EK, Sukal S, Chapas AM, et al: Fractional carbon dioxide laser resurfacing of photodamage and acne scars. *Lasers Surg Med* S19:83, 2007 (abstr)
44. Rahman Z, Chan KF, Tanner H, et al: Report of a novel fractional ablative laser for tissue tightening. *Lasers Surg Med* S19:74, 2007 (abstr)
45. Weiss RA, Weiss MA, Beasley KL: Prospective clinical trial of a fixed spacing array computer scanned fractional CO2 laser for rhytides. *Lasers Surg Med* S19:16, 2007 (abstr)
46. Levy JL, Fournier N, Mordon S: CO2 fractional resurfacing combined with air cooling: Histologic investigation and optimal parameters determination. *Lasers Surg Med* S19:17, 2007 (abstr)
47. Angel S, Boineau D, Levy JL, et al: Fractional resurfacing combined with air cooling as a novel approach to skin tightening: study of selective digital dosing and preliminary clinical outcomes. *Lasers Surg Med* S19: 71, 2007 (abstr)
48. Pozner JN, Goldberg DJ, Glanz S: Fractional erbium resurfacing: histologic and early clinical experience. *Lasers Surg Med* S19:73, 2007 (abstr)
49. Dierickx C, Khatari K, Altshulder G, et al: Fractionated delivery of Er:YAG laser light to improve the efficacy and safety of ablative resurfacing procedure. *Lasers Surg Med* S19:16, 2007 (abstr)