



Endovenous Laser Ablation and Sclerotherapy for Treatment of Varicose Veins

Natasha Brasic, MD,* David Lopresti, MD,[†] and Hugh McSwain, MD[†]

Superficial venous insufficiency is a common problem associated with varicose veins. Venous insufficiency and varicose veins can be symptomatic, but more commonly they are a cosmetic concern. In this article, we discuss the relevant anatomy and pathophysiology of superficial venous insufficiency, review the current literature for varicose vein treatment, and cover the technical aspects of diagnosing and treating superficial venous insufficiency. Saphenofemoral junction incompetence with resultant greater saphenous vein reflux is the most common cause of varicose veins; because this condition constitutes the majority of patients encountered in practice, we will concentrate on this area. Endovenous laser ablation and sclerotherapy are covered, including patient workup and selection, procedure set-up, and anesthesia.

Semin Cutan Med Surg 27:264-275 Published by Elsevier Inc.

Superficial venous insufficiency is a common problem associated with varicose veins, which are usually asymptomatic, but may cause aching, itching, edema, discoloration, or even frank ulceration. Varicose veins affect approximately 32% of women and 40% of men.¹ Multiple etiologies for varicose veins exist and include genetics, obesity, pregnancy, intraabdominal malignancy, and chronic, prolonged standing. Secondary causes typically include deep venous thrombosis.

Varicose veins are simply superficial veins that have expanded in response to increased pressure and turbulence. The superficial veins serve as a primary collecting system and are connected via perforating veins to the deep veins, which carry blood from the leg back to the central circulation. Superficial vein walls are inherently weak (except for the greater saphenous vein [GSV] in the thigh) because they are supported only by subcutaneous tissue and skin rather than by fascia and muscle. Valve failure is the most common cause of symptomatic venous pathology. Valvular incompetence is

multifactorial and may be caused by congenitally malformed leaflets, thrombosis, chronic turbulent flow, or thrombophlebitis. Valvular incompetence, regardless of its primary site or etiology, causes a leakage of high pressure into the superficial veins and a predictable progression of disease, with sequential failure of valves as the superficial veins become progressively more dilated in response to the increased backpressure. If localized, this dilation leads to appearance of cosmetic telangiectasias (spider veins) and if more diffuse, larger veins become more tortuous (varicose veins).

Relevant Anatomy and Pathophysiology

A detailed description of the anatomy of the lower-extremity venous system is beyond the scope of this article. If more in-depth information is desired, please see the review by Min et al.² The return of blood to the heart from the lower extremities is through 2 interconnected pathways—the superficial and deep venous systems. The superficial system consists of subcutaneous thin-walled veins and truncal veins. The most pertinent veins of the superficial venous system for the purposes of this article are the GSV and the lesser saphenous vein (LSV).

The GSV begins at the level of the foot, tracks anterior to the medial malleolus, and continues on the medial aspect of the leg and thigh until it ends at the saphenofemoral junction (SFJ) (Fig. 1A). The SFJ is the site of the GSV entering the femoral vein of the deep venous system (Fig. 2). The SFJ is the most common site of venous reflux into the GSV.

*Department of Radiology, University of California San Francisco, San Francisco, CA.

[†]Department of Radiology, Naval Medical Center San Diego, San Diego, CA. The views expressed in this article are those of the authors and do not reflect the official policy or position of the Department of the Navy, Department of Defense, or the United States Government. None of the authors has identified a potential conflict of interest.

Address correspondence to H. McSwain, Department of Radiology, Naval Medical Center San Diego, 34800 Bob Wilson Drive, San Diego, CA 92134. E-mail: hmcswain@hotmail.com

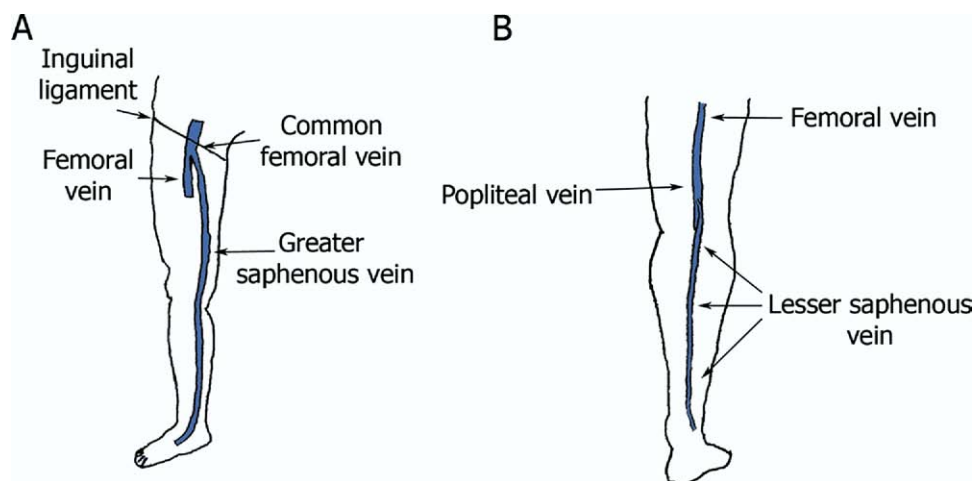


Figure 1 (A) Basic lower extremity venous anatomy. The GSV runs along the medial aspect of the leg and thigh to empty into the deep venous system (femoral vein) at the saphenofemoral junction. (B) Posterior view of the lower leg demonstrating the LSV running in the midline of the calf to empty into the deep venous system (popliteal vein) around the level of the knee at the saphenopopliteal junction.

The LSV starts at the level of the foot, tracks posterior to the lateral malleolus and continues in the midline of the calf until it ends at the saphenopopliteal junction (SPJ) around the level of the knee (Fig. 1B); the SPJ is the site of the LSV entering into the popliteal vein of the deep venous system, though other less common anatomic variations are possible (Fig. 3). The SPJ may be incompetent and serve as the source of venous reflux but this occurs much less frequently than SFJ incompetence.

Both the GSV and the LSV are in the saphenous compartment at their respective levels in the lower extremity. The saphenous compartment lies between the deeper muscular fascia and the more superficial saphenous fascial layer (Fig. 4). On ultrasound (US), these fascial layers are easily identified as echogenic (white) lines (Fig. 5). The GSV and LSV tributary veins are present in the subcutaneous fatty tissues superficial to the saphenous fascia; because the tributaries are thin-walled and not supported by fascial layers, these veins can enlarge greatly when distended giving the typical appearance of varicose veins.

The deep and superficial venous systems are connected by perforating veins, aptly named because they perforate the muscular fascia in their course. The larger perforating veins have venous valves that normally only allow blood flow from the superficial to the deep venous system.

The return of lower-extremity venous blood to the heart is a complex mechanism. Three major components of this mechanism are (1) integrity of the lower-extremity muscular pump, (2) unobstructed venous outflow, and (3) venous valve competency. Incompetent venous valves are the most common source of venous insufficiency (and thus varicose veins).

Venous valves are bicuspid one-way valves present every 3 to 4 cm in normal lower-extremity veins (deep, superficial, and larger perforating components). These valves help keep venous flow in the caudal to cranial direction and from peripheral to central. Valvular insufficiency or incompetence

(VI) can be primary or secondary (Fig. 6). 1° VI is caused by inherent abnormality of the valve and can be congenital or acquired. 2° VI occurs when venous valves are normal but distension of a vein causes an inability of the valves to oppose each other. With 2° VI, treatment of the underlying cause of incompetence may allow the vein to decompress and regain valvular competence.

Literature Review of Treatments for Varicose Veins

Multiple techniques have evolved in the treatment of small and large varicose veins. Long-term success in the treatment of leg varicosities, when the SFJ and the GSV are involved, depends on the elimination of the highest point of reflux and the incompetent venous segment. This elimination may be accomplished surgically or by endovascular methods. Seventy percent of varicose veins are attributable to incompetence at the SFJ with reflux along the GSV.³

The conventional treatment of saphenofemoral venous incompetence is surgery: ligation and GSV stripping.⁴ Ligation of varicosities is an older approach to treatment of varicose veins in which multiple incisions are made overlying visible varicosities and ligatures are placed every 2 to 3 cm. This method has proven ineffective because it fails to treat the origin of venous reflux and fails to extirpate the varicosities themselves.⁵ Patients treated in this way usually return after a few months with recurrent varicosities immediately adjacent to the incision sites.

GSV stripping is another surgical technique where the GSV is removed with the use of a stripping tool. The SFJ and its tributaries are flush ligated through a 2- to 3-cm incision placed in the skin slightly above the groin crease. After ligation and division of the GSV at the SFJ and all of its side branches along the medial thigh and knee, the GSV is pulled

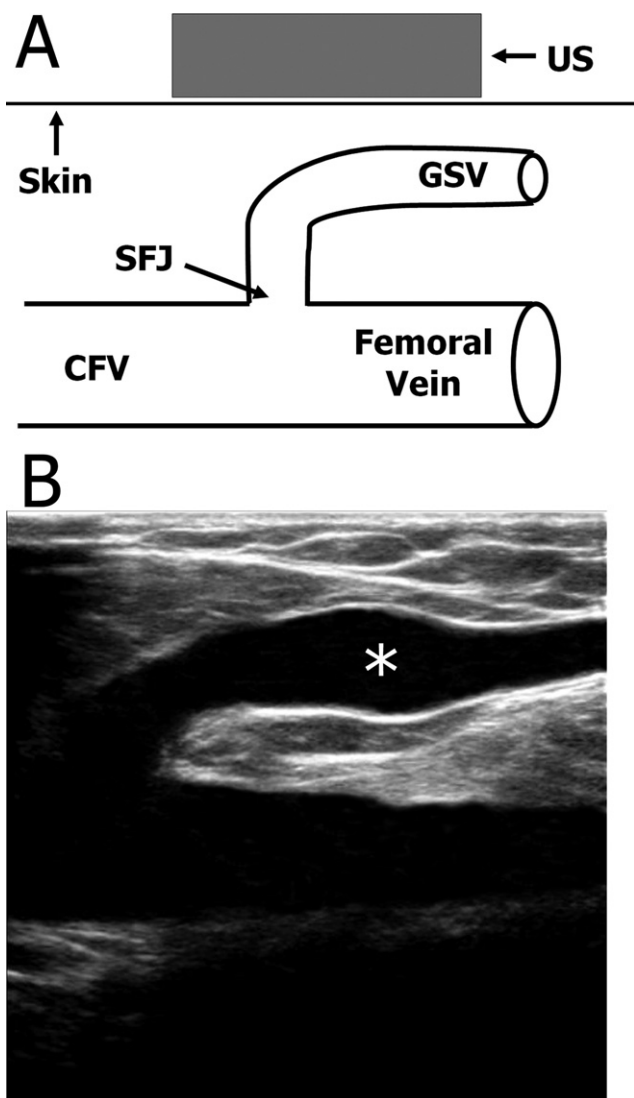


Figure 2 (A) Line drawing and (B) US, long view, demonstrate the SFJ region anatomy. Asterisk (*) denotes the GSV on the US view. The femoral vein and the CFV are part of the deep venous system, whereas the GSV is part of the superficial venous system; the SFJ is the site of the GSV emptying into the deep system.

from the leg usually with the aid of an endovascular stripping tool.

Surgical treatment of varicose veins is usually performed as a day procedure, with the patient under general anesthesia. There is recognized morbidity associated with day surgery, and recovery to normal activity is usually on the order of 2 to 3 weeks.^{6,7} Potential complications of surgical vein therapy include neurosensory loss (4-25%),⁸⁻¹⁰ wound infection (2-15%),^{10,11} hematoma (<30%),¹² and lymph leak or deep venous thrombosis (<2%).¹³ Recurrence remains a problem despite advances in surgical technique; clinical recurrences are as high as 21-37% at 5 years post surgery.^{9,14,15}

During the last 2 decades, less-invasive endoluminal methods of treating varicose veins have been developed as alternatives to surgery, with the intention of reducing morbidity and recovery time. Radiofrequency ablation (RFA) and endovenous laser ablation (ELA) are the most promising of

these methods. These techniques aim to abolish GSV and lesser saphenous vein reflux.

Endovenous RFA (Closure System, VNUS Medical Technologies, Inc, Sunnyvale, CA) of the GSV was first described by Goldman in 2000 and was approved by the Food and Drug Administration in 1999.¹⁶ The Closure system consists of a bipolar generator and catheter, with sheathable electrodes at the catheter tip. The GSV is cannulated at the level of the knee, and the catheter is inserted over a guidewire. The catheter is advanced 2 cm caudal to the SFJ as confirmed by sonography. The catheter is then slowly withdrawn at a rate of 3 cm/min, maintaining a temperature of 85°C. RF energy is passed through the unsheathed electrodes to cause controlled heating of the blood vessel wall. It has been suggested based on animal studies that the heat applied to the vein wall during RFA causes denaturation of the collagen fibers, resulting in vein constriction of the vessel wall rather than thrombosis of the vein.¹⁷ This results in vein shrinkage or occlusion by contraction of the venous wall collagen. When the vein

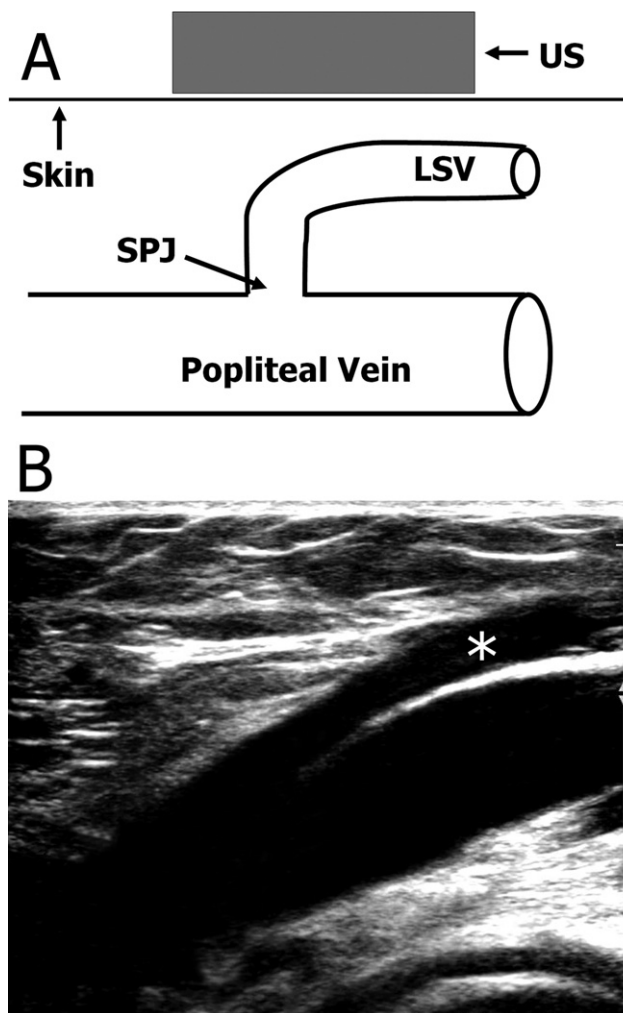


Figure 3 (A) Line drawing and (B) US, long view, demonstrate the SPJ region anatomy. Asterisk (*) denotes the LSV on the US view. The popliteal vein is part of the deep venous system, whereas the LSV is part of the superficial venous system; the SPJ is the site of the LSV emptying into the deep system.

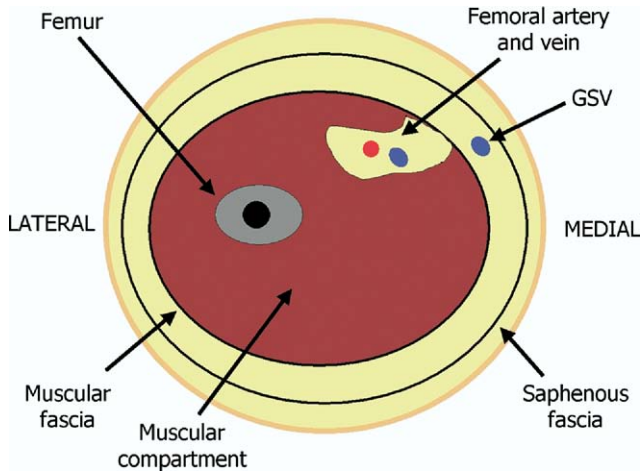


Figure 4 Axial cross section of the right mid-thigh. The GSV is present in the saphenous compartment deep to the saphenous fascia but superficial to the muscular fascia. The femoral vein (part of the deep venous system) is in the muscular compartment deep to the muscular fascia.

wall collapses, the catheter is slowly withdrawn, closing the vein. Compression is applied immediately postprocedure, with full compression stockings to be worn for 3 weeks post procedure.

RFA is considered a safe, effective procedure, with 2 prospective, randomized controlled trials comparing the RFA closure procedure and surgical ligation and stripping showing advantages to RFA. In a study of 28 patients, Rautio and coworkers¹² showed reduced postoperative pain, shorter sick leaves, and faster return to normal activity in patients treated

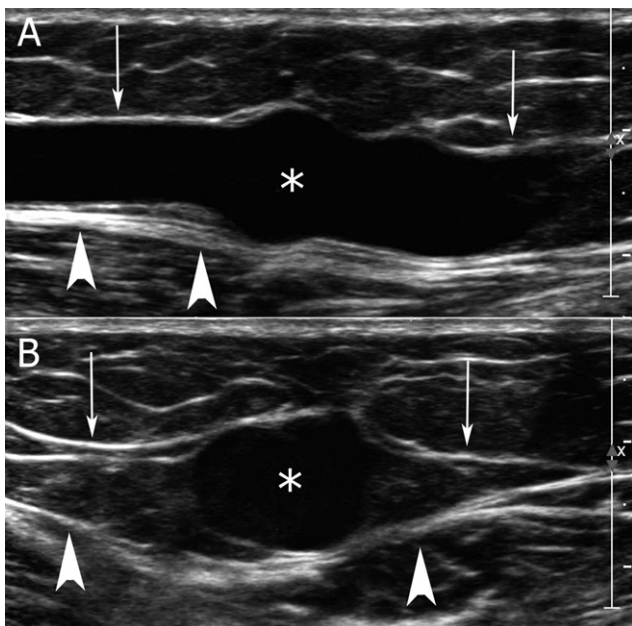


Figure 5 (A) Long view and (B) transverse view demonstrate the GSV (asterisk) on US within the saphenous compartment of the thigh. The saphenous fascia (white arrows) forms the superficial boundary of the compartment; the muscular fascia (white arrowheads) forms the deep boundary.

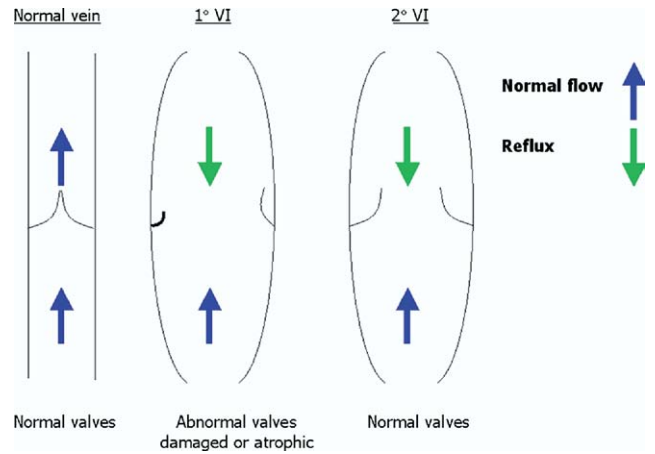


Figure 6 The normal vein has normal size and valves. In 1° VI, the valves are abnormal allowing reflux and venous dilation. In 2° VI, the valves are normal, but backpressure dilates the vein not allowing the valves to coapt. This leads to reflux; if the cause of the backpressure is treated, there is a chance the vein can regain normal function.

with RFA. A study by Lurie and coworkers¹⁸ involving 81 limbs treated by either RFA or ligation and stripping also showed significant advantages in return to normal activity and pain scores with RFA. In terms of success of RFA with the principle outcome being occlusion of the GSV as determined by ultrasound, a recent review by Beale and coworkers, in 2004,¹⁹ showed success rates ranging from 68% to 100% up to 24 months after the procedure.^{12,17,20-26} In the same review,¹⁹ frequency of complications was evaluated among 6 studies, reporting paresthesias in up to 19% of patients,^{12,17,24} burns in up to 4%,^{22,24} and phlebitis in 2% to 8%.^{12,22} Burns and parasthesias occurred less frequently with the use of perivenous tumescent anesthesia.¹⁷ DVT is reported in 1% of

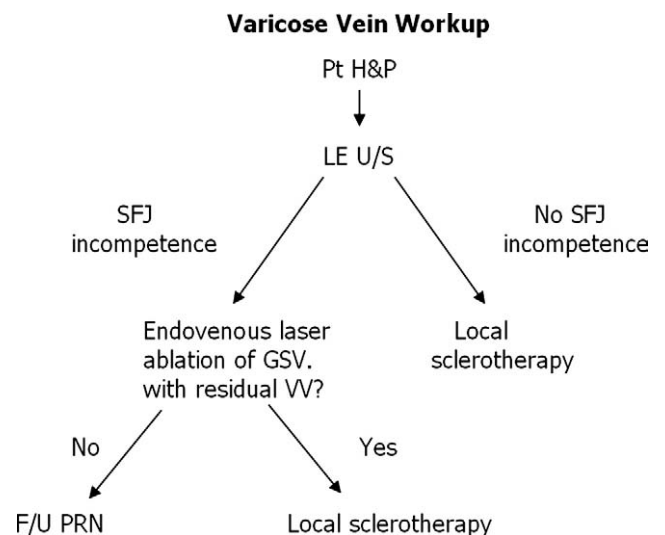


Figure 7 The workup for the patient with varicose vein (VVs). Patients with SFJ incompetence, as visualized with US, receive ELA treatment initially. For any residual VV at the follow-up appointment after ELA, local sclerotherapy is performed. If no SFJ incompetence is present on US, local sclerotherapy is the treatment of choice.

patients with pulmonary embolism incidence of 0.3%.²² In a study by Hingorani and coworkers²⁵ in 2004, duplex sonography of limbs status after recent successful GSV occlusion by RFA had a DVT rate of 16%. The authors of the study recommended mandatory early duplex sonography in all patients status after RFA.

Drawbacks to RFA relative to surgical vein therapy for the health care provider are high cost of the generator and disposable catheters. In addition, at a pullback rate of 3 cm/min, time consumption involved in catheter withdrawal becomes a significant issue, particularly when persistent flow is detected in the vein after the first ablative pull through, necessitating repeat treatments and additional time cost.

Endovenous laser ablation (ELA) is another minimally invasive alternative to conventional surgery for superficial venous insufficiency, where laser energy is used to ablate the veins. This procedure was designed as an alternative to RFA. The currently used technique was first reported in large series by Navarro and Min.^{27,28} ELA releases thermal energy to the blood and venous wall, causing localized tissue damage, thereby promoting vein collapse. The vein shrinkage is a

gradual process where endothelial damage, focal coagulative necrosis, shrinkage, and thrombotic occlusion of the vein lead to resorption of the vein over several months. ELA was approved for treatment of varicose veins by the Food and Drug Administration in 2002 and by the National Institute of Health and Clinical Excellence in 2004.

To date, several clinical studies in which the authors examined the efficacy of ELA have been published, showing high vein occlusion rates. Success rates range between 90% and 100% at follow-ups ranging from 1 to 24 months.²⁷⁻³³ Complications of ELA include bruising or ecchymosis in 24-49%,^{31,34} phlebitis in 1-38%,^{30,31,33,34} cellulitis in 2.6%,³³ hematoma in 1.3%,³³ and edema in 2.6%.³³ Reported rates of DVT range from 0% to 2.3%.^{33,35,36} Because the laser causes direct thermal damage to surrounding tissues, rare cutaneous thermal injury complications have been reported.^{37,38}

Several wavelengths have been proposed for the diode laser, with 810, 940, and 980 nm the most commonly used. 810 nm is the isosbestic point, where laser energy of this wavelength is maximally absorbed by red blood cells, allowing heating of the blood and vein wall. Power is usually set

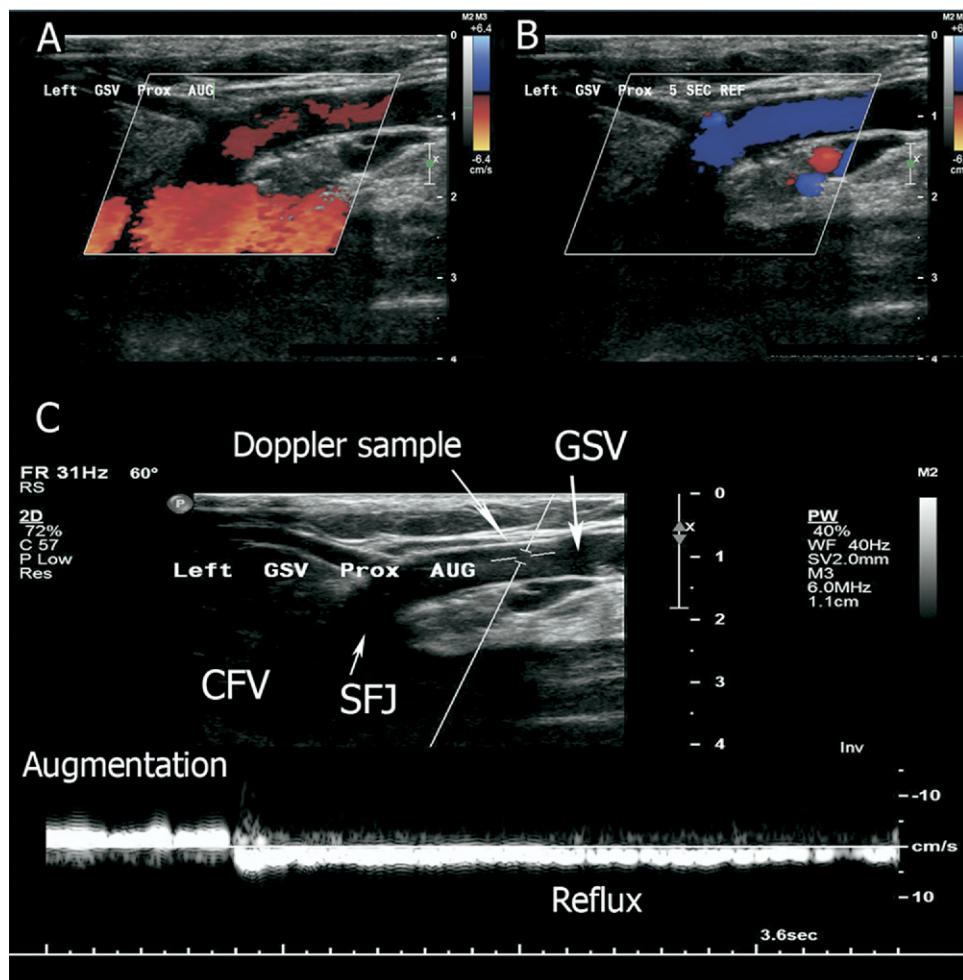


Figure 8 Color Doppler with calf augmentation (A), color Doppler with reflux (B), and pulsed-wave Doppler (C) of the left SFJ region. (A) Demonstrates expected antegrade flow at the SFJ region (red color) with augmentation. (B) shows opposite flow denoted by blue (reflux) in the GSV after the augmentation has stopped. (C) shows interrogation of the GSV with augmentation (white flow above the baseline) and reflux (white flow below baseline).

between 10 and 15 W. The energy is administered endovenously, either in a pulsed or continuous fashion, with both equally effective. For pulsed mode, the fiber pullback rate is 3 mm to 5 mm every 2 seconds; with continuous mode, the pullback rate is 1-3 mm per second. A study of 51 patients showed no difference in outcome, physical condition, symptoms, or adverse events between use of 810- and 980-nm lasers.³⁹ Higher doses of laser energy have been shown to be more effective in vessel occlusion and nonrecanalization, particularly at doses greater than 80 J/cm.^{36,40} Theivacumar and coworkers⁴¹ reported on the influence of several factors relating to GSV occlusion after ELA. Energy density (J/cm) was the main determinant of successful GSV occlusion; energy density >60 J/cm always resulted in GSV occlusion without an increase in complication rate.

A retrospective review comparing the early efficacy and complications of ELA and RFA in 130 limbs found a greater need for repeated treatment of the saphenous vein during the same operation in the RFA group compared with the ELA group (17% versus 0%) because of duplex evidence of vein patency after the first pass of the Closure catheter.³³ In this study, immediate technical success was reported as 100% in the ELA and 96% in the RFA groups. Follow-up sonography within 3 weeks confirmed occlusion of the GSV in 94% of ELA-treated limbs and in 91% of those treated with RFA.

Sclerotherapy is widely used for the treatment of leg veins less than 4 mm in diameter (reticular varicosities and telangiectasias), and for residual varicosities after surgery or endovascular treatment. Veins larger than 4 mm can be successfully treated if adequate compression follows injection. Good compression can reduce the risk of developing a symptomatic thrombophlebitis in these larger veins, making sclerotherapy an effective and scarless alternative to stab avulsion. Careful judgment should be used, however, when evaluating larger veins for sclerotherapy, including managing patient expectations, understanding compliance issues, and assessing the ability to achieve adequate compression.

During treatment, a sclerosant is injected directly into the vein, causing the irritated vessel lining to swell and seal itself, preventing blood from reentering. The use of foam sclerosing agents has been described as early as 1939⁴² and, since then, many technical improvements have been made.

Foam and liquid sclerotherapy have been used in conjunction with ELA for obliterating residual varicosities. Presently, the most-common sclerosants worldwide are sodium tetradecyl sulfate (Sotradecol; Angiodynamics, Queensbury NY) and polidocanol. Polidocanol has a long worldwide history of safety and efficacy; it has been used in the United States for vein sclerotherapy as an off-label use, ordered from compounding pharmacies. Sotradecol gained Food and Drug Administration approval for use in lower-extremity vein sclerotherapy in 2004 and comes in 1% and 3% formulations.

The most current widely used method of foam production using a 3-way stopcock device was described by Tessari et al in 2001⁴³ and, since then, the superiority of foam over liquid sclerotherapy has been reported.^{44,45} A sclerosing solution is mixed into foam with air with the use of 2 syringes and a

3-way stopcock. The dilution of sclerosant to air (1:3 to 1:6) and volume of foam (5 to 30 mL) varies per center.

Foam sclerotherapy is contraindicated in pregnancy, breastfeeding, allergy to the sclerosant, immobility, significant deep vein incompetence, and thrombophilia.⁴⁶ Complications include skin hyperpigmentation, skin necrosis, phlebitis, transient lymphedema, allergic reaction, transient scotoma, or confusional states. Fewer than 10 cases of DVT have been reported,^{47,48} none of which led to pulmonary embolism.

Initial Evaluation and Patient Workup

Although some of our patients present with symptomatic varicose veins, the majority of patients present with esthetic concerns. After the history and physical, patients undergo lower extremity color duplex sonography to assess for venous incompetence (Fig. 7).

With advances in technology during the last 5 to 10 years, US units that include gray-scale imaging, color Doppler, and pulsed-wave Doppler are relatively economical and portable.

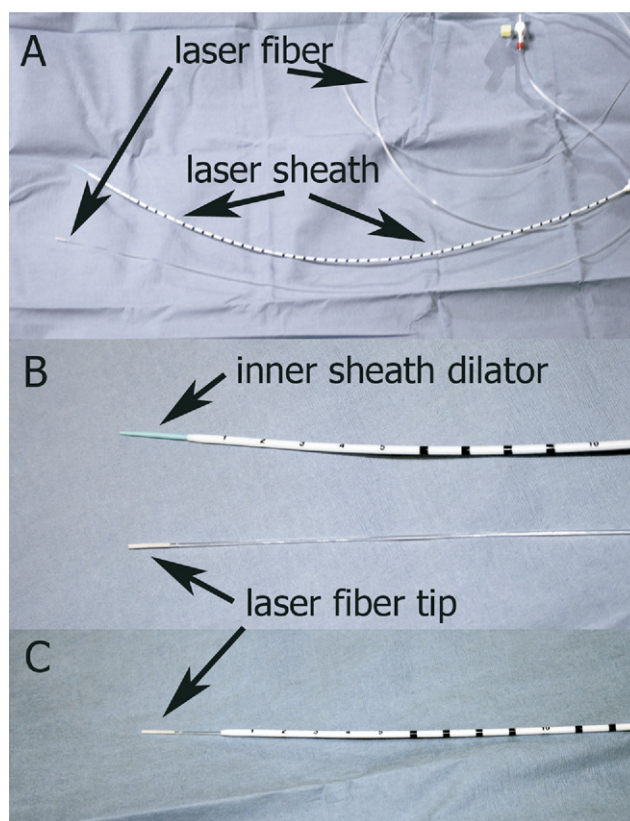


Figure 9 (A) 4-F, 55-cm laser sheath along side the laser fiber. Note the graduated black marks on the sheath, which serve to measure the withdrawal rate of the laser during treatment. (B) Magnified view of the distal most aspect of the sheath and fiber. The final 5 cm of the sheath are marked to help the operator stop the laser before withdrawal from the skin. (C) Laser fiber is shown in place in the laser sheath. Note the laser fiber tip projects approximately 2 cm beyond the sheath tip.

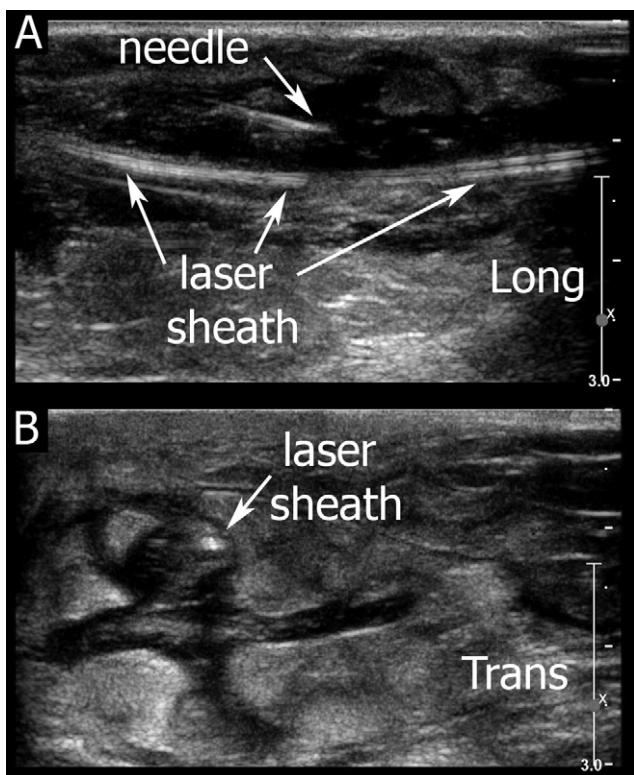


Figure 10 (A) Demonstrates the tumescent anesthesia needle in the saphenous compartment on US (long view). The laser sheath is visible and the dark area surrounding it is the lidocaine solution. (B) is a transverse view that demonstrates the marked collapse of the vein around the laser sheath as the result of tumescent anesthesia (dark area).

The US unit needs gray-scale and pulsed-wave Doppler capabilities with a high-frequency linear US probe (7.5–10 MHz) and a method to document the US examination (ie, printer or digital storage). Gray-scale Doppler US is used to assess the veins' morphology and compressibility. Pulsed-wave Doppler and/or color Doppler are used to assess for venous reflux.

Because of the scope of this article, the ultrasound examination will be discussed only briefly. Please refer to the review by Min et al² on the US evaluation of lower-extremity venous insufficiency for a more detailed discussion. The patient is dressed in a gown and stands while the US evaluation is performed. The examined leg is slightly externally rotated slightly with the majority of the patient's weight on the contralateral leg. The severity of reflux in the superficial (GSV and LSV) and deep venous systems (femoral and popliteal veins) is assessed with the use of real-time US by having the patient perform a Valsalva maneuver; calf-augmentation performed by the US operator is also done to assess reflux. Reflux is defined as reversal of flow lasting at least 0.5 seconds.⁴⁹ The size of the GSV and LSV is measured. When the patient is in the standing position, the GSV is usually ≤ 4 mm in diameter and the LSV is usually < 3 mm. Although abnormal reflux may be present, we use a GSV diameter of > 5 mm and > 2 seconds of reflux as a threshold for performing endovascular treatment (Fig. 8).

We offer ELA and foam sclerotherapy as treatment options for patients with varicose veins. After the ultrasound evalua-

tion, the determination is made whether ELA is indicated for the patient. ELA is favored over RFA for the decreased procedure time and lower procedure cost.

Contraindications to the ELA procedure include active deep vein thrombosis; significant peripheral arterial disease; advanced liver disease, which may cause intolerance to local anesthetic; uncorrected coagulopathy; or any contraindications to conventional vein stripping.

Special mention should be made regarding evaluation of pregnant patients. A pregnant patient can have her varicose veins evaluated during her pregnancy, but treatment is conservative (compression stockings) with a follow-up appointment 3 to 6 months after delivery. The patient is reassured that drastic improvement and possible resolution can occur with no other treatment after the hormonal changes and increased vascular volume have ceased.

Informed Consent

The informed consent should detail the indications, risks, benefits and alternatives to any planned procedure, as with

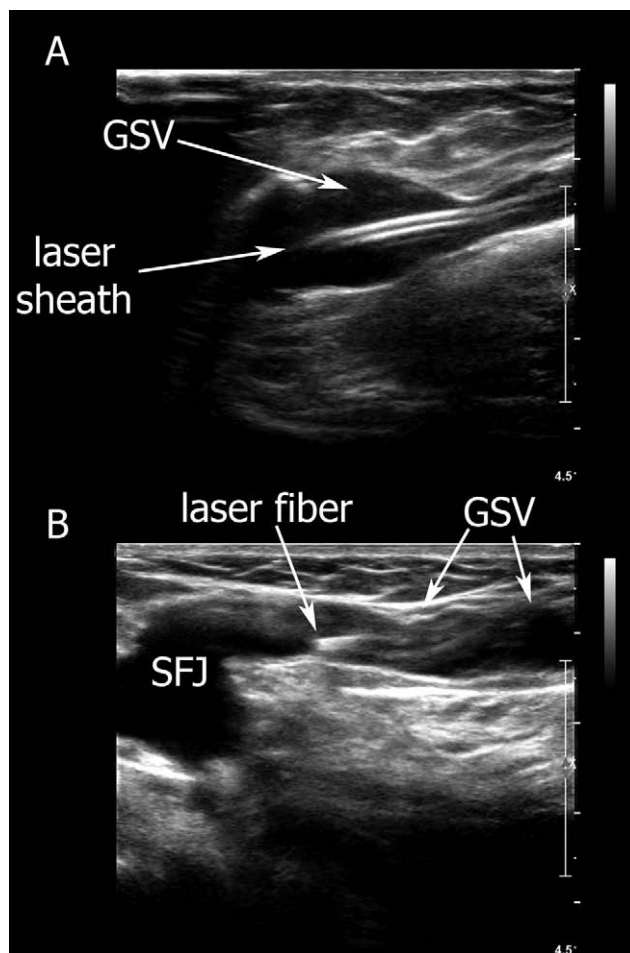


Figure 11 (A) Demonstrates the appearance of the laser sheath on US (long view). The sheath is visible as two parallel white lines. (B) demonstrates the appearance of the laser fiber tip proximal to the SFJ. Please note tumescent anesthesia was subsequently placed after these images were captured.



Figure 12 The laser set includes the laser console, foot pedal for laser activation, 2 pairs of protective eyewear, and a kit carrying case. The laser console has a touch screen with controls for choosing pulse or continuous laser function and wattage selection. The console also gives a running total of the energy administered to the vein being treated. Photo courtesy of Angiodynamics, Inc.

any medical procedure. A detailed explanation of venous disease and the prognosis for the patient is necessary to manage the patient's expectations. Both the patient and the physician should state their expectations for and goals of the procedure. Assuming a patient will be happy and satisfied with mere improvement in the appearance of the varicose veins will inevitably lead to disappointment with the results. Emphasis on two particular areas is suggested – any procedure performed will most likely not result in “perfect legs”; venous disease is a chronic disease and the patient should not be surprised at the appearance of new areas of abnormalities in the future. Color photography of the areas pre- and post-treatment is invaluable in documenting progress in the treatment of venous patients, especially when the primary indication is cosmesis.

ELA Technique

We will discuss the technique for GSV ablation because this is the ELA procedure most commonly performed. The gowned patient is placed supine on the procedure table. We perform our ELA procedures in a fluoroscopy capable suite. Although the use of fluoroscopy with venogram is not necessary to perform ELA, we have found it helpful in select cases.

The patient's ipsilateral hip is externally rotated and the medial thigh is prepared and draped in a sterile fashion. Of note, the venous access to the GSV is frequently the most difficult part of the case. Anecdotally, we have found the use of chlorhexidine to sterilely prepare the leg can result in significant vasospasm of the underlying GSV if accessed above the knee. If access above the knee is required, then a Betadine prep locally applied for access may be helpful.

Our procedural anesthesia varies from patient to patient. During informed consent, we describe the procedure in detail, including tumescent anesthesia. The patients are usually very forthcoming about their tolerance for pain. The patient and the physician then select the level of anesthesia provided. Our op-

tions include (1) no anesthesia other than the local anesthesia at the access site and the tumescent anesthesia along the GSV. This is the minimum level of anesthesia our patients receive. (2) 2.5% lidocaine/prilocaine cream (Astrazeneca, London) placed on the skin over the GSV where the tumescent anesthesia injections will be made. (3) Oral diazepam 5–10 mg administered 30 minutes before the procedure. (4) Intravenous conscious sedation with midazolam and fentanyl titrated to effect and monitored by qualified nurse.

With the patient prepared and draped, the GSV at and around the level of the knee is interrogated with sterile US technique. The site for venous access is chosen. Ideally, the GSV just below the level of the knee is selected for access. If the GSV at this level appears small enough to cause access problems, a site more cranial can be chosen. Strategies to distend the GSV include tilting the patient into a reverse Trendelberg position and maintaining a comfortable ambient procedure room temperature.

The GSV is accessed under US guidance using a 0.021-inch micropuncture needle (Cook, Bloomington, IN). After access is obtained using the micropuncture set, a 0.035-inch, 3-mm J guidewire is advanced into the GSV. A laser sheath is

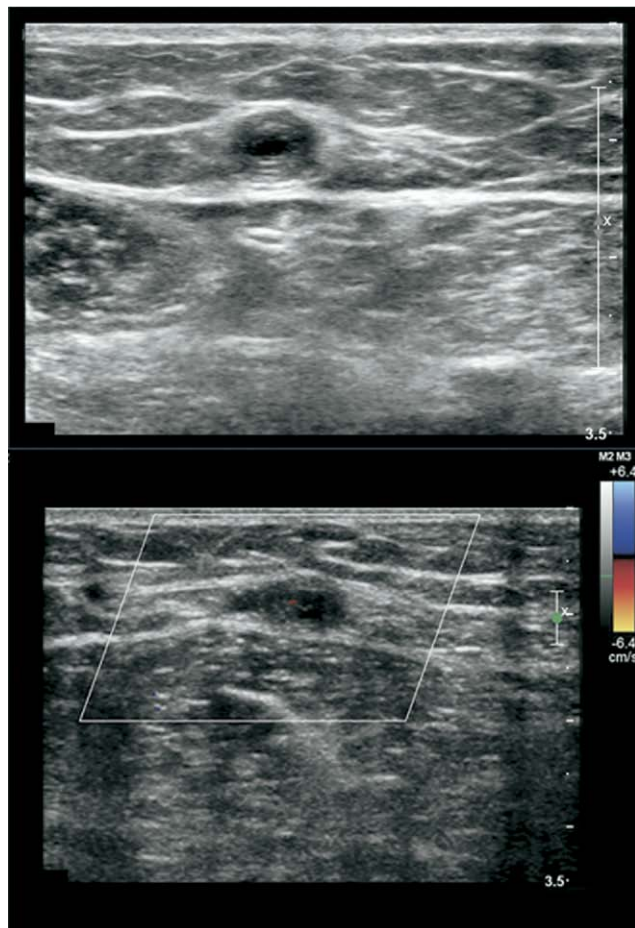


Figure 13 Normal appearance of GSV post-ELA. On the top image, the vein has a thickened wall. On the bottom image, there is no flow by color Doppler US. Other expected changes on US post-ELA (not shown) include a decrease in vein caliber and noncompressible vein over the treated segment.

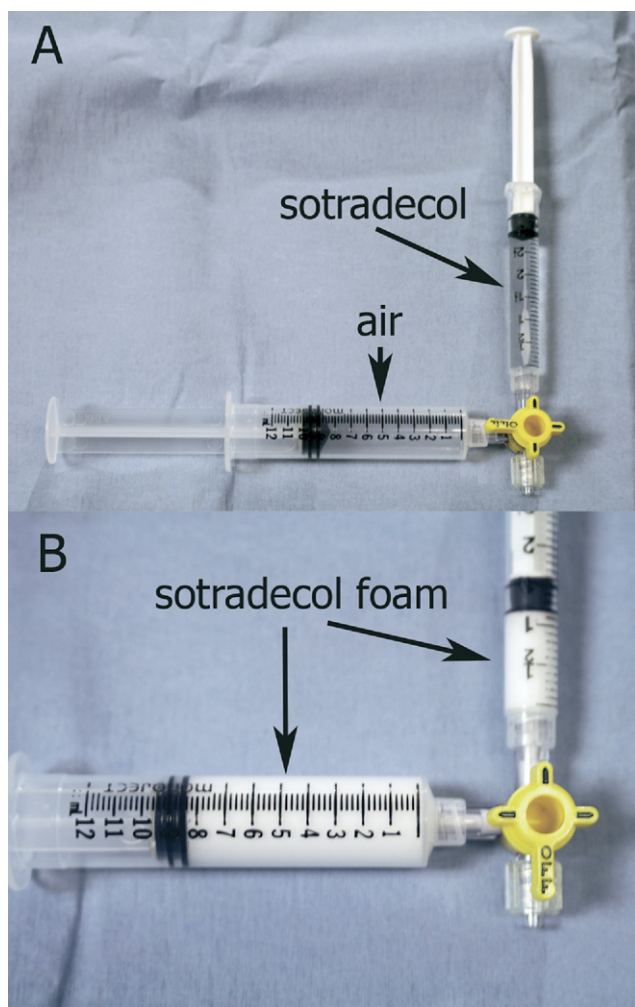


Figure 14 (A) Setup for sclerosant foam preparation. The 3-mL syringe contains 1 mL of 3% sotradecol in 2 mL of normal saline; the 12-mL syringe contains 9 mL of air. (B) Foam after vigorous mixing.

placed into the GSV over the 0.035-inch guidewire. There are several different companies for the laser sheath and catheter. We use a laser kit which contains a 4-French, 55-cm sheath and laser fiber (Vascular Solutions, Maple Grove, MN); the sheath has calibrated markings which are useful during the laser pullback (Fig. 9). The 4-F laser sheath is positioned in the GSV with the tip at the SFJ.

Tumescent anesthesia around the GSV is administered from the access site at the level of the knee cranial to the SFJ. The tumescent anesthesia reduces the patient's pain and decreases the risk of cutaneous injury by acting as a heat sink. We use a mixture of 60 mL of 1% lidocaine, 10 mL of sodium bicarbonate, and 530 mL of 0.9 normal saline. A 20-cm, 22-gauge spinal needle is used to minimize the number of injection sites. Under real-time US guidance, the perivenous tissues are injected with the anesthesia solution (Fig. 10).

After the tumescent anesthesia has been administered, the laser fiber is advanced through the laser sheath. The laser fiber tip will project approximately 2 cm beyond the sheath tip. The sheath/laser fiber are pulled back under US guidance until the distal most tip of the laser fiber is ~2 cm caudal to

the SFJ (Fig. 11). The laser fiber is then connected to the 980-nm diode laser source (Angiodynamics) (Fig. 12). Before the actual laser administration, everyone in the room (the patient and staff) must put on laser protective eyewear.

The laser is set to 15 W on continuous mode. While activating the laser via footpedal, the laser fiber and sheath are pulled back as a unit at ~0.5 cm/s. The pullback rate is monitored by assessing the calibrated marks on the sheath and a digital stopwatch. The pullback is performed until ~2 cm of laser fiber remains in the GSV. This can be assessed by US or using the sheath markings.

The laser unit is then turned off and the sheath and laser fiber are removed from the patient; the length of GSV treated (measured by the markings on the laser sheath in cm) and the total energy used (recorded by the laser generator console in Joules) are recorded. From this information, the energy delivered (in J/cm) is calculated. Manual pressure is held over the access site to obtain hemostasis. Simultaneously, the leg is elevated to achieve ~90° of hip flexion. The thigh and knee are wrapped with an elastic compression bandage (ACE wrap). A thigh-high graduated compression stocking (30-40 mm Hg) is placed on the leg over the compression wrap.

The patient is monitored after the procedure. The length and extent of monitoring depend on the level of anesthesia received. For intravenous conscious sedation, the patient is monitored by a nurse for 45 minutes after the procedure.

After discharge, the patient is given instructions regarding activity level, pain control, the use of a compression stocking, and follow-up. The patients are encouraged to ambulate after the procedure. When stationary, it is recommended to elevate the leg. Pain control after the procedure should be accomplished with a nonsteroidal antiinflammatory medication. The compression stocking should not be taken off for 72 hours. After this, the compression dressing (ACE wrap) may be removed. The patient may bathe after 72 hours; after this, until 2 weeks after the procedure, the compression stocking should be worn at all times unless bathing or sleeping. The patient is instructed to follow-up in 4 weeks. An US is performed at that time to assess the GSV and deep venous system (Fig. 13). We do not routinely



Figure 15 The Vein Lite (Wagner Medical) consists of the power source, a fiber optic cable, and a C-shaped light output. A dial on the power source allows for adjustment of the light output (up to 150 W).

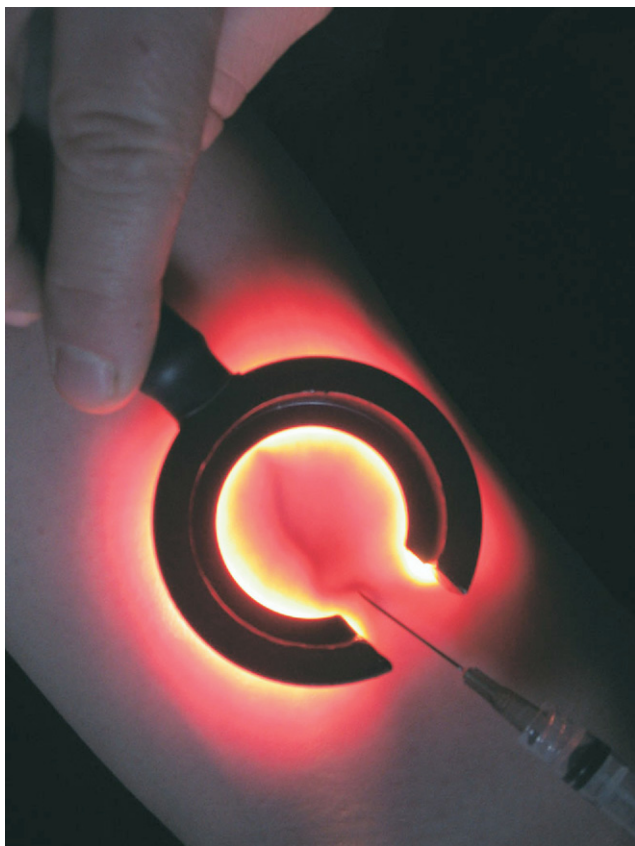


Figure 16 The use of the vein light to highlight veins for foam sclerotherapy injection is demonstrated. Photo courtesy of Wagner Medical, Inc.

do US assessment after 1 week to check for possible DVT. We think that the proper placement of the laser fiber caudal to the SFJ decreases the risk of thrombosis enough to mitigate against universal US interrogation postprocedure. If a patient has clinical signs of DVT, then US is performed.

Sclerotherapy Technique

The patient is brought into the procedure room in a gown. The patient identifies any areas of concern. These areas are

marked with an indelible surgical marker. When the areas have been identified and marked, the patient is positioned on the procedure table appropriately. The areas of concern are cleaned with a chlorhexidine solution. The 3% Sotradecol solution (Angiodynamics) is prepared for foam sclerotherapy. The Sotradecol is diluted by adding 2 mL of normal saline to 1 mL of Sotradecol in a 3-mL syringe. The 3-mL syringe is connected to a 3-way stopcock with a 12-mL syringe containing 9 mL of air (Fig. 14); the syringes are rapidly depressed sequentially to create the foam (1:3 sclerosant:air). A 3-mL syringe is universally the best size syringe for treating most varicosities because of the ability to modulate the pressure applied. Use of larger volume syringes will result in more incomplete treatments secondary to venous rupture. Very small veins may be easier to treat successfully with a 1 mL syringe.

A vein light (Wagner Medical, Middlebourne, WV; Fig. 15) is used to identify the reticular vein (Fig. 16) and a 26-G needle is placed into the vein with return of blood confirmed. The foam is injected through the needle while the operator observes the foam displace the blood from the vein. Extravasation of the foam is minimized using this technique. The needle is removed at the end of the injection.

After all injections are completed, pressure dressings are placed on the veins treated and an elastic compression wrap is secured over the dressings. The patient is encouraged to wear the compression dressing for 5 days continuously, taking it off only to shower. In our experience, this dressing minimizes the chances of trapped blood and phlebitis in the treated vein. The patient is instructed to follow up in 4 weeks. We do not obtain posttreatment US in patients who have been treated with foam sclerotherapy only; if the patient has signs/symptoms of a DVT, we will obtain an US at that time. Patients in whom we have performed both ELA and foam sclerotherapy do get US. The same changes seen in post-ELA veins on US are also seen in postfoam sclerotherapy veins (Fig. 17).

After treatment, a patient may notice the treated vein is a firm palpable cord that can be tender. The vein will gradually achieve a brown color that fades to yellow over several

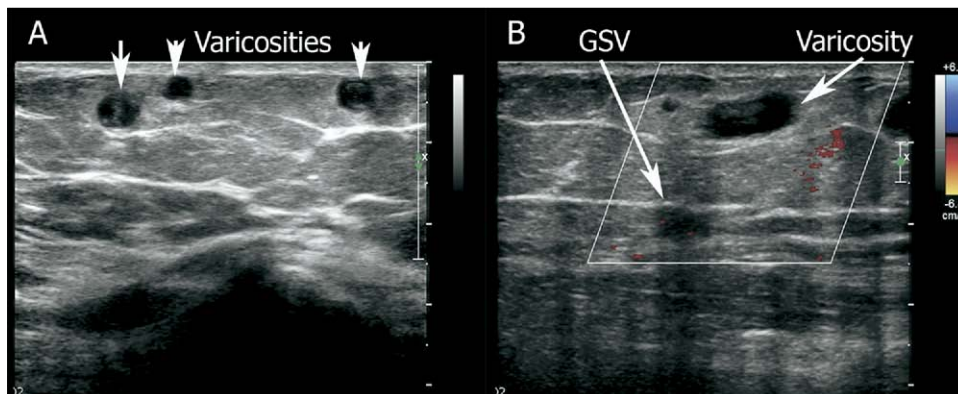


Figure 17 (A) Grayscale US that shows superficial varicosities after treatment with foam sclerosis. The vein has a thickened wall. (B) Color Doppler US that shows no flow in the GSV (treated by ELA) nor in the varicosity (treated by foam sclerosis).

months, and then usually disappears from reasonable view by 6 months. If not adequately discussed during the informed consent session, this progression and healing sequence can lead to patient disappointment.

Uncommonly, a superficial phlebitis will occur in a segment of treated vein; this phlebitis results from heme products under pressure within an inflamed closed segment of the vein. Although this occurrence is usually self-limited, needle thrombectomy with an 18 gauge needle can provide immediate relief. This is sterilely performed by placing the needle into the vein while palpating the tender vein segment. The vein is massaged to extract the heme product from the needle. Even a small amount removed can provide significant relief. This works best when the vein diameter is greater than 5 mm.

We do not use sclerotherapy for telangiectasias unless a feeding reticular vein can be identified by the vein light. Spider telangiectasias associated with a reticular vein respond well to foam sclerosis of the feeding vein. If no associated reticular vein is found, the patient is referred for cutaneous laser treatment.

References

- Evans CJ, Fowkes FG, Ruckley CV, et al: Prevalence of varicose veins and chronic venous insufficiency in men and women in the general population: Edinburgh Vein Study. *J Epidemiol Community Health* 53:149-153, 1999
- Min R, Khilnani N, Golia P: Duplex ultrasound evaluation of lower extremity venous insufficiency. *J Vasc Interv Radiol* 14:1233-1241, 2003
- Labropoulos N, Leon M, Nicolaides AN, et al: Superficial venous insufficiency: Correlation of anatomic extent of reflux with clinical symptoms and signs. *J Vasc Surg* 20:953-958, 1994
- Lees TA, Beard JD, Ridler BM, et al: A survey of the current management of varicose veins by Members of the Vascular Surgical Society. *Ann R Coll Surg Engl* 81:407-417, 1999
- Weiss RA: Surgery for truncal varicose veins, in Weiss RA, Feied FC (eds): *Vein Diagnosis and Treatment: A Comprehensive Approach*. San Francisco, CA, McGraw Hill, 2001, p 195
- Shamiyeh A, Schrenk P, Wayand W: Prospective trial comparing bilateral and unilateral varicose vein surgery. *Langenbeck's Arch Surg* 387:402-405, 2003
- Vaislic C, Clerc PCG, Dan J, et al: Return to work after surgical treatment of varicosities of the lower limb. *Phlebology* 45:159-165, 1992
- Holme JB, Skajaa K, Holme K: Incidence of lesions of the saphenous nerve after partial or complete stripping of the long saphenous vein. *Acta Chir Scand* 156:145-148, 1990
- Jones L, Braithwaite BD, Selwyn D, et al: Neovascularization is the principle cause of varicose vein recurrence: Results of a randomised trial of stripping of the long saphenous vein. *Eur J Vasc Endovasc Surg* 12:442-445, 1996
- Sarin S, Scurr JH, Coleridge Smith PD: Assessment of stripping of the long saphenous vein in the treatment of primary varicose veins. *Br J Surg* 79:889-893, 1992
- Corder AP, Schache DJ, Farquharson SM, et al: Wound infection following high saphenous ligation. A trial comparing two skin closure techniques: subcuticular polyglycolic acid and interrupted monofilament nylon mattress sutures. *J R Coll Surg Edinb.* 36:100-102, 1991
- Rautio T, Ohinmaa A, Perala J, et al: Endovenous obliteration versus conventional stripping in the treatment of primary varicose veins: A randomized controlled trial with comparison of the costs. *J Vasc Surg* 35:958-965, 2002
- Merchant RF, Kistner RL, Kabnick LS: Is there an increased risk for DVT with the VNUS closure procedure? *J Vasc Surg* 38:628, 2003
- Dwerryhouse S, Davies B, Harradine K, et al: Stripping the long saphenous vein reduces the rate of reoperation for recurrent varicose veins: Five-year results of a randomized trial. *J Vasc Surg* 29:589-592, 1999
- Turton EP, Scott DJ, Richards SP, et al: Duplex-derived evidence of reflux after varicose vein surgery: Neoreflux of neovascularisation? *Eur J Vasc Endovasc Surg* (3 VI):230-233, 1999
- Goldman MP: Closure of the greater saphenous vein with endoluminal radiofrequency thermal heating of the vein wall in combination with ambulatory phlebectomy: Preliminary 6-month follow-up. *Dermatol Surg* 26:452-456, 2002
- Weiss RA: Comparison of endovenous radiofrequency versus 810 nm diode laser occlusion of large veins in an animal model. *Dermatol Surg* 28:56-61, 2002.
- Lurie F, Creton D, Eklof B, et al: Prospective randomized study of endovenous radiofrequency obliteration (Closure procedure) versus ligation and stripping in a selected patient population (EVOLVeS Study). *J Vasc Surg* 38:207-214, 2003
- Beale RJ, Mavor AID, Gough MJ: Minimally invasive treatment for varicose veins: A review of endovenous laser treatment and radiofrequency ablation. *Lower Extremity Wounds* 3:188-197, 2004
- Goldman MP, Amiry S: Closure of the greater saphenous vein with endoluminal radiofrequency thermal heating of the vein wall in combination with ambulatory phlebectomy: 50 patients with more than 6-month follow-up. *Dermatol Surg* 28:29-31, 2002
- Fassiadis N, Kianifard B, Holdstock JM, et al: Ultrasound changes at the saphenofemoral junction and in the long saphenous vein during the first year after VNUS closure. *Int Angiol* 21:272-274, 2002
- Merchant RF, DePalma RG, Kabnick LS: Endovascular obliteration of saphenous reflux: A multicenter study. *J Vasc Surg* 35:1190-1196, 2002
- Pichot O, Sessa C, Bosson JL: Duplex imaging analysis of the long saphenous vein reflux: Basis for strategy of endovenous obliteration treatment. *Int Angiol* 21:333-336, 2002
- Sybrandy JE, Wittens CH: Initial experiences in endovenous treatment of saphenous vein reflux. *J Vasc Surg* 36:1207-1212, 2002
- Hingorani A, Ascher E, Markevich N, et al: Deep venous thrombosis after radiofrequency ablation of greater saphenous vein: A word of caution. *J Vasc Surg* 40:500-504, 2004
- Wagner WH, Levin PM, Cossman DV, et al: Early experience with radiofrequency ablation of the greater saphenous vein. *Ann Vasc Surg* 18:42-47, 2004
- Navarro L, Min R, Bone C: Endovenous laser: a new minimally invasive method of treatment for varicose veins—preliminary observations using an 810 nm diode laser. *Dermatol Surg* 27:117-122, 2001
- Min R, Zimmet S, Isaacs MN, et al: Endovenous laser treatment of the incompetent greater saphenous vein. *J Vasc Interv Radiol* 12:1167-1171, 2001
- Gerard J-L, Desgranges P, Becquemen J-P: Peut-in traiter les grandes saphenes variqueuses par laser endoveineux en ambulatoire. *J Maladies Vasculaires* 27:222-225, 2002
- Proebstle T, Lehr HA, Kargl A: Endovenous treatment of the greater saphenous vein with a 940-nm diode laser: Thrombotic occlusion after endoluminal thermal damage by laser-generated steam bubbles. *J Vasc Surg* 35:729-736, 2002
- Min R, Zimmet S, Isaacs MN: Endovenous laser treatment of saphenous vein reflux: Long term results. *J Vasc Interv Radiol* 14:991-996, 2003
- Proebstle T, Gul D, Lehr HA, et al: Infrequent early recanalisation of greater saphenous vein after endovenous laser treatment. *J Vasc Surg* 38:511-516, 2003
- Puggioni A, Kalra M, Carmo M, et al: Endovenous laser therapy and radiofrequency ablation of the great saphenous vein: Analysis of early efficacy and complications. *J Vasc Surg* 42:488-493, 2005
- Proebstle T, Gul D, Kargl A: Endovenous laser treatment of the lesser saphenous vein with a 940-nm diode laser: Early results. *Dermatol Surg* 29:357-361, 2003
- Desmyttere J, Grand C, Wassmer B, et al: Endovenous 980-nm laser treatment of saphenous veins in a series of 500 patients. *J Vasc Surg* 46:1242-1247, 2007

36. Timperman P, Sichelau M, Ryu RK: Greater energy delivery improves treatment success of endovenous laser treatment of the incompetent saphenous veins. *J Vasc Interv Radiol* 15:1061-1063, 2004
37. Chang C, Chu C: Endovenous laser photocoagulation (EVLP) for varicose veins. *Lasers Surg Med* 31:257-262, 2002
38. Sichelau M, Ryu R: Cutaneous thermal injury after endovenous laser ablation of the great saphenous vein. *J Vasc Interv Radiol* 15:865-867, 2004
39. Kabnick L: Outcome of different endovenous laser wavelengths for great saphenous vein ablation. *J Vasc Surg* 43:88-93, 2006
40. Timperman P: Prospective evaluation of higher energy great saphenous vein endovenous laser treatment. *J Vasc Interv Radiol* 16:791-794, 2005
41. Theivacumar NS, Dellgrammaticas D, Beale RJ, et al: Factors influencing the effectiveness of endovenous laser ablation (EVLA) in the treatment of great saphenous vein reflux. *Eur J Vasc Endovasc Surg* 35:119-123, 2008
42. McAusland S: The modern treatment of varicose veins. *Med Press Circular* 201:404-410, 1939
43. Tessari L, Cavezzi A, Frullini A: Preliminary experience with a new sclerosing foam in the treatment of varicose veins. *Dermatol Surg* 27: 58-60, 2001
44. Hamel-Desnos C, Desnos P, Wollmann J-C, et al: Evaluation of the efficacy of polidocanol in the form of foam compared with liquid form in the sclerotherapy of the greater saphenous vein: Initial results. *Dermatol Surg* 29:1170-1175, 2003
45. Yamaki T, Nozaki T, Iwasaka S: Comparative study of duplex-guided foam sclerotherapy and duplex-guided liquid sclerotherapy for the treatment of superficial venous insufficiency. *Dermatol Surg* 30:718-722, 2004
46. Barrett J, Allen B, Ockelford A, et al: Microfoam ultrasound-guided sclerotherapy of varicose veins in 100 legs. *Dermatol Surg* 30:6-12, 2004
47. Frullini A, Cavezzi A: Sclerosing foam in the treatment of varicose veins and telangiectases: History and analysis of safety and complications. *Dermatol Surg* 28:11-15, 2002
48. Cavezzi A, Frullini A, Ricci S, et al: Treatment of varicose veins by foam sclerotherapy: Two clinical series. *Phlebology* 17:13-18, 2002
49. van Ramshorst B, van Bemmelen P, Hoeneveld H, et al: The development of valvular incompetence after deep vein thrombosis: A follow up study with duplex scanning. *J Vasc Surg* 19:1059-1066, 1994