

Needle Aspiration of Breast Cysts

George P. Rosemond, MD, Willis P. Maier, MD, and Thomas J. Brobyn, MD
Philadelphia, Pennsylvania

Material has been introduced to support the use of needle aspiration of dominant breast masses as a diagnostic and therapeutic tool. Experience with approximately 3,000 successful aspirations of simple breast cysts is presented. No evidence of decreased survival was found in patients in whom carcinoma was proved after an unsuccessful aspiration attempt. The technique of needle aspiration of breast masses is included. Routine excision of simple breast cysts is condemned.

The controversy surrounding needle aspiration of simple cysts of the breasts has boiled unabatedly for almost 100 years. It is time that the flame be extinguished by experience and logical consideration of the problem. There is no question that routine excision of simple cysts of the female breast represents needless, unjustified, and meddlesome operation. We strongly believe that aspiration should replace excision of the simple cyst. The purpose of this article is to review the procedure of needle aspiration of breast cysts in terms of its indications, limitations, technique, and results in a large series of patients.

At the time of initial examination of patients seen in our clinic, aspira-

tion attempts are made on dominant breast masses. If the dominant mass is obviously malignant with skin fixation, or the like, needle aspiration is unnecessary and biopsy mandatory. Lesions as small as 1 cm in diameter are suitable for aspiration. We are often pleasantly surprised to find that masses exhibiting several of the characteristics of a malignant lesion yield fluid with aspiration and completely disappear. Besides the immediate relief and gratitude of the patient, many hundreds of hospital days as well as thousands of dollars have been saved using this simple technique. This, in addition to the inherent hazards of general anesthetics and the sparing of needless scars, both in the breasts and in the psyche, helps to illustrate the value of needle aspiration of breast cysts.

Needle aspiration should not be confused with needle biopsy. The use of needle aspiration is for the diagnosis of solid tumors of the breast as well as the treatment of simple cysts, with no attempt being made to obtain tissue for pathologic study. Needle biopsy has been used in an effort to avoid incisional biopsy of lesions in which

adenocarcinoma is suspected. This requires a pathologist experienced in making the diagnosis of carcinoma from small bits of tissue and has not been widely practiced.

Background of Experience

During the years 1940 to 1968, approximately 3,000 breast cysts have been aspirated by members of the Department of Surgery at this medical center. This presentation concerns our experience with this method of dealing with simple cysts of the breast. The incidence of intracystic carcinoma in this series has been minute. There are three known instances of intracystic carcinoma which were discovered following initial aspiration, after which there was a prompt reaccumulation of fluid within several days, biopsy and subsequent mastectomy being required.

Eighty-five percent of the masses were first noted by the patients. Pain and tenderness, in the area of the cyst, were present in one third of the patients. The usual history consisted of a painless, hard mass, accidentally noticed while bathing or dressing. The duration, from the time the patient noted the cyst to the time she was seen by a physician, varied from two hours to several months. Some of the patients noted an increase in the size of the cyst before menstrual periods, with a decrease beginning with the onset of menses. Pain and tenderness,

From the Department of Surgery, Temple University Health Sciences Center, Philadelphia, Pennsylvania. Reprinted from THE JOURNAL OF FAMILY PRACTICE, Volume 1, Numbers 3/4, 1974. Requests for reprints should be addressed to Dr. George P. Rosemond, Department of Surgery, Temple University Health Sciences Center, Philadelphia, Pa. This paper has been adapted with permission of authors and publishers from "Needle Aspiration of Breast Cysts," by Rosemond GP, Maier WP, Brobyn TJ. Surg Gynec Obstet 128:351-354, 1969, and "Differentiation Between the Cystic and Solid Breast Mass by Needle Aspiration by Rosemond GP. Surg Clin N Amer 43:1433-1437, 1963.

when present, similarly corresponded to the menstrual cycle.

The average age of the patients successfully treated by aspiration of breast cysts has been 40 years. The youngest patient was 15 years of age and the oldest 64 years. There is no reason for a person past the menopause to develop breast cysts, unless she is taking exogenous estrogen or has an estrogen-producing tumor. When cystic masses are present in older patients, one should be more suspicious of intracystic carcinoma.

In the patients we have seen, the right and left breasts have been equally affected. Three fourths of the cysts have been found in the upper, outer quadrant of the breast, which is also the commonest site of carcinoma. All quadrants have been involved, and cysts have been successfully aspirated from the retroareolar area.

The cysts were multiple in about ten percent of the patients, with two or more distinct cysts being palpable. As many as five separate cysts have been aspirated in a single breast. The incidence of development of other simple cysts has been approximately 40 percent. Several patients have presented with three to four cysts every six months for many years. In this group, the alternative to aspiration would probably have been bilateral simple mastectomy.

Size has no relationship to malignant change. The smallest aspirated cysts yielded 0.5 cubic cm of fluid and at least one cyst of 125 cubic cm of fluid has been successfully treated with this technique. Most cysts have contained from three to 10 cm in volume and it seems logical to refer to the size of cysts based on the amount of fluid aspirated.¹

The incidence of intracystic cancer in this series was one tenth of one percent. In all of these patients, the mass promptly reappeared within one week. All were successfully operated on and all of them survived five years.

As our experience broadens with the aid offered by mammography, we are employing this valuable adjunct to diagnosis more frequently. We have been impressed with the diagnostic accuracy of the mammogram when typical "salt and pepper" punctate calcifications are demonstrated. Since we are finding more and more carcinomas that are so small they cannot be appreciated as a dominant mass with

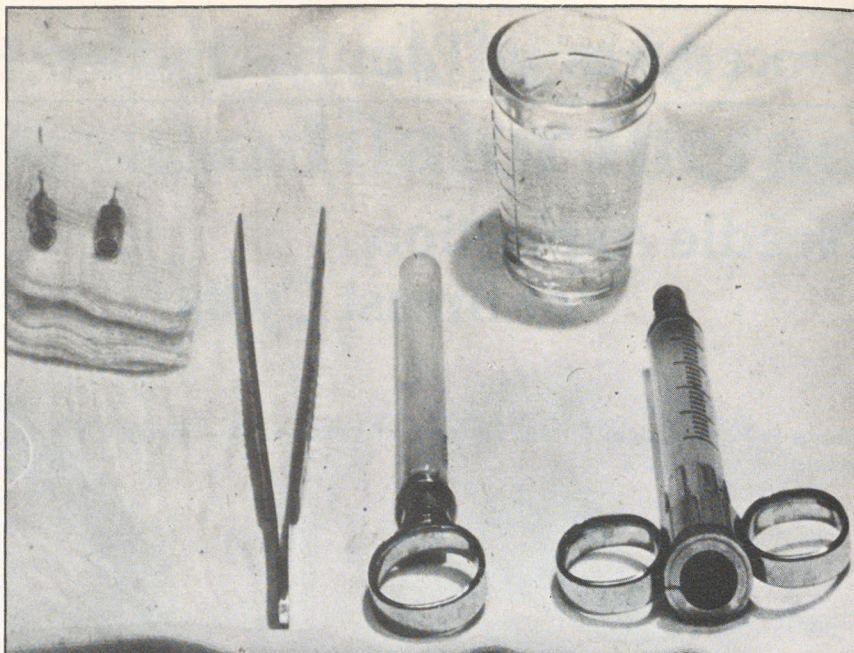


Figure 1. The breast aspiration tray containing a vial of local anesthesia, a 10 cc syringe and 27 and 20-gauge needles.

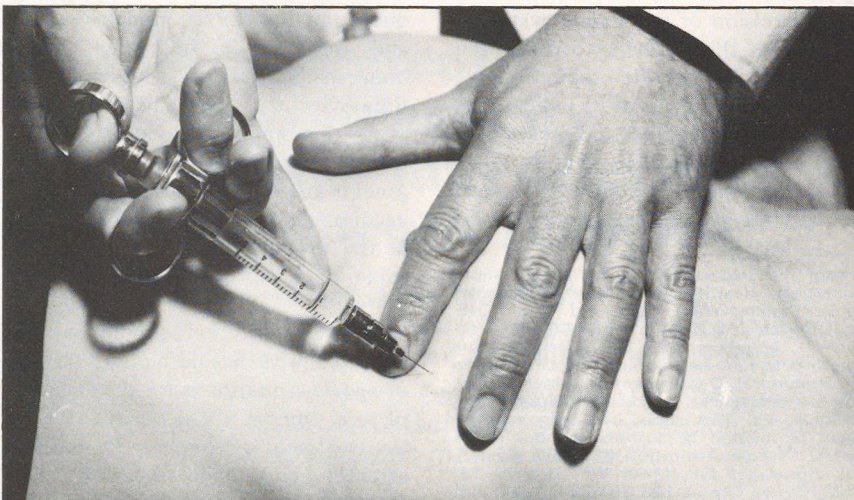


Figure 2. A wheal is raised from the local anesthetic in the skin overlying the breast cyst.

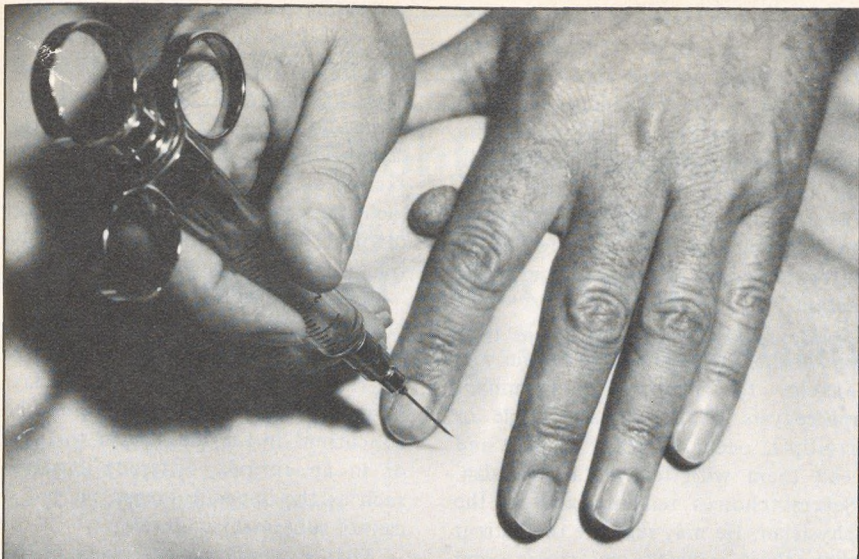

Figure 3. While the cyst is immobilized between the index and middle fingers, puncture into the cyst is accomplished.

palpation, our tendency is to include mammography as part of breast examination.

Technique

The contents of the breast aspiration tray are shown in Figure 1.

After anesthetizing the area over the mass with a wheal from the local anesthetic, a 20-gauge needle, attached to a syringe, is introduced into the mass (Figures 2 and 3). If the mass is cystic, fluid will immediately be returned, often under pressure (Figure 4). Cystic fluid may vary in color from clear to green to dark brown, but it is nearly always thin. The color of the fluid is unimportant, and cytologic study of it is unnecessary. An attempt should be made to aspirate every drop of fluid, as a small residual amount may encourage the cyst to refill. Recurrence is not as common with cysts of less than five milliliters of fluid, when the tension within the small cavity aids in decompression of this area. The incidence of refilling of a previously aspirated cyst has been less than five percent.

If fluid is not aspirated, the lesion is solid and arrangements must be made for biopsy as well as subsequent appropriate therapy. If, however, aspiration results in the complete disappearance of the mass, then the patient is seen for follow-up examination in two weeks and is told that if the cyst returns, surgical removal is indicated. Follow-up examination is indicated at six-month intervals, unless the patient notices a mass before then. On some occasions when a cyst promptly returns, especially if the initial cyst yielded over 15 ml of fluid and the second seems much smaller, reaspiration is performed with success. If the cyst returns to its original size it is still likely to be benign, but to be certain it should be completely removed.

One special circumstance which should be mentioned is when grossly bloody fluid is returned with aspiration. If the blood is from the center of a necrotic tumor, aspiration will not cause disappearance of the mass. If the mass completely disappears, the patient is still regarded with more suspicion because of the possibility of a papilloma or, even more rarely, a small

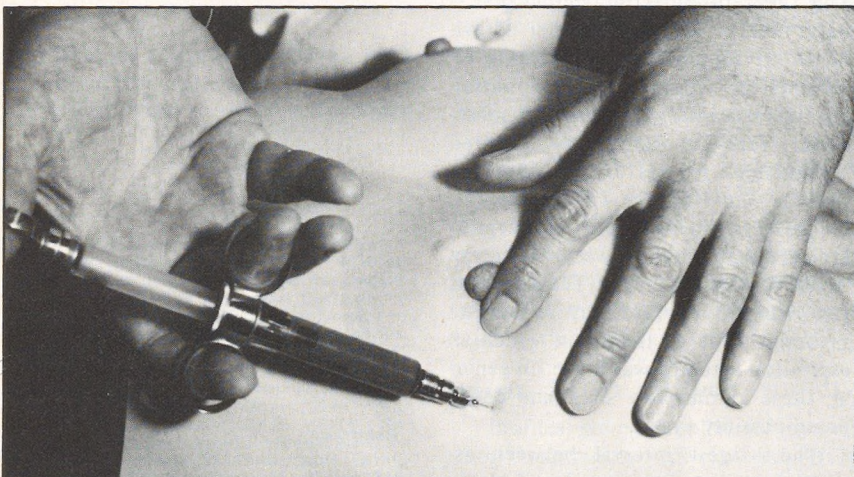

Figure 4. Fluid is aspirated from the cyst with the help of digital pressure.

intracystic carcinoma causing the gross blood. If this is the case, our experience indicates that the cyst promptly refills, usually within three or four days.

The following precautions are important to remember in regard to needle aspiration of breast cysts:

1. Follow-up in two to four weeks is indicated because of the possibility, however slight, of cancer.

2. Reaspiration should not be persisted in, although occasional reaspiration may be indicated if the material appears purulent or recurs in decreasing amounts.

3. The character of the fluid is of no significance insofar as the possibility of cancer is concerned.

4. The presence of a cyst in one area does not rule out cancer in another.

5. The postmenopausal mass must be considered with especial interest.

Discussion

The fact that simple cystic masses cannot with certainty be differentiated from cancer by palpation alone is well accepted. When aspiration is not practiced, the alternative to surgical excision of each cyst is to watch the cysts for a period of time and try to detect changes if they occur. The dangers with this approach should be obvious.

Simple breast cysts usually have an epithelium lining of no more than one cell layer and often completely lack an epithelium lining. After successful aspiration of a cyst, the wall collapses and a small indentation can be felt at the site. This indentation is not palpable within two or three days thereafter as the surrounding tissue moves in to fill the temporary void. Examination of the cystic breast is facilitated by aspiration of the cysts. Masses which cannot be separated from cysts are then readily palpable. We have been able to palpate small carcinomas in the remaining breast, after the obscuring cysts have been aspirated.

During the menstrual years, the physiologic alterations affecting breasts cause extreme cellularity of ductal tissue with fibrous and reten-

tion cysts developing in many women. The fact that cystic changes in the female breast are the most common alteration of the appendages is, therefore, not surprising. This cyclic increase and decrease of ductal epithelium occurs with each menstrual cycle, occasionally interrupted and cleansed by pregnancy and lactation, to resume afterward until menopause ceases the action.

Microcysts are present at one time or another in most women from menarche to menopause. Dominant macrocysts of the breast, single or multiple, occur in many women and lead them with fear to a physician. Several choices remain open to the physician. He may reassure the patient that these masses are cystic, and follow-up examination for a period of time would be desirable to see what, if any, changes occur. Mammography and thermography may be included as adjunctive measures. On the other hand, he may insist on immediate biopsy and removal of the cyst or cysts to rule out adenocarcinoma. In our opinion, the best choice lies with needle aspiration performed as an office procedure. If the cyst completely disappears, he can assure his patient that this was not cancerous and that biopsy is not required. Follow-up examinations are mandatory and the patient is allowed to go home with a considerably improved outlook and to return for re-evaluation in two weeks. She is then seen every six months for routine breast examination.

One objection to needle aspiration has been the fear of spread of malignant cells into the needle tract and into the blood stream and lymphatics. This theoretic objection simply that — only theory, without a shred of evidence to support it. In analyzing 67 patients in whom needle aspiration was unsuccessful and in whom subsequent biopsy of the lesions indicated malignancy, it was found that the five-year survival rate was 89 percent, 60 patients. This result would seem to indicate that no harm was done to the tumor by this technique. The excellent five-year survival rate may reflect the favorable type of lesions in which an aspiration attempt was made. In general, these lesions were small and considered possibly cystic.

The longest interval between aspiration and operation was 34 days. The average delay was 12 days. When

aspiration is unsuccessful, we prefer that definitive operation be delayed no more than two weeks; however, we have no evidence that a somewhat longer delay has affected the survival rate in our series. The needle tract was excised at the time of mastectomy in each case. No instance of implantation of tumor cells was found in the needle tract.

It is our belief that there is no proved relationship between the presence of fibrocystic disease and cancer of the breast. That is not to say, however, that a carcinoma cannot be concurrent in the breast near the cyst or in an entirely different location, such as the opposite breast, or that it cannot subsequently develop.

That a carcinoma can occur in the same or opposite breast, affected by a cystic mass, is not the point being made in the presentation. It is illogical to assume that all cysts should be removed; the odds should be no better than those of discovering a carcinoma with a random biopsy of an apparently normal breast.

Any physician experienced in breast examination can effectively undertake needle aspiration of the breast if he abides by the simple rules set up to avoid errors with its use. This procedure appears to be especially useful to the family physician, who often sees these patients initially. With the issue of the nature of the breast mass then settled, arrangements for referral can be made promptly if necessary.

Reference

1. Rosemond, GP, Burnett WE, Caswell HT, et al: Aspiration of breast cysts as a diagnostic and therapeutic measure. *Arch Surg* 71:223-229, 1955