

# Injuries in Amateur Ice Hockey: A Two-Year Analysis

Richard H. Daffner, MD  
Louisville, Kentucky

A compilation of injuries sustained in an amateur ice hockey program over a two-year period revealed that the majority of those injuries were facial lacerations. The number of injuries increased with the level of players' skill and with the intensity of the games. Youth players who were required to wear head and total face protection had fewer injuries than either the adult league or semi-professional players. Injuries were greatest to the semi-professional players who wore little or no head protection, and no facial protection. Physicians have a duty to urge all hockey players to wear adequate head and face protection to prevent such injuries. Equipment which is currently available is illustrated.

Ice hockey has become increasingly popular in the United States in the past few years. Formerly, it was a sport played only in the colder climates of the United States and Canada, but now it is found in the unwintery regions of the South and Southwest, including Atlanta, Houston, Phoenix, and San Diego. Concomitant with the establishment of professional teams, popular youth and amateur adult leagues have sprung up, in each of these areas. In the Louisville, Kentucky, area the opening of a new ice-skating facility was accompanied by a renewed interest in the sport along with establishment of youth and amateur men's leagues. This report analyzes the injuries incurred at all levels of participation during the 1974-1975 and 1975-1976 seasons.

## Material and Method

There were three levels of participation. Youth hockey included boys and

girls ages 5 to 17. There were 120 participants in the 1974-1975 season and 130 in the 1975-1976 season.

A men's league consisting of players age 17 and older had 35 players during the 1974-1975 season and 40 players during the 1975-1976 season. This men's league met on a year-round basis because of the availability of ice throughout the year.

The Louisville Blades are an adult semi-professional team which played in the Mid-American Hockey League against similar teams from Columbus, Ohio; Cleveland; Indianapolis; St. Louis; and Fort Wayne. The age range was 16 to 40. There were 20 players each season. Several of the Blades participated in the men's league during the spring-summer season. Any injuries incurred by them are included in the appropriate group in which they were participating at the time.

All injuries were recorded by the author, who was team physician for the three programs. They are summarized in Table 1.

All members of the youth hockey program were required to wear the following protective equipment: helmet with mouth guard, shin pads, gloves, elbow pads, and protective cup. Shoulder pads and hockey pants were considered optional. During the

1975-1976 season, an additional requirement mandated the use of full face protection in the form of plexiglass or wire masks which were fitted to the helmets (Figures 1, 2, and 3). Helmets and masks were not required either in the men's league, or for the Blades. Approximately half the players in the men's league, however, did have helmets and many wore mouth guards. Three had full face protection. Only six of the Blades players wore helmets. None had face protection.

## Results

### Youth Hockey

During the 1974-1975 season, only one laceration was sustained. This was on the wrist of a player who was not wearing protective gloves. There were no fractures, dental, ocular, or other serious injuries which would have required physician treatment. These statistics are all the more remarkable when one considers the fact that this was the first year of a youth hockey program in which there were a large number of participants who had neither skated nor played hockey prior to this time.

During the second year, there were two lacerations, both to the chin. These were caused by the player being cut by his own face mask secondary to an improperly secured helmet. In each case, had the player not been wearing a protective face mask, there would have been serious dental injury. There was one fracture of the clavicle in a patient who was checked into the boards from his blind side.

### Men's League

During the 1974-1975 season, there were six lacerations, all facial. Fractures were sustained to a metacarpal by one player and to the ribs by another. There were no dental, ocular, or serious injuries.

During the 1975-1976 season, six

From the Department of Radiology, University of Louisville School of Medicine, Louisville, Kentucky. Requests for reprints should be addressed to Dr. Richard H. Daffner, Department of Radiology, Duke University Medical Center, Durham, NC 27710.



Table 1. Ice Hockey Injury Statistics: 1974-1976

	Youth Hockey		Men's League		Blades	
	1974-1975	1975-1976	1974-1975	1975-1976	1974-1975	1975-1976
Number of Participants	120	130	35	40	20	20
Types of Injury						
Lacerations	1	2	6	6	17	27
Fractures	0	1 clavicle	1 ribs 1 hand	1 zygoma	1 ankle	1 zygoma 1 clavicle
Dental	0	0	0	0	1	0
Ocular	0	0	0	0	0	0
Serious injuries	0	0	0	0	1 knee	0

facial lacerations were encountered. There was one fractured zygoma requiring surgical elevation. There were no dental or ocular injuries.

*Louisville Blades*

During the 1974-1975 season, 17 lacerations were sustained. All of these were to the face or scalp. One of these was to a goaltender who was hit in the face and was cut by his protective mask. There was one fractured lateral malleolus, caused by the player being hit by a slapshot. This required subsequent bone grafting one year later. One patient sustained a broken tooth when hit by a high stick.

The most serious injury was a torn medial meniscus incurred in a clipping-type injury where the player's skate was planted firmly against the side of the goal.

During the 1975-1976 season, 27 lacerations were sustained. All but one of these, to the lower neck, were on the face and scalp. There were two fractures, one clavicle and one zygoma. The zygoma fracture required surgery with reduction and internal fixation. There were no ocular or dental injuries. These results are summarized in Table 1.

**Discussion**

The popularity of ice hockey is tempered by its image as a thoroughly rough-neck sport. Despite the antics of some of the professional teams which foster this image, the game is actually more benign, requiring skill and agility rather than brawn. (The recent exhibition game between the touring Soviet Army team and Montreal Canadiens of

the National Hockey League illustrated this fact beautifully.)

Even if the game were more closely controlled, however, a significant number of injuries, particularly to the face, would occur in inadequately protected players. The puck, a mass of hard rubber three inches in diameter and one inch thick is propelled at speeds approaching 120 miles per hour. Hockey sticks that may be carried too high and the sharpness of the skaters' blades are two other sources of potential injury. Recent articles by Vinger<sup>1</sup> and Horns<sup>2</sup> emphasized the high potential for injury to the face and eye in ice hockey.

The statistics gathered in this study demonstrate an interesting pattern. The injury rate was directly proportional to the level at which the individual played as well as to the extent to which protective equipment was worn. In the youth league, the only facial lacerations were caused by the players' protective masks through improper anchoring by a loose chin strap. During both seasons the author had occasion to witness many episodes of potential facial injury, when players were struck across the mask by a stick or a puck. The masks were very effective in protecting the wearer.

In the men's league, only three players wore full face protection. All the lacerations sustained in both seasons, as well as the zygomatic fracture, would have been prevented by the wearing of a helmet with full face protection.

The large increase in the number of lacerations sustained by the Blades is a corollary to their tempo of play. The

increase during the 1975-1976 season represents more aggressive play (which ultimately resulted in their winning the league championship). As mentioned before, only six of the players wore head protection, and none had full face protection (except for the goaltenders).

The solution to the problem of facial injuries would be to require players to wear helmets and proper face protection. This can be mandated in amateur hockey leagues.

There are currently two types of facial protection available. The first is a wire mask which completely covers the face (Figure 1). It has the advantage of low cost and high impact resistance. On the negative side, however, are the spaces between the bars through which a stick handle, stick blade, or skate blade could penetrate and cause serious injury. In addition, although the spaces for the player to see through are smaller than the thickness of a puck, a puck shot at high speed would no doubt penetrate and could enter that space causing serious ocular injury. A minor disadvantage is the interference with the player's peripheral vision which could be caused by the bars.

A second type of face protection consists of a clear, high-impact, plastic visor which may be combined with a lower face protection (Figures 2 and 3). This has the advantage of total face protection against sticks, skates, and pucks. The main disadvantage of this system is that the plastic visor will become scratched with use and with storage of the helmet. Fogging has not proved to be a problem. Some players






Figure 1. Wire face mask by Cooper.\* The spaces between the bars will prevent a puck from entering. Butt-ends and skate blades could enter, however. This type of helmet-mask combination would have prevented all the facial/scalp injuries recorded in this study.



Figures 2 and 3. Full face protection by CCM\*\* mounted on two different helmet styles. The top part is clear plastic. The company recommends that both parts be worn together although each is a separate unit. This type of facial protection will prevent injuries from sticks, pucks, and skates. Both this type of protective equipment and the wire mask are designed to fit any brand of helmet.

have complained of respiratory restriction by the lower face guard.

Unfortunately, there is a reluctance on the part of professional players, whom most younger hockey players respect, to wear such protection. A common statement made about such protection is that these masks will limit the players' visibility. The author has worn such protective equipment for several years and, while I must agree that there is some restriction in peripheral vision,<sup>1</sup> the net result of this has been a stimulus to scan the field of play frequently and play "heads up."

Vinger has listed the following criteria for an ideal hockey face mask: "(1) [that it] be affixed to an adequate helmet; (2) offer full face protection without interfering with speech, breathing, hearing, visual acuity, or visual field; (3) be inexpensive, durable, and light in weight, yet offer sufficient protection to prevent most possible stick, puck, skate, and contact injuries; and (4) [be] cosmeti-

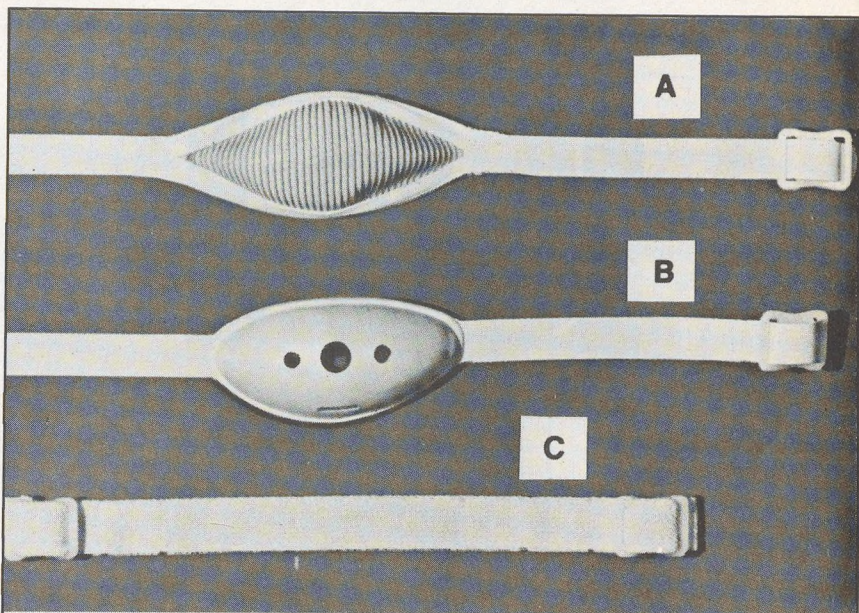


Figure 4. Three types of chin straps available for hockey helmets. The author recommends the cup-type strap which fastens to the chin and gives better anchoring of the helmet.

cally acceptable to the players and fans."<sup>1</sup>

To the above criteria, I would add a fifth specification requiring the use of a football-type chin strap (Figure 4). This will insure adequate anchoring of the helmet to the player's head. Some currently available chin straps are elastic. When the helmet or mask affixed by such a strap is contacted,

motion occurs which could result in the mask itself causing facial injury to the player. This was the mechanism of injury in our two youth players in the 1975-1976 season. Firm anchoring of the helmet by use of a proper strap will prevent such injuries.

#### References

1. Vinger PF: Ocular injuries in hockey. *Arch Ophthalmol* 94:74-76, 1976
2. Horns RC: Blinding hockey injuries. *Minn Med* 59:255-258, 1976

\*Cooper International, Inc, 1707 Ridge Road, Lewiston, NY 14092

\*\*CCM, 2015 Lawrence Ave W, Weston, Ontario M9N 1H6, Canada