
Procedures in Family Practice

Termination of Pregnancy by Menstrual Extraction

William MacMillan Rodney, MD, Martin Quan, MD, and Eugene Felmar, MD
Los Angeles, California

Termination of pregnancy by means of "menstrual extraction" is a useful procedure for family physicians opting to offer this service to their patients. It is an easily performed procedure which, when compared to the presently available avenues for abortion, offers significant advantages in cost, diminished morbidity, and the opportunity for continuity of care by the primary physician. The procedure is successful in properly selected patients 99 percent of the time.

Since the historic Supreme Court decision in *Roe vs Wade* in 1973, which served to repeal or reform nearly all restrictive abortion laws, the demand for legal abortion has steadily increased in the United States.^{1,2} In response to this demand, newer and safer procedures for pregnancy termination have evolved. One of the most important of these is "menstrual extraction."

Menstrual extraction is a procedure that can be readily mastered by the family physician interested in providing early abortion service to his/her patients. The procedure is similar to the placement of an intrauterine device (IUD) in that, without prior cervical dilatation, a soft flexible cannula is inserted into the uterus. However, instead of utilizing the cannula as a conduit for placing an IUD within the uterus, a vacuum source is connected to the cannula to aspirate out the uterine lining.

The concept of menstrual extraction was first alluded to in the literature in 1971.³ Since then, it has gone by numerous names including "menstrual induction," "menstrual planning," "menstrual regulation," "endometrial aspiration," "pre-emptive abortion," "syringe aspiration," and "atraumatic termination of pregnancy."⁴ The purpose of this paper is to describe the procedure as it is performed at the UCLA Family Health Center.

Screening of Candidates

Candidates for menstrual extraction are women desiring termination of pregnancies less than seven weeks in size and duration from their last menstrual period. Complete medical history and physical examination are mandatory to identify any problems that might have bearing on the procedure. In addition, individual counseling is required to determine and explore any ambivalence on the part of the patient regarding the proposed abortion.

From the Division of Family Practice, UCLA School of Medicine, Los Angeles, California. Requests for reprints should be addressed to Dr. Martin Quan, University of California, Los Angeles, Family Health Center, Room BH-134, CHS, 10833 Le Conte Avenue, Los Angeles, CA 90024.

A contraindication to menstrual extraction is the presence of acute pelvic inflammatory disease. The procedure is not recommended for pregnancies more advanced than seven weeks because of the increased risk of incomplete evacuation with its attendant complications.

Pre-Operative Laboratory Studies

Although the risks of the procedure are small, a positive serum pregnancy test is required to avoid subjecting the patient to an unnecessary procedure. A radioreceptor assay which measures active human chorionic gonadotropin in serum is used. Sensitive at seven to eight days after conception, the cost is \$20 (UCLA Clinical Laboratories Memorandum, April 1979). A hematocrit reading may be obtained if anemia precluding surgical intervention is suspected. Rh screening is also performed so that RhoGAM can be administered to the Rh negative woman to prevent sensitization. It should be noted that the amount of RhoGAM necessary for protection is significantly less than the two units recommended at term pregnancy.⁵ In view of the cost of approximately \$50 per unit as well as the potential for serum reactions, a smaller less costly dose, commercially available as MICRhoGAM, is advised.

Materials Required

1. Speculum
2. Single-tooth tenaculum
3. Betadine prep
4. Number 22 spinal needle, 1 percent xylocaine, 12 cc syringe (optional)
5. Flexible Karman cannula, sizes 5, 6, 7 mm (uterine depth measure is on cannula)
6. 50 cc Karman syringe
7. Size "0" uterine curette
8. Oxygen and face mask
9. Scalp vein IV and tubing
10. Dextrose, 5 percent

11. Atropine sulfate
12. Ephedrine sulfate

Procedure

The patient is placed in a dorsal lithotomy position. A bimanual examination is performed to assess the size and position of the uterus. The cervix is visualized via speculum and prepped with betadine. The cervix is then stabilized by grasping its anterior lip with a single-tooth tenaculum. An optional paracervical block can then be performed by injecting, via a Number 22 spinal needle, 5 cc of 1% xylocaine into both uterosacral areas. An alternative is intramuscular premedication with meperidine hydrochloride, hydroxyzine hydrochloride, and atropine sulfate. (The authors use 1 mg/kg meperidine hydrochloride, 0.3-0.5 mg/kg hydroxyzine hydrochloride, and 0.01 mg/kg atropine sulfate.) Experience has shown these premedications to be unnecessary, but, in patients with a low threshold for pain and/or anxiety reactions, the individual physician may wish to use them. In these instances, establishing an intravenous line would be an appropriate back-up safety measure. Prophylactic antibiotics are not routinely used in this clinic.

Using the "no-touch" technique whereby care is taken not to contaminate that portion of the sterile instruments which are to be passed into the uterus,² a flexible Karman cannula is inserted through the cervical os to the uterine fundus (Number 6 Karman cannula is normally used). The cannula is then connected to the Karman syringe and the plunger is pulled back until it locks, creating 50 mmHg negative pressure. The cannula is then rotated 180 degrees repeatedly and the apparatus is moved back and forth within the uterus from the fundus to the cervical canal, taking care not to traverse the internal os. These motions are continued until the uterus is evacuated completely. This is usually signified by "bubbles" appearing in the cannula and a "grating sensation" produced when the cannula comes into contact with the firm muscle of the uterus.⁴ If suction is lost or the cannula obstructs, the apparatus is removed, the syringe emptied, and the procedure repeated until the uterus is "emptied." Less than 30 cc of tissue is obtained 68 percent of the time, while less than 50 cc is obtained 90 percent of the time.⁶ At the conclusion of the procedure, the

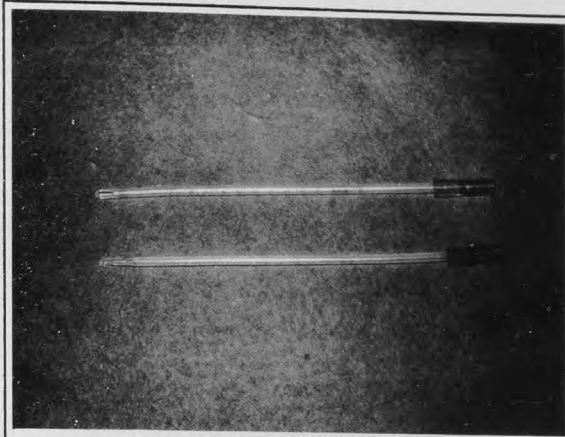


Figure 1. The Karman cannula is a flexible, polyethylene cannula with two whistle-tip apertures. The convex hood overlying each aperture allows it to be used as a "pseudo curette" during the procedure. The cannula is marked off in centimeters to allow sounding of the uterine depth




Figure 2. The Karman syringe has two side-arm catchers which flare out to hold the plunger in a withdrawn position, thereby creating a negative pressure inside the syringe

uterus should be explored with a size "0" uterine curette.

All tissue obtained can be sent to pathology, but the authors currently assess the success of the procedure by: (1) gross inspection of tissue looking for placental villi and fetal parts; (2) follow-up examination at two weeks with emphasis on continuing signs and symptoms of pregnancy; and (3) urine pregnancy test at two weeks after the procedure.

One group has reported elevated serum human chorionic gonadotropin levels in 53 percent of patients two weeks after abortion, thus the serum assay may be positive despite a successful procedure.⁷ The authors' experience has been that the urine agglutination-inhibition test is negative two weeks after a successful menstrual extraction. This experience is supported in the literature.⁸

The patient is observed for 30 to 40 minutes and given MICRhoGAM if indicated. She is then dis-

charged with instructions to refrain from placing anything into her vagina for two weeks and to return if she develops fever, bleeding in excess of normal menses, or severe pain. A return appointment in two weeks is scheduled for follow-up pelvic examination, a repeat pregnancy test, and for contraceptive counseling. A persistent positive pregnancy test after abortion requires work-up to rule out failed abortion, extrauterine pregnancy, pregnancy located in an anomalous uterus, tubal mole, or choriocarcinoma.⁹ If the patient is to start on birth control pills, she may start these on the day of abortion or on the following Sunday (as a memory aid).

Complications

Successful termination of pregnancy is achieved in a reported 99.1 percent of cases, resulting in a failure rate of 0.9 percent.^{6,10}

A major advantage of menstrual extraction is the lack of serious complications. The risks of death of first trimester abortion have been described as statistically similar to the risk of an intramuscular injection of penicillin.¹¹ Immediate side effects occur in a reported six percent of patients.⁶ These side effects include: (1) syncope and vertigo (which responds to leg elevation, oxygen, ephedrine sulfate, or atropine sulfate) in 6 percent of patients, (2) nausea and vomiting in 2 percent, (3) pain in 4.8 percent, and (4) severe hemorrhage in 0.1 percent. Late complications include (1) excessive bleeding requiring curettage in 0.6 to 3.0 percent, (2) endometritis in 0.8 to 2.0 percent, (3) finding of ectopic pregnancy in 0.2 percent, (4) incomplete abortion in 0.6 to 2.5 percent, (5) cervical perforation in less than 0.01 percent, and (6) uterine perforation in less than 0.01 percent.^{6,10,12}

Conclusion

For the family physician opting to offer pregnancy termination to his patients, menstrual ex-

traction is a valuable tool. Requiring an average of 5 to 10 minutes, this outpatient procedure is relatively inexpensive (cost at UCLA is \$100 plus laboratory fees) and can be performed with or without local anesthesia. The procedure is successful in properly selected patients 99 percent of the time and is associated with minimal side effects. In addition, its usage obviates the need for the more expensive and complicated suction abortion with its increased risks and complications.

References

1. Young PE: Abortion and menstrual extraction for the ambulatory patient. *Clin Obstet Gynecol* 17:277, 1974
2. Margolis AJ, Goldsmith S: Early abortion without cervical dilation: Pump or syringe aspiration. *J Reprod* 9:237, 1972
3. Pion RJ, Wabrek AJ, Wilson WB: Innovative methods in prevention of need for abortion. *Clin Obstet Gynecol* 14:1313, 1971
4. Van der Vlugt T, Piotrow PT: Menstrual regulation—what is it? In *Population Reports*, series F, No. 2. Washington, DC, Department of Medical and Public Affairs, the George Washington University Medical Center, 1973; reprinted by Population Information Program, Johns Hopkins University, 1978
5. Bliss RT, Schwartz GA: Minimal risks of Rh sensitization in induced abortions. *J Abdom Surg* 20:35, 1978
6. Hale RW, Kobara TY, Sharma SD, et al: Office termination of pregnancy by menstrual aspiration. *Am J Obstet Gynecol* 134:213, 1979
7. Mandelin M, Rutanen EM, Heikinheimo M: Pregnancy-specific beta-1-glycoprotein and chorionic gonadotropin levels after first trimester abortions. *Obstet Gynecol* 52:3:314, 1978
8. Marrs RP, Kletzky OA, Howard WF, et al: Disappearance of human chorionic gonadotropin and resumption of ovulation following abortion. *Am J Obstet Gynecol* 135:731, 1979
9. Valle RF, Sabbagha RE: Management of first trimester pregnancy termination failures. *Obstet Gynecol* 55:625, 1980
10. Marshall BR, McGeachin SG, Hepler JK, et al: Outpatient termination of early pregnancies using syringe and plastic cannula. *West J Med* 132:186, 1980
11. Cates W Jr: Legal abortion in the United States: Epidemiologic surveillance 1972-1974. *JAMA* 237:452, 1977
12. Brenner WE, Edelman DA: Menstrual regulation: Risks and abuses. *Int J Obstet Gynecol* 15:177, 1977