

---

# Procedures in Family Practice

---

## Suction Curettage

Eugenia C. English, MD  
Seattle, Washington

In the decade after the legalization of elective abortion by a Supreme Court decision in January 1973, suction curettage has been widely used and accepted as a safe outpatient procedure for first-trimester abortion. Evaluation of the patient for feasibility of the procedure requires careful assessment of gestational age and the determination of the absence of an ectopic pregnancy and conditions that might contraindicate local anesthesia. Counseling clarifies the patient's options and ensures her understanding of the implications of abortion so that she can give an informed consent. Suction curettage is performed under local anesthesia using a sterile plastic cannula or curette inserted through a progressively dilated cervix with aspiration of the uterine contents by an electric pump. The procedure is completed by the physician's examination of the aspirate for the presence of placental villi. Postoperative instructions include contraception and monitoring for hemorrhage and infection prior to a return visit in 10 to 14 days. Complications can be reduced by careful selection of patients with appropriate duration of pregnancy, the use of gentle operative technique, antibiotics for prophylaxis of infection, and a continued maintenance of experience and procedural skill by the physician.

An electrical vacuum aspiration technique for emptying the pregnant uterus was first described in 1958.<sup>1</sup> This technique was later reported as an outpatient procedure performed without anesthesia to obtain endometrial tissue for histologic

examination, being equally effective as sharp curettage under general anesthesia.<sup>2-6</sup> Since then, suction curettage has been widely evaluated and accepted, particularly for the elective termination of pregnancy in the first trimester.<sup>7-14</sup>

---

From the Department of Family Medicine, School of Medicine, University of Washington, Seattle, Washington. Requests for reprints should be addressed to Dr. Eugenia C. English, Department of Family Medicine, School of Medicine, University of Washington, RF-30, Seattle, WA 98195.

### Advantages

As an outpatient procedure performed with a paracervical block, suction curettage obviates

hospitalization and operating room costs. Paracervical anesthesia is preferred in abortion procedures because it is associated with a lower rate of cervical injury, uterine perforation, and hemorrhage than abortion performed under general anesthesia.<sup>13,15</sup> The procedure is rapid and creates a minimal disruption of the patient's normal activities, and little or no premedication is required. The technique involves less dilatation of the cervix than is required for surgical curettage, particularly in early pregnancy.

The plastic cannula or curette used is less traumatic than a sharp metal curette and the suction is of sufficient force so that the tip of the cannula or curette need not come into direct contact with the entire surface of the uterine cavity. The placenta is separated by aspiration without trauma to deeper tissues, avoiding potential subsequent complications of traumatic amenorrhea and intrauterine adhesions. The quick evacuation of the uterine cavity causes appreciably less uterine blood loss than when sharp curettage is employed under general anesthesia. The amount of blood lost can be measured directly, since all aspirated material enters the vacuum bottle.

### Disadvantages

It is important to use a cannula of a size appropriate for the duration of pregnancy. Since the quantity of aspirated tissue increases with gestation,<sup>16</sup> an underestimation of gestational age will result in the use of too small a cannula, which can be blocked by fetoplacental tissue. Changing to a larger cannula might necessitate further use of dilators with additional manipulation. The use of a cannula that is too large can possibly result in subsequent cervical incompetence.<sup>17</sup> When microscopic diagnosis is required, distortion of the histologic preparation may result from vacuum pressure. The effect of this on diagnosis has not been found to be of significance, however.<sup>4-6</sup>

### Contraindications

When the patient is extremely apprehensive, local anesthesia may be inadvisable. Also, docu-

mented prior reaction to local anesthetic agents precludes their usage. The presence of an ectopic pregnancy is an absolute contraindication. Musculoskeletal limitations, abnormalities of the genital tract, or palpable pelvic masses indicate a need for general anesthesia. Coexisting systemic illness and coagulopathies require hospitalization for abortion. In general, prior cesarean section, myomectomy, or adnexal surgery does not affect the procedure, and controlled diabetes, epilepsy, and compensated heart disease are not contraindications to an outpatient suction curettage.

### Materials

For positioning the patient, a gynecologic table with obstetrical stirrups is required. A Mayo stand and a mobile light are helpful. A source of vacuum is essential to effect aspiration. For abortion, an electrical pump is required to generate the needed 60 to 70 torr vacuum. Figure 1 shows the aspirate container connected in tandem to the backup container, which is directly connected to the pump.\* For diagnostic endometrial sampling, a modified 50- to 60-mL syringe can be used to produce suction.

Instruments included in the sterile procedure tray are shown in Figure 2: a bivalve vaginal speculum, ring forceps, three-fingered glass syringe with plunger, single-tooth tenaculum, malleable uterine sound, tapered cervical dilators, and a small sharp curette. A cannula adaptor to permit a break in the vacuum is optional.

Plastic suction cannulas (flexible or rigid) shown in Figure 3 are available in several diameters. The flexible cannula has two apertures (Karman-type). A cannula with an external diameter of 4 to 6 mm is used for the termination of early pregnancy, endometrial sampling, and menstrual regulation. The rigid cannula is curved and has an elliptical aperture. In general, a 6-mm cannula is sufficient for a 6- to 8-week gestation, while each millimeter of external diameter roughly corresponds to the number of gestational weeks. In the more advanced 10- to 12-week gestation, it may be necessary to use up to a 12-mm cannula to facilitate the passage of larger placental and fetal parts.

\*Model VC-V, Berkeley Bioengineering, San Leandro, California



Figure 1. Vacuum pump for suction curettage showing a backup bottle connected to the aspirate bottle with tubing for the cannula

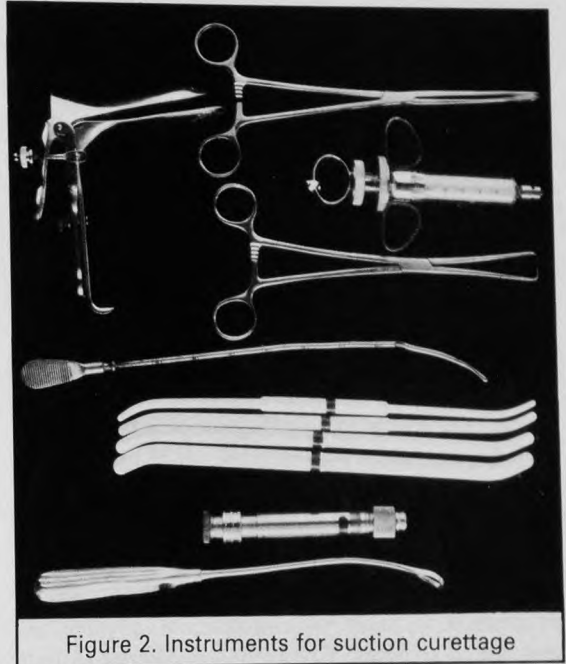


Figure 2. Instruments for suction curettage

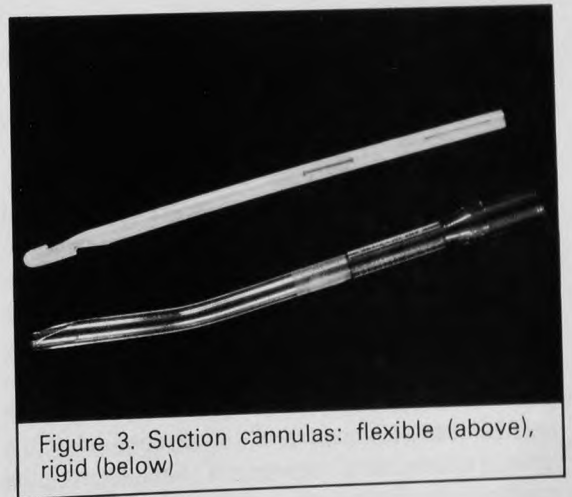


Figure 3. Suction cannulas: flexible (above), rigid (below)

Other necessary materials used during the procedure include sterile drapes, povidone-iodine solution, sterile cotton balls for vaginal and cervical cleansing, a 3.5-in 22-gauge spinal needle for the paracervical block, and 1 percent lidocaine hydrochloride or 0.25 percent bupivacaine hydrochloride, both without epinephrine.

As with other procedures involving local anesthesia, the following emergency equipment should be readily available: low-pressure suction device to aspirate oropharyngeal secretions, an airway and a source of oxygen, a face mask with a positive pressure ventilation bag, intravenous fluid infusion equipment, parenteral pressor amines for hypotension, and diazepam for seizure. For possible uterine atony parenteral ergonovine maleate or oxytocin should be included.

### Evaluation of the Patient

It is essential to establish the presence of pregnancy by testing a first-morning specimen of urine. If positive, the probable duration is determined as closely as possible from the history and a pelvic examination correlating uterine size with the weeks from the last menstrual period. This bimanual examination takes into consideration the influ-

ence of parity, the tone and thickness of the abdominal wall, and the position of the uterus. Exclusion of an ectopic pregnancy is mandatory before performing suction curettage.

Once pregnancy and its duration are established, other aspects of importance relate to the feasibility of local anesthesia and to other possible coexisting diseases, both local and general, that may influence a decision for suction curettage. Pelvic inflammatory disease, if present, requires immediate attention. Cervical stenosis or uterine anomaly may have technical implications and are contraindications to an office procedure. Laboratory tests necessary prior to the procedure include the determination of the hematocrit, blood type, Rhesus factor, and a cervical culture for gonorrhea.

In addition to the medical aspects of pregnancy, evaluation is made of concomitant psychologic and social stresses. Counseling is offered to help the patient make the choice between continuation and termination of the pregnancy. If an abortion is elected, the procedure of suction curettage is discussed in detail.

### Preparation of the Patient

An informed consent is an essential prerequisite for an abortion. Before the patient consents, the physician ensures that she understands the procedure. Risks and alternatives are discussed and medication both before and during the procedure should be planned. Some of the anxiety of the apprehensive patient can be alleviated by emphasizing the transient nature of the discomfort at the time of dilatation of the internal os and likening the contraction of the uterus as it empties to that of menstrual cramps. For the anxious patient, 5 to 10 mg of diazepam can be given orally the evening before or by slow intravenous injection immediately before the procedure. Other useful forms of premedication for anxiety are hydroxyzine hydrochloride, 25 mg orally, or promethazine hydrochloride, 25 mg by intramuscular injection.<sup>7</sup> Not uncommonly, patients opt to have no premedication. Progressive relaxation and trance induction can also be used successfully in preparation for the procedure.

If preferred, prior cervical dilatation can be ac-

complished by introducing a laminaria the day before the procedure. However, this prolongs the discomfort for the patient and may be associated with an increased risk of infection. At present, the use of ergonovine maleate, 0.2 mg given orally at the beginning of the procedure, for prophylaxis of uterine atony is open to evaluation. Prophylaxis against infection is widely used following reports of a decreased infection rate with the use of tetracycline in a dose of 1.5 g 2 hours before the procedure and 0.5 g every 6 hours following for four days.<sup>14</sup> Ideally, the cervical culture for gonorrhea should be obtained 2 to 3 days in advance for results to be known before the procedure. In practice, such prior information may not be available; therefore, the loading dose of tetracycline was designed to treat possible gonorrhea.

### Procedure

An atmosphere of empathetic concern for the patient is generated. She is informed that the estimated length of the procedure is 15 to 20 minutes and that the actual suction time is approximately 3 to 5 minutes. The patient is then given a demonstration of the noise of the suction machine when it is turned on so that she can identify its use during aspiration. She is reassured that she should not be reluctant to communicate with the physician during the procedure.

Vital signs are obtained. With the patient in the lithotomy position, the perineum is cleansed with pHisoHex. The vaginal speculum is positioned and sterile drapes are placed. The vaginal and cervical walls are cleaned by squirting povidone-iodine solution through the speculum and wiping with cotton balls.

Observing a sterile "no-touch" technique, approximately 1 mL of 1 percent lidocaine or 0.25 percent bupivacaine is infiltrated into the anterior lip of the cervix. An interval of 2 to 3 minutes ensures local anesthesia. The single-toothed tenaculum is next applied transversely at the infiltration site and used for gentle countertraction and lateral movement of the cervix. The paracervical block is made using 3 to 6 mL of local anesthetic injected at 3, 5, 7 and 9 o'clock submucosally into the vaginal wall, which is reflected around the cervix. The degree of anesthesia is not significantly in-

creased by more local anesthetic, and a larger dose increases a likelihood of such adverse side effects as vertigo, paresthesia, muscle irritability, hypotension, and seizure. Multiple site injection minimizes systemic effects.

Following another brief interval of 2 to 3 minutes for nerve blockade to be effected, the uterine sound is introduced. This procedure is performed with gentle care to prevent creating a false passage or perforation of the uterus. The length of the cervical canal and the depth of the uterine cavity are noted. Progressive dilatation of the cervix is then achieved by slowly introducing the tip of the smallest dilator through the cervical canal and exerting gentle pressure while using the tenaculum for countertraction. A decrease in resistance indicates passage through the internal os, usually at 3 cm or less. The cervix is progressively dilated using both ends of the dilators until the internal os is adequately dilated to allow free passage of the cannula. The latter is then introduced to the fundus and connected by tubing to the suction machine. When a pressure of 40 to 50 torr is generated, the cannula is rotated 360° in situ. Commonly, the amniotic sac and fluid contents can be seen to pass through the plastic tubing into the aspirate bottle. The cannula is then gently moved to and fro in its long axis while serially rotated within the uterus to complete aspiration. A rough gritty sensation can be felt in all quadrants of the uterine wall as the uterus empties and becomes noticeably contracted. At this point, the aspirate consists only of frothy blood. Use of the sharp curette is optional. In general, although it is not necessary to use the curette in an early gestation, its use is advisable to check for complete evacuation in the more advanced 10- to 12-week gestation. If the sharp curette is used, the cannula is reintroduced for a final aspiration. If blood loss is excessive or uterine atony is present, 0.2 mg of ergonovine maleate or 10 units of oxytocin can be given intramuscularly.

The procedure is not considered complete until the aspirate is examined by the physician for the amount and the presence of placental tissue. The villi of the early placenta can be easily identified when the aspirated fragments are suspended in saline in a shallow glass dish. A nearly intact sac is often seen in the 6- to 8-week abortion. Fetal matter is rarely identified before a 9-week gestation. Hydatidiform villi can often be detected macro-

scopically; however, in known high-risk patients, a pathology evaluation will confirm its absence or presence and that of choriocarcinoma.<sup>18</sup> The amount of aspirated tissue has been used as an indication of completeness of the suction curettage<sup>16,19</sup> and should be consistent with the gestational age. At 6 weeks, the aspirate volume is at least 20 mL, at 7 to 8 weeks it is approximately 60 mL, and at 9 to 10 weeks an average volume is 80 mL. Scanty aspirate may be compatible with a terminated early pregnancy when villi are present; however, the abortion may be incomplete and careful follow-up would be needed in 1 to 2 weeks. If villi are absent, a repeat suction curettage can be performed to resolve the question of an early pregnancy, a failed abortion, incomplete abortion, or an ectopic pregnancy. Persistent absence of villi on the repeat curettage indicates a need for a repeat pregnancy test and careful re-evaluation for ectopic pregnancy.

Vital signs are recorded at the end of the procedure. If examination of the aspirate is confirmatory, the patient is informed that she is no longer pregnant to indicate that abortion has been achieved. She is told that abortion effects temporary hormonal changes that may have emotional expression such as a mild depression comparable to "baby blues." She is then instructed to take her oral temperature twice daily for the next four to five days. A temperature above 38° C requires a report to the clinic. For prophylaxis against infection, tetracycline, 500 mg every 6 hours, is prescribed for the next four days. An explanation is given of the pattern of bleeding to be expected. She is asked not to take tub baths or to use tampons or douches and to refrain from sexual intercourse during the next seven days. An appointment is made for a return visit in 10 to 14 days. The importance of this visit is stressed not only for a check of return to normality, but also as an opportunity for a diaphragm fit or insertion of an intrauterine device. If oral contraception is elected, this can be started within 24 hours of the abortion.

If the patient is Rhesus negative, an intramuscular injection of Rh<sub>0</sub>(D)-immune globulin, or MICRhOGAM, is given unless the father is known to be negative also.

At 30 and 60 minutes after the procedure, vital signs are repeated and uterine bleeding is checked. Depending on the degree of sedation from premedication, patients are then ready to leave.

## Complications

The overall morbidity rate for suction curettage abortion ranges from 7 to 22 per 1,000 procedures.<sup>7,12,14,20</sup> For the most part, these complications relate to difficulties in the diagnosis of uterine pregnancy, in the estimation of its duration, and in the procedural skill of the physician.

If the pregnancy is early and in doubt, the use of a less-sensitive urine pregnancy assay is preferable, since a false-negative test only indicates the necessity for subsequent retesting. Delaying the procedure until the urine pregnancy test is positive can avoid the complications often associated with cervical dilatation and evacuation of a non-pregnant uterus. Complications of suction curettage are greater when performed at a gestational age under 6 weeks or later than 10 weeks.<sup>12,19-24</sup> Thus, the optimal time for an uncomplicated suction curettage abortion falls between 6 and 10 weeks. The estimation of gestational age is of sufficient importance that, if uncertainty exists, consultation with another physician would be desirable. When pregnancy approaches the 12-week period, ultrasound can help determine the feasibility of an office suction curettage abortion. After 12 weeks' gestation, in general, the patient should be referred to a specialist.

The physician's technical skill is of importance in avoiding such complications as cervical laceration, perforation of the uterus, incomplete abortion, failed abortion, postabortal hemorrhage, and infection. Sufficient ongoing experience with the procedure is related to maintenance of skill. Lower complication rates have been demonstrated in physicians who performed at least 100 abortions over a two-year period,<sup>12</sup> suggesting that both experience and proficiency contribute to an improved outcome.

## Summary

Suction curettage is a safe and inexpensive procedure for the termination of first-trimester pregnancy. A patient's request for an abortion requires both an interpersonal and a procedural skill that can be provided by a family physician. Optimal outcome is assured by combining individual consideration for the patient with maintenance of experience and proficiency in the procedure.

## References

1. Wu YT, Wu HC: Suction in artificial abortion. *Chin J Obstet Gynecol* 6:447, 1958
2. Jensen JA, Jensen JG: Abrasio mucosae uteri e aspiratione. Forelobig meddelelse. *Ugeskr Laegen* 130: 2124, 1968
3. Jensen JG: Vacuum curettage. Outpatient curettage without anesthesia. A report of 350 cases. *Dan Med Bull* 17: 199, 1970
4. Haack-Sorensen PE, Starklint H, Aronson A, et al: Diagnostic Vabra (aspiration curettage). *Dan Med Bull* 26:1, 1979
5. Goldberg GL, Tsalacopoulos G, Davey DA: A comparison of endometrial sampling with the Accurette and Vabra aspirator and uterine curettage. *S Afr Med J* 61:114, 1982
6. Lubbers JA: Diagnostic suction curettage without anesthesia. An investigation into the practical usefulness of the Vabra aspirator. *Acta Obstet Gynecol Scand (suppl)* 62:1, 1977
7. Nathanson BM: Ambulatory abortion: Experience with 26,000 cases (July 1, 1970 to Aug 1, 1971). *N Engl J Med* 286:403, 1972
8. Abortion surveillance, 1975. Atlanta, Center for Disease Control, 1977
9. Tietze C, Lewit S: Early medical complications of legal abortion. Joint program for the study of abortion (JPSA). *Stud Fam Plann* 3:97, 1972
10. Miller ER, Wood JL, Andolsek L, et al: First trimester abortion by vacuum aspiration: Interphysician variability. *Int J Gynaecol Obstet* 16:144, 1978
11. Strausz IK, Schulman H: 500 outpatient abortions performed under local anesthesia. *Obstet Gynecol* 38:199, 1971
12. Bozorgi N: Statistical analysis of first-trimester pregnancy terminations in an ambulatory surgical center. *Am J Obstet Gynecol* 127:763, 1977
13. Grimes DA, Schulz KF, Cates W, et al: Local versus general anesthesia: Which is safer for performing suction curettage abortions? *Am J Obstet Gynecol* 135:1035, 1979
14. Hodgson JE: Major complications of 20,248 consecutive first trimester abortions: Problems of fragmented care. *Adv Plann Parenthood* 9:52, 1975
15. Cullen BF, Margolis AJ, Eger EI: Part 2: The effects of anesthesia and pulmonary ventilation on blood loss during elective therapeutic abortion. *Anesthesiology* 32:108, 1970
16. Rasmussen P: Amount of tissue evacuated by vacuum aspiration in therapeutic abortions. *Acta Obstet Gynecol Scand* 60:475, 1981
17. Johnstone FD: Cervical diameter after suction termination of pregnancy. *Br Med J* 1:68, 1976
18. De Cherney AH, Silverman BB, Mastroianni L Jr: Abortion and unrecognized trophoblastic disease. *N Engl J Med* 285:407, 1971
19. Burnhill MS, Armstead JW: Reducing the morbidity of vacuum aspiration abortion. *Int J Gynaecol Obstet* 16: 204, 1978
20. Cheng M, Andolsek L, Ng A, et al: Complications following induced abortion by vacuum aspiration: Patient characteristics and procedures. *Stud Fam Plann* 8(5):125, 1977
21. Moberg P, Sjoberg B, Wiquist N: The hazards of vacuum aspiration in late first-trimester abortions. *Acta Obstet Gynecol Scand* 54:113, 1975
22. Hodgson JE, Major B, Portmann K, et al: Prophylactic use of tetracycline for first trimester abortion. *Obstet Gynecol* 45:574, 1975
23. Hale RW, Kobara TY, Sharma SD, et al (eds): Office termination of pregnancy by "menstrual aspiration." *Trans Pac Coast Obstet Gynecol Soc* 46:117, 1979
24. Grimes DA, Schulz KF, Cates W Jr, et al: Proceedings of the Western Regional Conference on Abortion. Denver, National Abortion Federation, 1976