

# Systemic Reaction to Pyrimethamine-Sulfadoxine

Robert L. Murphy, MD, and John P. Phair, MD  
Chicago, Illinois

A combination of pyrimethamine and sulfadoxine (Fansidar) is increasingly prescribed as malaria prophylaxis for travelers to areas of the world with chloroquine-resistant *Plasmodium falciparum*. An unusually severe reaction occurred in an individual receiving this long-acting combination agent.

## CASE REPORT

An active 75-year-old, white, nonsmoking woman in good general health received immunizations for yellow fever, poliomyelitis, and rabies, and immune serum globulin, as well as weekly chloroquine and pyrimethamine-sulfadoxine prophylaxis beginning January 30, 1983, in preparation for a trip to Madagascar, the Seychelles, and La Reunion. She arrived in Madagascar February 8. On February 14, she began a one-week course of tetracycline for a nonspecific eye infection, which subsided, but fatigue, malaise, anorexia, and nonproductive cough developed and persisted. The patient returned to the United States on February 23. Three days later she developed evening fevers to 101.4°F. A transient pruritic, vesicular rash appeared on both lower extremities. On March 6 she again took, as prescribed, her antimalarial drugs and noted fever with shaking chills. She was admitted to Northwestern Memorial Hospital on March 7.

On admission her temperature was 98.2°F, pulse 144 beats/min, blood pressure 150/170 mmHg, and respiration 18/min. She appeared fatigued. A vesicular rash was present on the anterior aspect of the knees and thighs. Bibasilar inspiratory crackles were heard in the lung fields. A grade 2/6 systolic murmur was heard over the precordium. There was no hepatosplenomegaly. Rectal examination revealed Hemoccult-negative stool.

An extensive evaluation was undertaken. The white blood count was  $7.6 \times 10^3/\mu\text{L}$  (61 percent polymorphonuclear cells, 8 percent band forms, 7 percent eosinophils), hemoglobin 13.0 g/dL, hematocrit 38.8 percent, platelets  $228 \times 10^3/\mu\text{L}$ . SGOT was 53 U/mL, alkaline phosphatase 364 U/dL, lactic dehydrogenase 178 U/dL, albumin 3.1 g/dL. Electrocardiogram demonstrated a supraventricular tachycardia, which reverted to normal sinus rhythm spontaneously. A fine reticulonodular pattern was noted on the chest film. Three sputa induced by ultrasonic nebulization were negative for acid-fast bacteria but grew moderate *Candida* species. Three urine cultures for bacteria, mycobacteria, and fungi were negative. Blood cultures were negative, as were thick blood smears, for malaria. A stool examination for ova and parasites and VDRL were negative. Tuberculin skin test was non-reactive and filarial titers were negative. Complement fixation and double immune diffusion tests for histoplasmosis, blastomycosis, and coccidiomycosis were negative. Titers for cytomegalovirus, influenza A, influenza B, adenovirus, *Mycoplasma pneumoniae*, parainfluenza 1, 2 and 3, and respiratory syncytial and varicella zoster virus were negative. Convalescent sera demonstrated no increase in titer.

An echocardiogram demonstrated mitral annular calcification and a mild to moderate pericardial effusion. Pulmonary function tests revealed a mild obstructive deficit, and the diffusion capacity was 70 percent. Levels of angiotensin-converting enzyme were within normal limits.

The hospital course was remarkable for the patient's rise in liver enzymes and mild eosinophilia as well as persistent fatigue and malaise. A low-grade fever resolved over a one-week period (Figure 1).

The bone marrow and liver were biopsied and cultured. Cultures were negative for mycobacterium. Histopathologically, both specimens demonstrated non-caseating granulomas. The description of the liver noted the granulomas to be "well formed and consist of plump epithelioid cells, giant cells and chronic inflammatory cells. Numerous eosinophils are also seen. These granulomas are randomly scattered. The portal areas are unremarkable. Special stains for acid fast

From the Section of Infectious Disease, Department of Medicine, Northwestern University Medical School, Chicago, Illinois. Requests for reprints should be addressed to Dr. Robert L. Murphy, Department of Medicine, Northwestern University Medical School, 303 East Chicago Avenue, Chicago, IL 60611.

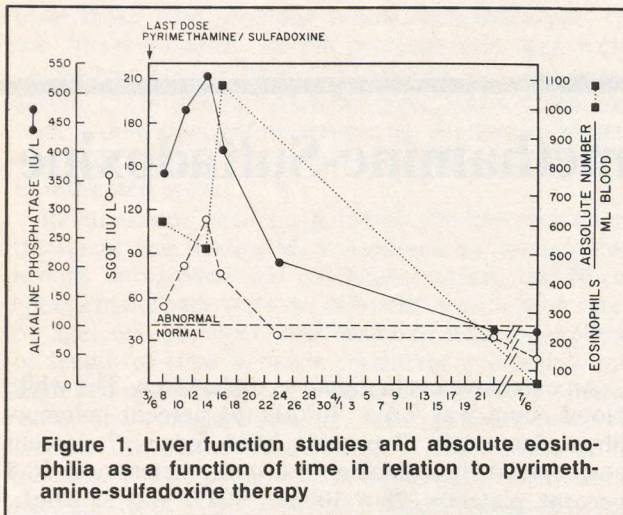


Figure 1. Liver function studies and absolute eosinophilia as a function of time in relation to pyrimethamine-sulfadoxine therapy

bacilli and fungi fail to demonstrate microorganisms.”

The patient was discharged when her temperature resolved and was followed closely as an outpatient. Over a period of one month her strength gradually returned and the liver function tests normalized. The chest roentgenogram showed improvement in the interstitial pattern. She had no further cardiac problems. Eleven months later she was active and in good health.

## COMMENT

The initial differential diagnosis in this patient included mycobacterial disease, malaria, disseminated fungus, sarcoidosis, and drug reaction. Other less common entities, such as paragonimiasis and tropical eosinophilia, were also considered. Because of the extensive negative evaluation, mycobacterial, fungal, malarial, and filarial causes were considered as unlikely reasons for her fever. The normal angiotensin-converting enzyme and rapid spontaneous resolution of the interstitial infiltrate spoke against the diagnosis of sarcoidosis. Drug fever was thus considered the most likely cause of this illness. The patient had begun taking chloroquine and pyrimethamine-sulfadoxine January 30, 1983. Her last weekly dose was the day before the hospital admission date of March 7, 1983.

The timing of her symptoms, as well as the eosinophilia and hepatitis, incriminate her malarial prophylaxis as the most probable cause. The histology of the liver biopsy demonstrated scattered eosinophils surrounding the granulomas, which is more suggestive of a drug reaction than an infectious process. Granulomatous hepatitis is an unusual side effect of chloroquine,<sup>1</sup> and to date pyrimethamine-sulfadoxine has not been reported to cause this reaction. However, sulfadoxine is a long-acting sulfonamide with a mean

half-life of 169 hours, and sulfonamides have been incriminated as a cause of granulomatous hepatitis.<sup>1-4</sup> A nearly identical case involving fever, skin rash, granulomatous reaction in the liver, and interstitial pneumonitis has been reported in a 24-year-old patient within one week following a 2-g dose of sulfadimethoxine.<sup>5</sup> In two other instances, granulomatous reactions were documented three weeks and three years after therapy with salicylazosulfapyridine for ulcerative colitis.<sup>6,7</sup> This component of the combination is thought to be the most probable cause in this case. Of the 1.5 million individuals who have taken the combination agent, only 137 patients with adverse effects have been analyzed by the Hoffman-LaRoche drug-monitoring group.<sup>6-9</sup> The great majority of adverse effects were mild and transient. Fewer than one dozen patients have suffered severe reactions. A total of 24 patients have had a reaction involving the liver and biliary system. The incidence of sulfonamide reactions in the general population is unknown. In Denmark during the decade 1968 to 1978, there were 572 cases of hepatotoxicity reported to the Danish Board of Adverse Reactions to Drugs (6 percent of all reported adverse reactions).<sup>10</sup>

This patient demonstrated granulomatous hepatitis, eosinophilia, interstitial pulmonary infiltrates, pericardial effusions, fevers, chills, and general malaise. She presented a diagnostic and therapeutic dilemma early in the course of her illness. Primary care physicians should be aware of the potential side effects of pyrimethamine and sulfadoxine when given to third world travelers going to malarious areas of the world where chloroquine-resistant *P falciparum* is a risk.

## References

1. Fauci A: Granulomatous hepatitis. *Liver* 1976; 5:609-621
2. Guckian JC: Granulomatous hepatitis. *Ann Intern Med* 1966; 65:1081-1100
3. Klatskin G: Hepatic granulomatous: Problems in interpretation. *Mt. Sinai J Med* 1977; 44:798-812
4. More RH, McMillan GC, Duff GL: The pathology of sulfonamide allergy in man. *Am J Pathol* 1946; 22:703
5. Espiritu CR, Kim TS, Levine RA: Granulomatous hepatitis associated with sulfadimethoxine hypersensitivity. *JAMA* 1967; 202(10):161-164
6. Namias A, Bhalotra R, Donowitz M: Reversible sulfasalazine-induced granulomatous hepatitis. *J Clin Gastroenterol* 1981; 3:193-198
7. Callen JP, Soderstrom RM: Granulomatous hepatitis associated with salicylazosulfapyridine therapy. *South Med J* 1978; 71:1159-1160
8. Koch-Weser J, Hodel C, Leimer R, Styk S: Adverse reactions to pyrimethamine/sulfadoxine. *Lancet* 1982; 2:1459
9. Olsen V, Loft S, Christensen K: Serious reactions during malarial prophylaxis with pyrimethamine/sulfadoxine. *Lancet* 1982; 2:994
10. Dossing M, Andreasen PB: Drug-induced liver disease in Denmark. *Scand J Gastroenterol* 1982; 17(2):205-211