

## Asphyxia Neonatorum

Raul C. Banagale, MD, and Steven M. Donn, MD  
Ann Arbor, Michigan

*Various biochemical and structural changes affecting the newborn's well-being develop as a result of perinatal asphyxia. Central nervous system abnormalities are frequent complications with high mortality and morbidity. Cardiac compromise may lead to dysrhythmias and cardiogenic shock. Coagulopathy in the form of disseminated intravascular coagulation or massive pulmonary hemorrhage are potentially lethal complications. Necrotizing enterocolitis, acute renal failure, and endocrine problems affecting fluid electrolyte balance are likely to occur. Even the adrenal glands and pancreas are vulnerable to perinatal oxygen deprivation. The best form of management appears to be anticipation, early identification, and prevention of potential obstetrical-neonatal problems. Every effort should be made to carry out effective resuscitation measures on the depressed infant at the time of delivery.*

Perinatal asphyxia produces a wide diversity of injury in the newborn. Severe birth asphyxia, evidenced by Apgar scores of three or less at one minute, develops not only in the preterm but also in the term and post-term infant. The knowledge encompassing the causes, detection, diagnosis, and management of the clinical entities resulting from perinatal oxygen deprivation has been further enriched by investigators from various disciplines in recent years. However, in spite of the many advances, the impact of perinatal asphyxia on neonatal mortality and morbidity is still evident.

Prevention of the problem is, of course, preferable to treatment. An understanding of the pathophysiology of asphyxia is necessary to achieve this goal.

### **PATHOPHYSIOLOGY AND NATURAL HISTORY**

Perinatal asphyxia describes a clinical entity whereby the fetus or the newborn infant sustains an impairment in respiratory gas exchange. Neonatal asphyxia reflects acute respiratory failure, that is, a rapid decrease in alveolar ventilation. The number of oxygen

molecules brought into the alveoli inadequately compensate for the uptake by the blood, causing decreases in alveolar oxygen pressure ( $PO_2$ ), arterial  $PO_2$  ( $PaO_2$ ) and arterial oxygen saturation. Correspondingly, arterial carbon dioxide pressure ( $PaCO_2$ ) rises because the insufficient ventilation cannot expel the volume of carbon dioxide that is added to the alveoli by the pulmonary capillary blood. Asphyxia can be total or partial. Total asphyxia occurs when the ingress of oxygen and the egress of carbon dioxide is entirely halted. Partial asphyxia results when the respiratory gas exchange has been reduced, but not totally abolished.

For obvious reasons there is no detailed information regarding the various chemical and biophysical changes of fetal or neonatal asphyxia in the human. A useful substitute for the missing human model is the observation by Adamsons and co-workers<sup>1</sup> and Dawes<sup>2</sup> of the natural history of total asphyxia at birth in the rhesus monkey fetus.

Shortly after the onset of asphyxia, rapid gasping occurs, accompanied by muscular effort and thrashing movements of the arms and legs. This ceases after a little more than a minute, preceding the onset of primary apnea, which lasts almost 60 seconds. The animal then develops a series of spontaneous deep gasps for 4 to 5 minutes, which gradually become weaker and terminate after approximately 8 minutes of total anoxia. Secondary or terminal apnea begins after the last gasp, and death occurs if asphyxia is not reversed within several minutes. When secondary apnea occurs, spontaneous respiration cannot be induced by any sensory stimuli. The longer the delay in initiating

Submitted, revised, April 5, 1984.

From the Section of Newborn Services, Department of Pediatrics, University of Michigan Medical Center, Ann Arbor, Michigan. Requests for reprints should be addressed to Dr. Raul C. Banagale, Neonatal Special Care Unit, Emanuel Hospital, 2801 N. Gantenbein, Portland, OR 97227.

adequate ventilation, the longer it will take to initiate regular respirations.

Assuming the changes in humans are similar to those in the rhesus monkey, are mechanisms possible for a newborn infant to protect himself or herself from such an insult? It has been postulated that circulatory adjustments occur in the human infant during total asphyxia. A study of the effects of hypoxia on the rhesus monkey fetus by Behrman et al<sup>3</sup> indicates that concomitant with the decrease in total cardiac output, there is a redistribution of the available cardiac output in an attempt to provide oxygenated blood to the more vital organs. Scholander,<sup>4</sup> in his study of diving seals, found that the following reflex circulatory adjustments occur when a seal dives: (1) profound bradycardia, (2) decrease in oxygen consumption, (3) decrease in body temperature, (4) accumulation of lactic acid in muscle, (5) maintenance of central blood pressure, and (6) continued oxygenation of arterial blood at the expense of peripheral blood. When the experimental seals return to the surface, the pre-dive state resumes, and after air breathing starts, the lactic acid is removed from the muscles by the bloodstream and is subsequently metabolized by the liver.

There is, obviously, a fundamental difference between the diving mammal and the stressed human infant. In the diving mammals, the circulatory changes are not overwhelmed under the condition of a normal dive. In the asphyxiated infant, however, the circulatory changes are in response to life-threatening pathologic conditions and the protective mechanisms are quickly exhausted after short periods of asphyxia. Therefore, assuming there is some circulatory adaptation, such as a redistribution of the available cardiac output and provision of oxygenated blood to vital organs such as the brain, heart, and adrenal glands, it must be at the expense of the kidneys, spleen, lungs, and intestine. As a result, the newborn human is still likely to suffer many possible complications.

## ETIOLOGY

Table 1 lists the different causes of impairment in respiratory gas exchange. Failure of the respiratory center has been associated with prematurity, intrauterine hypoxia, obstetrical complications, and administration of drugs. Prolapse and compression of the umbilical cord, hypovolemia (resulting from placenta previa, abruptio placenta, or any other form of blood loss), and umbilical cord or placental anomalies can lead to intrauterine hypoxia. Other obstetrical problems that may lead to severe perinatal asphyxia include uterine and cervical malformation, multifetal gestation, abnormal presentation, and traumatic delivery. Administration of certain drugs including local anesthetics such

TABLE 1. CAUSES OF PERINATAL ASPHYXIA

Failure of the respiratory center
Prematurity
Intrauterine hypoxia
Umbilical cord anomalies and accidents
Hypovolemia secondary to antepartum hemorrhage
Maternal conditions (cardiovascular problems, pulmonary disease, toxemia, other systemic illness)
Obstetrical factors
Uterine and cervical malformation
Multiple gestation
Abnormal presentation
Difficult delivery
Respiratory obstructive diseases
Airway malformation
Tumors
Vocal cord paralysis
Meconium aspiration syndrome
Primary disorders
Nervous system
Respiratory muscle
Neuromuscular junction
Infections
Group B streptococcus and other bacteria
Viral

as mepivacaine and lidocaine, known to be rapidly transmitted to the fetus, may produce fetal bradycardia and hypotension. Respiratory obstructive diseases such as airway malformations, tumors, vocal cord paralysis, and meconium aspiration syndrome may also result in neonatal asphyxia. Primary disorders involving the nervous system, respiratory muscles, and neuromuscular junction (such as neonatal myasthenia gravis) are rare, but are also potential causes. Intrauterine pneumonia and sepsis may result in severe perinatal asphyxia.

## BIOCHEMICAL CHANGES DURING ASPHYXIA

Of the different biochemical events (Table 2) occurring as a result of asphyxia, the most important is the conversion from aerobic oxidation of glucose to anaerobic glycolysis. This conversion leads to accumulation of lactic acid and the development of metabolic acidosis. Respiratory acidosis may also occur because of the rapid elevation of PaCO<sub>2</sub>. A profound drop in pH is, therefore, the result of a mixed acidosis coincidental with the hypoxia. Free fatty acids and glycerol, products of neutral fat hydrolysis, increase in the blood in response to hypoxia, which may be mobilized by the release of epinephrine and norepinephrine. During labor, maternal blood glucose is elevated secondary to sympathetic stimulation, leading to a corresponding blood sugar elevation in the fetus. When the maternal blood glucose supply is terminated at birth, glycogenolysis begins immediately to provide a con-

**TABLE 2. BIOCHEMICAL CHANGES RESULTING FROM ASPHYXIA**

Respiratory and metabolic acidosis
Increased free fatty acids and glycerol
Mobilization of hepatic glycogen
Hyperkalemia and amino acidemia
Hypocalcemia
Hypoglycemia or hyperglycemia
Hyperammonemia
Hyperuricemia (?)

tinuing source of glucose to the newborn's brain. Depletion of carbohydrate reserves with a corresponding hypoglycemic state is not an uncommon finding in asphyxiated newborns. Animal studies<sup>5</sup> have shown that the adenosine triphosphate level is maintained initially at the expense of phosphocreatinine. Hyperglycemia has also been observed following perinatal asphyxia, but the genesis of this problem is unknown.

Hyperuricemia has been postulated to occur in association with perinatal hypoxia.<sup>6</sup> Hypocalcemia has been noted following perinatal asphyxia, possibly as a result of anoxic stimulation of calcitonin, increasing renal calcium loss, and diminishing calcium resorption from bone. Hypomagnesemia in association with hypocalcemia has also been noted. Hyperammonemia following severe perinatal asphyxia has been described.<sup>7,8</sup> Blood ammonia concentrations of 300 to 1,000  $\mu\text{g/dL}$  have been observed along with the clinical manifestations of central nervous system dysfunction, hyperthermia, hyperextension, and extreme heart-rate variability. Severe neurologic sequelae have been described in some surviving infants.

## CLINICAL COURSE

Perinatal asphyxia presents a wide variety of injuries to the newborn infant (Figure 1). Each of the major organ systems will be discussed.

## CENTRAL NERVOUS SYSTEM

Damage to the central nervous system accounts for the greatest number by far of clinical problems secondary to perinatal compromise. Hypoxic-ischemic encephalopathy is the most common and clinically significant occurrence following perinatal asphyxia. Additionally, intracranial hemorrhage may be associated with asphyxia. There are three major clinically important categories of intracranial hemorrhage: (1) subdural hemorrhage, (2) subarachnoid hemorrhage, and (3) periventricular, intraventricular, intracerebral, and cerebellar hemorrhage. The distinctive pathogenesis and clinical manifestations of each of

these conditions in asphyxiated newborns have been described extensively.<sup>9</sup>

The role of asphyxia in the production of central nervous system hemorrhage is multifactorial. First, hypoxia is associated with impairment of vascular autoregulation.<sup>10</sup> Second, asphyxia produces augmentation of cerebral blood flow, which may lead to the development of intracranial hemorrhage.<sup>11</sup> Third, congestion in cerebral veins causes increased pressure within the periventricular capillaries.<sup>9</sup> Fourth, hypoxia results in a distinct injury to the capillary endothelial cells and the vascular border zones within the germinal matrix.<sup>12</sup> The diagnosis of intraventricular hemorrhage and possible subsequent ventricular dilation is no longer a problem with the present advances in computed tomography and ultrasonography.<sup>9,13</sup>

Supportive treatment involves maintenance of cerebral perfusion<sup>9</sup> through maintenance of blood pressure and prevention of hypercapnia, hypoxemia, and acidemia. Hyperosmolar solutions and rapid volume expansion should be avoided. Appropriate supportive care and serial assessment of ventricular size are mandatory.<sup>9</sup> Vidyasagar and associates<sup>14</sup> reported the usefulness of intracranial pressure monitoring in infants with obstructive hydrocephalus. Seizures frequently occur and should be vigorously treated<sup>15</sup> using phenobarbital, the drug of choice, given intravenously as a loading dose of 20 mg/kg in divided doses, ten minutes apart. If seizures continue, phenytoin may be given intravenously, using a loading dose of 20 mg/kg over ten minutes. Maintenance doses are started 12 hours after the loading dose and given every 12 hours. Maintenance dosage for both drugs is 3 to 5 mg/kg/d and is adjusted according to frequent measurement of blood concentrations. Management of progressive ventricular dilation has been approached differently<sup>9,16,17</sup> and remains controversial.

Cerebral edema, an abnormal accumulation of fluid in either the extracellular space or within the cells of the brain, is one of the more severe complications of perinatal asphyxia.<sup>18</sup> If sufficiently severe, cerebral edema may lead to death by precipitating uncal and tonsillar herniation.<sup>15</sup> Despite the importance of brain swelling in hypoxic newborns, its pathophysiology and pathogenesis remain uncertain.<sup>19,20</sup> Cerebral edema can be classified into three types: cytotoxic (cellular), vasogenic, and interstitial (hydrocephalic). Cytotoxic cerebral edema results from disturbance in the cell membrane permeability, leading to increased intracellular water in the gray and white matter, but without enlargement of the extracellular space and without a breakdown of the blood-brain barrier. Hypoxia resulting from neonatal asphyxia<sup>17</sup> is associated with cytotoxic cerebral edema. Vasogenic cerebral edema is characterized by increased capillary endothelial permeability, allowing fluid from the vascular compartment to enter the space between cells.

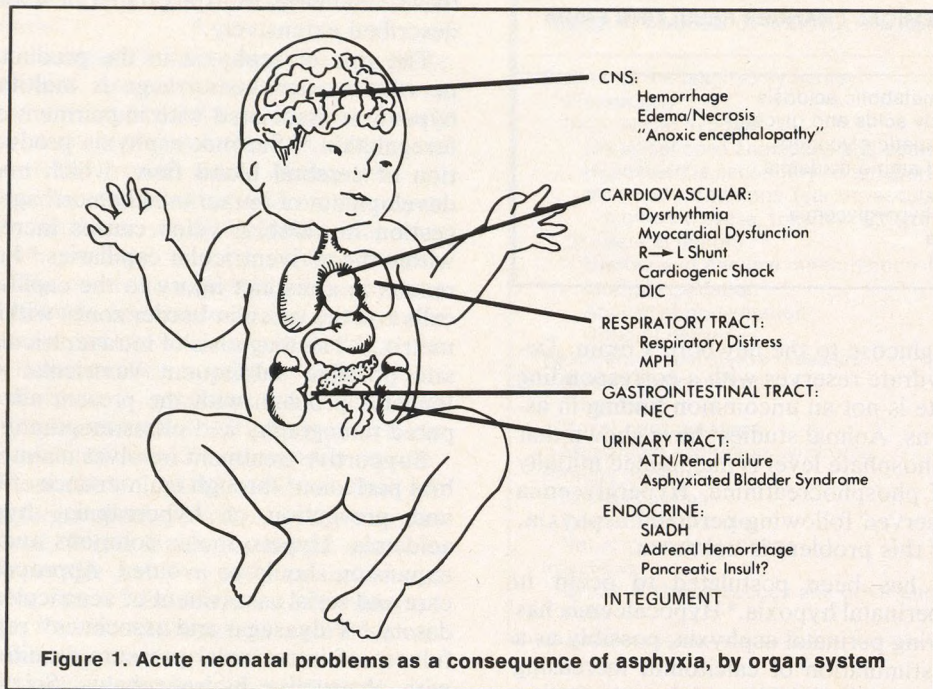


Figure 1. Acute neonatal problems as a consequence of asphyxia, by organ system

Interstitial edema results in periventricular accumulation of spinal fluid, such as that occurring with obstructive hydrocephalus.

The treatment of cerebral edema has been subject to debate. Osmotically active agents (30 percent urea at a dose of 1 to 1.5 g/kg, or 20 percent mannitol at 1.5 to 2 g/kg) given over 30 to 60 minutes have been suggested.<sup>18</sup> These hypertonic agents produce an osmotic gradient between the intravascular and extravascular compartments, reducing the extravascular water content. Glucocorticoid (dexamethasone) in a dose of 0.5 to 1 mg/kg/d in two divided doses, given at 12-hour intervals has been noted to be an adjunct in the treatment of cerebral edema. However, the exact mechanism by which steroids produce a beneficial effect in cerebral edema following asphyxia is still uncertain.<sup>21</sup> Brain swelling itself, when sufficiently severe, can lead to local capillary or small vessel occlusion, resulting in tissue necrosis. The question of when cerebral necrosis occurs is also not known. As most asphyxiated infants initially require respiratory support, hyperventilation has been attempted. The vascular compartment, if responsive to changes in carbon dioxide tension and hyperventilation, causes a reduction of the intracranial pressure by constricting cerebral vessels and decreasing cerebral blood flow, which leads to a decrease of blood volume within the cranial cavity.

The outcome of asphyxiated infants with central nervous system complications is confusing in the sense

that some infants with severe asphyxia are resuscitated and later recover, displaying persistent neurologic deficits. On the other hand, Windle<sup>22</sup> has shown that asphyxiation for more than seven minutes invariably produced at least transient neurologic signs and permanent brain damage. When hypoxic-ischemic encephalopathy is suspected, it certainly is unwise to give a definitive statement of the individual infant's long-term prognosis during the immediate postnatal period.<sup>23</sup> Extensive discussions concerning ethical and medico-legal issues in the management of severely damaged newborns have been published elsewhere.<sup>24,25</sup>

### CARDIOVASCULAR AND HEMATOLOGIC SYSTEMS

The relationship between the degree of asphyxia and appearance of myocardial damage in the newborn is not precisely known. However, it is possible for asphyxia to produce ultrastructural changes,<sup>26</sup> which may lead to dysrhythmias because of alterations in automaticity and conduction patterns. This rhythm disturbance may be sinoatrial block or supraventricular or ventricular dysrhythmias. Sinusoidal heart rate rhythms in severe neonatal hypoxia were reported by Reid et al.<sup>27</sup> Transient tricuspid insufficiency (ischemic papillary muscle necrosis) in 14 term newborn infants associated with significant perinatal asphyxia was noted by Bucciarelli and co-workers.<sup>28</sup>

Asphyxia may result in right-to-left shunting through a patent foramen ovale or patent ductus arteriosus, leading to cyanosis and signs of respiratory distress. Further discussion of the mechanisms involved is presented under the respiratory system.

Cardiogenic shock associated with perinatal asphyxia in preterm infants may resemble respiratory distress syndrome.<sup>29</sup> Primary diagnosis of cardiac failure is made with the recognition of cardiomegaly, hepatomegaly, electrocardiographic changes of myocardial ischemia, decreased myocardial contractility, elevated central venous pressure, and severe lactic acidosis. The treatment of heart failure, including the use of inotropic agents, may result in rapid improvement in the clinical manifestations within 24 to 36 hours in transient myocardial insufficiency.

Disseminated intravascular coagulation (DIC), also known as consumption coagulopathy or defibrination syndrome, is not in itself a primary disease but a response to certain stimuli. There are many conditions associated with DIC,<sup>30</sup> including infection, respiratory distress syndrome, trauma, abruptio placenta, and toxemia of pregnancy. Gross alteration in the clotting process in hypoxic infants with consumption of clotting factors leading to hemorrhagic diathesis has been noted.<sup>31</sup> Marked increase in fibrinogen turnover and fibrinolytic activity has also been observed. Hypoxia may lead to a multiple bleeding diathesis, triggering widespread coagulation with the formation of intravascular thrombi and utilization of coagulation factors and platelets. Absolute control of DIC necessitates an effective treatment of the underlying disease state. Anticoagulation with the use of heparin remains controversial. Exchange transfusion with fresh adult blood offers several potential advantages in treating DIC in newborns.<sup>32</sup>

Polycythemia and a "shift to the left" in white blood cell differential counts have also been associated with neonatal asphyxia.

## RESPIRATORY SYSTEM

Perinatal asphyxia results in alterations of the normal pulmonary physiologic transition, causing respiratory distress in the newborn infant. Significant pulmonary vasoconstriction may occur following asphyxia, triggering a progressive and usually self-perpetuating cycle similar to that found in infants with respiratory distress syndrome.<sup>33,34</sup> Pulmonary vasoconstriction may lead to an increase in pulmonary vascular resistance, producing a right-to-left shunting of blood. The resulting venous admixture leads to anaerobic metabolism and subsequent acidosis. These changes potentiate the pulmonary vasoconstriction, alveolar hypoperfusion, damage to the alveolar lining cells, and an increase in alveolar wall permeability with effusion of plasma and red blood cells into the air spaces with

fibrin deposition. Deficient anabolism of alveolar cells then decreases surfactant production and contributes to further atelectasis. The treatment is largely symptomatic and supportive, and usually follows the common modalities in the management of respiratory distress syndrome. This condition has some resemblance to "shock lung" in adult patients.

Massive pulmonary hemorrhage (MPH), a condition of unknown pathogenesis, has been associated with asphyxia and acidosis.<sup>35</sup> Factors predisposing to the development of MPH are multiple. Hypoxia or acidemia may lead to pulmonary hypertension and a right-to-left shunt at the ductal and atrial levels with left ventricular failure. When the left ventricle fails, the left atrial pressure and the pulmonary capillary pressure rise, leading to increased filtration of liquid into the interstitial tissues of the lungs. This results in edema formation and rupture of the pulmonary capillaries and alveolar membranes. Management consists of maintenance of an adequate airway and assisted ventilation. Increased peak-inspiratory and end-expiratory pressures have been recommended.<sup>36</sup> These maneuvers may produce a tamponade effect on the transudation of edema fluid and red cells from engorged capillaries and may also decrease the flow of blood from ruptured precapillary arterioles by reducing pulmonary blood flow and increasing intrathoracic pressure. Postural drainage and chest physiotherapy to maintain good pulmonary toilet are essential. Accurate maintenance of blood volume and correction of hemostatic abnormalities are necessary.<sup>37</sup>

## GASTROINTESTINAL SYSTEM

Necrotizing enterocolitis (NEC), a disease of uncertain pathogenesis and multifactorial etiology, has been associated with perinatal complications, particularly hypoxia.<sup>38</sup> Poor perfusion of the gut during the perinatal period may be caused not only by asphyxia, but also by other conditions such as umbilical arterial catheter placement, sepsis, respiratory distress, DIC, exchange transfusion, hypertonic formula feeding, immature systemic immunity, congenital heart defects (including patent ductus arteriosus), and hyperviscosity.<sup>39,40</sup>

The onset of acute necrotizing enterocolitis usually occurs in the first week of life. The clinical picture is characterized by gastric retention, intolerance of feeding (with or without vomiting of bile-stained fluid), and abdominal distention usually accompanied by bloody diarrhea. The course is progressive. The baby may become lethargic, apneic, jaundiced, and appear to be in the shock-like state usually seen in sepsis. The typical roentgenographic findings of an abnormal gas pattern with intramural gas (pneumatosis intestinalis)<sup>41</sup> or gas in the portal vein are not always observed.

Other radiographic findings that have been noted<sup>42</sup> include ileus and elongation of bowel loops, loss of bowel wall definition, and a disorganized atonic pattern of intestinal gas. Bowel perforation with the production of peritonitis and pneumoperitoneum may occur. In the absence of an acute abdomen requiring surgery, medical management includes discontinuation of oral feeding, provision of adequate parenteral nutrition, gastric decompression, and appropriate correction of acid-base and electrolyte imbalance. Evaluation for infection, including blood, stool, cerebrospinal fluid, and urine cultures should be done, followed by parenteral administration of broad-spectrum antibiotics. Measurement of the abdominal girth and follow-up radiographs of the abdomen permit early diagnosis of bowel perforation. Serial abdominal transillumination has been found to be very useful in the early detection of pneumoperitoneum in the newborn with necrotizing enterocolitis.<sup>43</sup> Some surviving infants may show mechanical and functional abnormalities of the involved intestine secondary to stricture formation or short bowel syndrome.

### GENITOURINARY SYSTEM

The acute reversible renal failure that may follow asphyxia is commonly referred to as acute tubular necrosis (ATN).<sup>44</sup> Oliver and co-workers<sup>45</sup> observed that the glomeruli and blood vessels appear, for the most part, histologically normal, whereas the tubular epithelium is irregularly damaged. The cause of renal failure was presumed to be tubular obstruction by cellular debris with the back diffusion of filtrate through the damaged tubular walls. The kidneys are very sensitive to oxygen deprivation.<sup>46</sup>

A new concept of acute renal failure has been proposed. Reduced cortical blood flow and diminished glomerular filtration<sup>46</sup> have been emphasized over the hypothesis of tubular blockage<sup>45</sup> in the pathophysiology of acute renal failure. Catecholamine release increases sympathetic tone, and activation of the renin-angiotensin system further decreases cortical blood flow. The decrease in cortical perfusion leads to a decrease in glomerular filtration and oliguria. Within 24 hours of an ischemic episode, renal insufficiency may occur. This condition is almost always reversible, but prolonged renal insufficiency can also lead to irreversible cortical and medullary necrosis. Renal papillary necrosis is rare in newborns and infants.

Infants with oliguric renal failure may be managed successfully by employing restriction of fluid, sodium, and potassium.<sup>44</sup> Correction of other predisposing factors should be done. Careful monitoring of serum creatinine, urinalysis, and serum drug concentrations (especially when nephrotoxic antibiotics are required) decreases the risks of further renal damage. The use of mannitol and furosemide as therapeutic agents is con-

troversial. Single trial doses of these agents may be given if the patient is well hydrated and normotensive, and usually only if no diuresis is obtained after a dose of 20 mL/kg of normal saline is given intravenously over a 20-minute period. Dialysis, especially peritoneal, is instituted when one or more of the following are present: (1) intractable acidosis, (2) intractable hyperkalemia, (3) abnormal expansion of the extracellular fluid with hypertension and congestive heart failure, and (4) rapid deterioration in the general clinical condition.

Delayed micturition, despite the presence of adequate urine formation and in the absence of gross anatomic abnormalities, has been reported<sup>48</sup> secondary to the asphyxiated bladder syndrome. These patients present with distended bladders, but with urine easily expressed by the Credé method, aspirated by suprapubic tap, or drained by catheterization.

### ENDOCRINE SYSTEM

The syndrome of inappropriate antidiuretic hormone (SIADH) secretion has multiple causes<sup>49</sup> and has been reported in infants following asphyxia,<sup>50</sup> though the mechanism is unknown. Possibly the osmoreceptor cells in the anterior hypothalamus are affected by asphyxia leading to inappropriate hypersecretion of antidiuretic hormone, resulting in water retention and expansion of the extracellular fluid volume. This sequence in turn inhibits the secretion of aldosterone by the adrenal cortex and leads to salt loss in the urine. The features of SIADH are (1) hyponatremia of moderate to marked degree without significant renal, adrenal, hepatic, or cardiac disease, (2) excretion of a hypertonic urine, (3) normal or low blood urea nitrogen, (4) urinary loss of administered sodium, (5) inability to maintain abnormal serum sodium concentrations by infusions of hypertonic saline, (6) correction of hyponatremia by fluid restriction, and (7) urine serum osmolality ratio of greater than one.

The most crucial differential diagnosis should be to distinguish between SIADH and adrenal insufficiency. Infants with primary adrenal insufficiency usually have hyperkalemia, dehydration, hypovolemia, and hypotension. When hyponatremia is not severe, excessive fluid retention can be reversed with a rise in serum sodium and a decrease in urinary sodium loss by simply restricting fluid intake. Supplemental sodium by mouth or intravenous isotonic saline is of no benefit under these circumstances, as the sodium will be rapidly and completely excreted. Steroids are of no direct benefit in SIADH, although they are sometimes used in the management when adrenal insufficiency cannot be ruled out.

Adrenal hemorrhage has been associated with fetal hypoxia.<sup>51</sup> Intrapartum asphyxia was associated with

adrenal hemorrhage or necrosis in about 32 percent of the cases studied.<sup>52</sup> Massive adrenal hemorrhage in the newborn usually occurs within the first few days after delivery. Shock and lethargy are the usual mode of presentation; and often by the time symptoms appear, a mass is already palpable. Blood may leak into the tissue around the gland and also be present in the peritoneal cavity. Renal vein thrombosis closely resembles this problem. The blood urea may be elevated in both conditions, but gross hematuria is usually seen only in renal vein thrombosis. Intravenous pyelography in renal vein thrombosis shows no excretion of the affected side, while in adrenal hemorrhage the kidney is displaced downward and rotated outward with flattening of the upper calyces. Sometimes a retrograde pyelogram is necessary to show the characteristic appearance. Ultrasound<sup>53</sup> and computerized tomography are now being utilized in confirming suspected adrenal hemorrhage. Treatment consists of blood transfusions; occasionally antibiotics are necessary. The use of intravenous corticosteroids is rarely necessary, but in the presence of severe shock or in bilateral hemorrhage, adrenal insufficiency should be ruled out and renal hypertension should be excluded.<sup>51</sup>

The pancreas may also be compromised in perinatal asphyxia. Hypoglycemia and, in rare cases, hyperglycemia have been observed in small for gestational age (SGA) asphyxiated neonates. Pathogenesis of hypoglycemia or hyperglycemia<sup>54</sup> is probably more related to the altered glucose metabolism, decreased glycogen, and delayed maturation of the pancreatic beta cells in SGA infants rather than a direct result of anoxic pancreatic insult.

## INTEGUMENT

Recently, Mogilner and colleagues<sup>55</sup> described a case of widespread subcutaneous fat necrosis in a newborn who had suffered severe perinatal asphyxia. They postulated that generalized ischemia of the skin occurred during the circulatory redistribution that accompanies the "diving seal" reflex. Characteristic lesions are indurated, reddish-purple in color, and nodular. The lesions vary in size, but do not appear to be tender or warm, and are generally located in the subcutaneous fat adjacent to bony structures. The prognosis for resolution is usually excellent.

## CONCLUSIONS

It is obvious that anticipation or prevention of the many problems discussed is the key to management of perinatal asphyxia. Early identification of potential obstetrical problems is mandatory, and for the high-risk fetus that may have gone through pregnancy and labor without detection, every effort should be made at

the time of delivery to carry out adequate and effective resuscitation. Anticipation of the sequelae of asphyxia neonatorum and aggressive treatment of problems as they first arise will be the key to reducing the high morbidity associated with this unfortunate event.

## References

1. Adamsons K Jr, Behrman R, James LS, et al: Resuscitation by positive pressure ventilation and Tris-hydroxymethyl-aminomethane of rhesus monkeys asphyxiated at birth. *J Pediatr* 1964; 65:807-818
2. Dawes GS: *Foetal and Neonatal Physiology: A Comparative Study of the Changes at Birth*, ed 1. Chicago, Year Book Medical, 1969, pp 141-159
3. Behrman RE, Lees MH, Peterson EN, et al: Distribution of the circulation in the normal and asphyxiated fetal primate. *Am J Obstet Gynecol* 1970; 108:956-969
4. Scholander PF: The master switch of life. *Sci Am* 1963; 209:92-105
5. Richter D: Biochemical changes in hypoxia. In James LS, Meyers R, Gaull G (eds): *Brain Damage in the Fetus and Newborn from Hypoxia or Asphyxia*. Report on the 57th Ross Conference on Pediatric Research. Columbus, Ohio, Ross Laboratories, 1967, p 56
6. Raivio KO: Neonatal hyperuricemia. *J Pediatr* 1976; 88:625-630
7. Goldberg RN, Cabal LA, Sinatra FR, et al: Hyperammonemia associated with perinatal asphyxia. *Pediatrics* 1979; 64:336-341
8. Donn SM, Banagale RC: Neonatal hyperammonemia. *Pediatr Rev* 1984; 5:203-208
9. Volpe JJ: Intraventricular hemorrhage in premature infants. *Pediatr Rev* 1980; 2:145-153
10. Lou HC, Lassen NA, Friis-Hansen B: Impaired autoregulation of cerebral blood flow in the distressed newborn infant. *J Pediatr* 1979; 94:118-121
11. Lou HC: Perinatal hypoxic-ischemic brain damage and intraventricular hemorrhage. *Arch Neurol* 1980; 37:585-587
12. Takashima S, Tanaka K: Microangiography and vascular permeability of the subependymal matrix in the premature infant. *Can J Neurol Sci* 1978; 5:45-50
13. Donn SM, Goldstein GW, Silver TM: Real-time ultrasonography. *Am J Dis Child* 1981; 135:319-321
14. Vidyasagar D, Raju TNK, Chiang J: Clinical significance of monitoring anterior fontanel pressure in sick neonates and infants. *Pediatrics* 1978; 62:996-999
15. Volpe JJ: Neonatal seizures. *Clin Perinatol* 1977; 4:43-63
16. Papile LA, Burstein J, Burstein R, et al: Posthemorrhagic hydrocephalus in low-birth-weight infants: Treatment by serial lumbar punctures. *J Pediatr* 1980; 97:273-277
17. Hill A, Volpe JJ: Seizures, hypoxic-ischemic brain injury, and intraventricular hemorrhage in the newborn. *Ann Neurol* 1981; 10:109-121
18. Batzdorf U: The management of cerebral edema in pediatric practice. *Pediatrics* 1976; 58:78-87
19. Tweed WA, Pash M, Doig G: Cerebrovascular mechanisms in perinatal asphyxia: The role of vasogenic brain edema. *Pediatr Res* 1981; 15:44-46
20. Goldstein GW: Pathogenesis of brain edema and hemorrhage: Role of the brain capillary. *Pediatrics* 1979; 64:357-360
21. Fishman RA: Steroids in the treatment of brain edema. *N Engl J Med* 1982; 306:359-360

22. Windle WF: Brain damage at birth: Functional and structural modifications with time. *JAMA* 1968; 206:1967-1972
23. Finer NN, Robertson CM, Richards RT, et al: Hypoxic-ischemic encephalopathy in term neonates: Perinatal factors and outcome. *J Pediatr* 1981; 98:112-117
24. Rabkin MT, Gillerman G, Rice NR: Orders not to resuscitate. *N Engl J Med* 1976; 295:364-366
25. Robertson A, Fost N: Passive euthanasia of defective newborn infants: Legal considerations. *J Pediatr* 1976; 88:883-889
26. Hatt PY, Moravec J: Acute hypoxia of the myocardium: Ultrastructural changes. *Cardiology* 1971; 56:73-84
27. Reid MM, Jenkins J, McClure G: Sinusoidal heart rate rhythms in severe neonatal hypoxia. *Arch Dis Child* 1979; 54:432-435
28. Bucciarelli RL, Nelson RM, Egan EA, et al: Transient tricuspid insufficiency of the newborn: A form of myocardial dysfunction in stressed newborns. *Pediatrics* 1977; 59:330-337
29. Cabal A, Devaskar U, Siassi B, et al: Cardiogenic shock associated with perinatal asphyxia in preterm infants. *J Pediatr* 1980; 96:705-710
30. Corrigan JJ: Disseminated intravascular coagulopathy. *Pediatr Rev* 1979; 1:37-46
31. Chadd MA, Elwood PC, Gray OP, et al: Coagulation defects in hypoxic full term newborn infants. *Br Med J* 1971; 4:516-518
32. Gross SJ, Filston HC, Anderson JC: Controlled study of treatment for disseminated intravascular coagulation in the neonate. *J Pediatr* 1982; 100:445-448
33. Chu J, Clements JA, Cotton E, et al: The pulmonary hypoperfusion syndrome. *Pediatrics* 1965; 35:733-742
34. Chu J, Clements JA, Cotton E, et al: Neonatal pulmonary ischemia. *Pediatrics* 1967; 40:709-766
35. Fedrick J, Butler NR: Certain causes of neonatal death: Massive pulmonary haemorrhage. *Biol Neonate* 1971; 18:243-262
36. Castile RG, Kleinberg F: The pathogenesis and management of massive pulmonary hemorrhage in the neonate. Case report of a normal survivor. *Mayo Clin Proc* 1976; 51:155-158
37. Thomas DB: Survival after massive pulmonary haemorrhage in the neonatal period. *Acta Paediatr Scand* 1975; 64:825-829
38. Santulli TV, Schullinger JN, Heird WC, et al: Acute necrotizing enterocolitis in infancy: A review of 64 cases. *Pediatrics* 1975; 55:376-387
39. Stoll BJ, Kanto WP, Glass RI, et al: Epidemiology of necrotizing enterocolitis: A case control study. *J Pediatr* 1980; 96:447-451
40. Herbst JJ, Book LS: Clinical characteristics. In Brown EG, Sweet AY (eds): *Neonatal Necrotizing Enterocolitis*. New York, Grune & Stratton, 1980, p 27
41. Leonidas JC, Krasma IH, Fox HA, et al: Peritoneal fluid in necrotizing enterocolitis: A radiologic sign of clinical deterioration. *J Pediatr* 1973; 82:672-675
42. Kogutt MS: Necrotizing enterocolitis of infancy. Early roentgen patterns as a guide to prompt diagnosis. *Radiology* 1979; 130:367-370
43. Donn SM, Kuhns LR: Transillumination of the abdomen. In Donn SM, Kuhns LR (eds): *Pediatric Transillumination*. Chicago, Year Book Medical, 1983, pp 87-88
44. Aschinberg LC, Zeis PM, Hageman JR, et al: Acute renal failure in the newborn. *Crit Care Med* 1977; 5(1):36-42
45. Oliver J, MacDowell M, Tracy A: The pathogenesis of acute renal failure associated with traumatic and toxic injury. Renal ischemia, nephrotoxic damage and the ischemic episode. *J Clin Invest* 1951; 30:1307-1351
46. Dauber IM, Krauss AN, Symchych S: Renal failure following perinatal anoxia. *J Pediatr* 1976; 88:851-855
47. Sevt S: Pathogenesis of traumatic uraemia. A revised concept. *Lancet* 1959; 2:135-140
48. Ivey HH: The asphyxiated bladder as a cause of delayed micturition in the newborn. *J Urol* 1978; 120:498-499
49. Barter FC, Schwartz WB: The syndrome of inappropriate secretion of antidiuretic hormone. *Am J Med* 1967; 42:790-806
50. Kaplan SL, Feigin RD: Inappropriate secretion of antidiuretic hormone complicating neonatal hypoxic-ischemic encephalopathy. *J Pediatr* 1978; 92:431-433
51. Black J, Williams DI: Natural history of adrenal haemorrhage in the newborn. *Arch Dis Child* 1973; 48:183-190
52. deSa DJ, Nicholls S: Haemorrhagic necrosis of the adrenal gland in perinatal infants: A clinico-pathological study. *J Pathol* 1972; 106:133-149
53. Donn SM, Pollack LD, Roloff DW: Calcified neonatal adrenal hemorrhage: Diagnostic and therapeutic considerations. *Am J Perinatol* 1983; 1:36-39
54. Pagliara AS, Karl IE, Kipnis DB: Transient neonatal diabetes: delayed maturation of the pancreatic beta cell. *J Pediatr* 1973; 82:97-101
55. Mogilner BM, Alkalay A, Nissim F, et al: Subcutaneous fat necrosis of the newborn. *Clin Pediatr* 1981; 20:748-750