

## Retinoblastoma and a Family in Crisis

John W. Saultz, MD, Jeffrey Olenick, MD, Kate Commerford, PhD, and Susan Clack, MD  
Portland, Oregon

**D**R. SUSAN CLACK (*Third-year Family Practice Resident*): Today we will discuss the Andrew family (names changed to protect confidentiality), which consists of the mother, Carlie, the father, Lee, and their daughter, Meagan. I first became acquainted with this family on an obstetrics rotation in January of 1986, when Carlie became my patient in her 37th week of pregnancy. Her pregnancy had been complicated by genital herpes and a history of intravenous drug use prior to becoming pregnant. At her second prenatal visit, I noted that Lee had a prosthetic eye. He stated that he had bilateral retinoblastoma diagnosed when he was 4 years old. I reviewed the literature and learned that retinoblastoma can be an autosomal-dominant trait. I recommended that they see a pediatric ophthalmologist soon after the child's birth. Lee stated they had undergone counseling prior to starting a family, and that both he and Carlie understood the risks and would comply.

On January 23, 1986, Carlie went into labor after having prodromal symptoms of genital herpes. An active lesion was noted on the cervix, and a cesarean section was performed. She had an uncomplicated postoperative course and was discharged with the baby after four days. At both the two-week and two-month postpartum appointments, I stressed the importance of ophthalmology consultation, and appointments were made for the child, although results of an eye examination were thought to be normal in the Family Practice Center. These ophthalmology appointments were not kept.

The baby, Meagan, was admitted to the hospital on April 30, 1986, for evaluation of mild cyanotic spells of unknown etiology. She was discharged on the third day with a heart rate monitor for use at home. Appointments for the four-month and six-month well-child checkups were kept in the Family Practice Center with normal findings on examinations. Carlie continued to delay in keeping an appointment with the ophthalmologist. When I asked

her about this at the six-month visit, Carlie responded, "I had a sprained leg. You don't find anything wrong with the child here in the clinic, and it can't be that important, since they didn't do anything in the hospital." The importance of an ophthalmology consultation was again stressed, and an appointment with the eye clinic was scheduled and kept on July 30, 1986. The child was found at that time to have bilateral retinoblastoma. On August 1, 1986, she was admitted to the hospital for metastatic workup, which was negative. Radiation therapy was started at that time.

**DR. JEFFREY OLENICK** (*Assistant Professor of Family Medicine*): Retinoblastoma was one of the first tumors recognized as having a genetic predisposition, and that predisposition was one of the first to be analyzed in terms of the genetic defect on the chromosomes of the affected individual. Retinoblastoma is the most common tumor that physicians will encounter in the eyes of children, with an incidence of 1 in 18,000 live births. Typically, the disease is discovered on fundoscopic examination, when the physician sees a white reflex (leukocoria). Several conditions that can cause leukocoria in children are listed in Table 1.<sup>1</sup> All children with leukocoria or a family history of retinoblastoma should undergo very careful eye examination under general anesthesia.

Forty percent of cases of retinoblastoma and virtually all cases of bilateral retinoblastoma are associated with a familial predisposition.<sup>2</sup> The remainder are cases of sporadic mutation that are not considered to be inherited. The average age of diagnosis of bilateral retinoblastoma is 8 months, but the average age of diagnosis of unilateral retinoblastoma is 26 months, a very great difference. Most of the cases of unilateral disease are identified during routine examination, most commonly because of leukocoria, decreased visual acuity in the eye, hyphema, disconjugate gaze, or other abnormalities of the eye examination. Obtaining a careful family history for all babies is essential because, when positive, the child should have regular examinations under anesthesia every six to eight weeks until the age of 2 years. Familial retinoblastoma will nearly always be apparent by the age of 2 years.

The child who is found to have leukocoria should be evaluated with a variety of tests. In the past, the diagnosis was confirmed by the finding of calcifications on plain x-

Submitted, revised, April 1, 1988.

From the Department of Family Medicine, Oregon Health Sciences University, Portland, Oregon. Requests for reprints should be addressed to Dr. John W. Saultz, Department of Family Medicine, Oregon Health Sciences University, 3181 S. W. Sam Jackson Park Rd, Portland, OR 97201.

TABLE 1. CONDITIONS ASSOCIATED WITH LEUKOCORIA

Hypoplastic primary vitreous
Bacterial panophthalmitis
Parasitic infection
Cataracts
Retinopathy of prematurity
Retinal detachment
Retinoblastoma
Other tumors of the eye

ray films, but computerized tomography (CT scanning) is now the standard diagnostic tool for retinoblastoma. Magnetic resonance imaging (MRI) may eventually prove to be the superior test for this disease because of the large amount of bone in the area, as MRI is generally superior to CT for examining soft tissues near bone.<sup>3</sup> Another reason to do CT or MRI scanning is to exclude intracranial tumors, especially the so-called trilateral retinoblastoma syndrome, in which there is disease in both eyes and the pineal gland. This syndrome is nearly always familial.

Bone scan, bone marrow biopsy, and lumbar puncture are usually done to evaluate areas where the disease can metastasize. The survival rate is 90 percent if the disease has not spread beyond the globe (stage I and II). In disease that has spread beyond the globe, either into the brain or to distant sites, the survival rate is much lower.

Cases that are characterized by familial predisposition are inherited as an autosomal-dominant trait. The locus of the retinoblastoma gene was identified early in the history of karyotyping. Retinoblastoma will develop in about 50 percent of children with deletion of all or part of the long arm of chromosome 13. This observation led to the discovery of the gene for retinoblastoma on band 14 of the long arm of chromosome 13.<sup>4</sup> The latest development in the chromosomal analysis of this disease is deoxyribonucleic hybridization analysis of the chromosomes of affected children, a process that may someday make it possible to diagnose familial retinoblastoma prenatally. Children who have a familial predisposition are also more likely to develop other tumors later in life, the most common being osteosarcoma. About 13 percent of children with the trait will develop other tumors. The average age is 10 years and the mortality rate is nearly 85 percent.

**DR. CLACK:** Findings on Meagan's metastatic workup were negative, and she was scheduled to receive daily radiation therapy. On August 16, approximately one week later, Carlie came to the Family Practice Center complaining of chest pain, epigastric tenderness, and episodes of hyperventilation. Results of a chest x-ray examination, electrocardiogram, and laboratory studies were normal. A week later, x-ray films of the upper gastrointestinal tract were done, which also showed normal results. Ibuprofen was prescribed and the symptoms slowly improved. Also within a week of Meagan's discharge, Lee complained of intermittent back pain. He also improved with ibuprofen. A social history revealed multiple areas of stress in the

family. Besides Meagan's hospitalization, Carlie lost her job as a waitress, and Lee's job was cut to 80 percent time.

On October 9, 1986, Carlie came into the clinic complaining of amenorrhea and "feeling pregnant." Tearfully, she stated that she had not been taking her birth control pills for the last month. Stresses that had changed at home included her husband losing his job, with their health insurance ending at the end of the month. Carlie had a motor vehicle accident that destroyed the family car, and transportation was difficult to arrange for Meagan's radiation therapy. There was increasing conflict between Carlie and Lee and some talk of divorce. A pregnancy test was positive and an examination revealed a ten-week-sized uterus. After discussions with her minister and her husband, and after counseling in the Family Practice Center, Carlie underwent an elective abortion on October 22 with no complications.

On November 6, 1986, Carlie presented to the Family Practice Center with a complaint of weak legs. She stated that she woke up in the morning to tend Meagan and was unable to stand for five minutes. She denied any change in vision, loss of consciousness, or difficulty with her arms. Afterward, she could walk normally, had a normal bowel movement, and urinated. About one hour later she completely lost use of her legs. At this appointment Carlie also disclosed that several family members had been un-supportive about the abortion, including Carlie's step-mother. In addition, the ophthalmologist had recently told Carlie that Meagan was blind in the left eye. Carlie felt the radiation therapy had failed. On examination, Carlie was able to wiggle her toes but had no muscular strength or pain sensation in the lower extremities. When the leg was elevated and dropped, the patient was able to keep the leg from dropping so quickly that it injured her. The deep tendon reflexes were intact and symmetrical, and she had normal rectal tone. During the examination, both Lee and Carlie appeared less concerned than expected about these symptoms. We felt the most likely diagnosis was hysterical paralysis, but a neurology consultation was obtained, and the patient was admitted to the hospital for further evaluation. A myelogram, spinal tap, and blood studies all showed normal results, and her leg function returned gradually over the next two days. We also consulted with Dr. Kate Commerford during this hospitalization.

**DR. KATE COMMERFORD** (*Assistant Professor and Behavioral Science Director*): I was able to evaluate this family both during and after Carlie's hospitalization. Dr. Clack obtained a family genogram, and psychological testing was done including the Minnesota Multiphasic Personality Inventory (MMPI) and the Holmes-Rahe Life Stress Indicator.

Let's look first at the family genogram (Figure 1). Carlie is the fourth of five children. Her mother, Flo, had numerous marriages, and is currently involved in an abusive relationship that is not a marriage. On the other side of the family, Lee is the second of two boys. Carlie has had a total of four pregnancies, three of which ended in elective

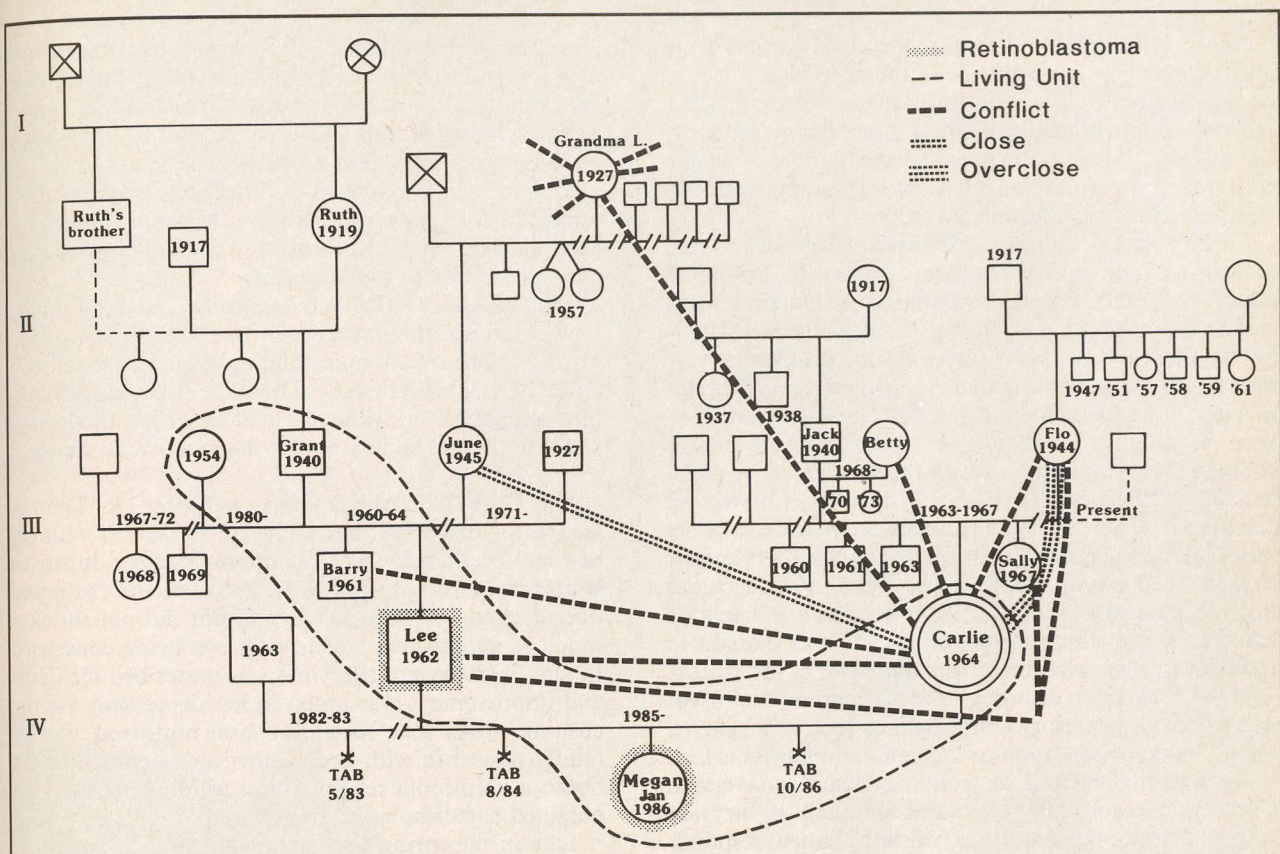


Figure 1. Genogram of the Andrew family. TAB—Therapeutic Abortion

abortions. The third pregnancy resulted in the birth of Meagan. As far as we know in this family, the retinoblastoma has been found only in Meagan and Lee.

Genograms may also include information regarding the relationships in the family. This genogram conveys a significant amount of conflict between family members. Carlie has conflict with Lee, Lee's brother, her own sister, her stepmother, and with Lee's maternal grandmother. The only close positive relationship for Carlie is with Lee's natural mother. Carlie appears to have an overly close relationship with her own mother, which includes frequent conflict. Lee's relationships are also either conflictual or neutral, but there are none with any real closeness. Lee's conflicts are primarily with Carlie, Carlie's mother, and her sister.

The Holmes-Rahe Life Stress Indicator<sup>5</sup> is a test used to measure the amount and nature of stress on an individual during a given time. Holmes and his colleagues have developed scales to measure life experiences; scores of 300 or greater have been found to correlate positively with increased incidence of illnesses. It is now thought that illnesses do not occur at random; rather, they coincide with events in a person's life and with the person's emo-

tional state.<sup>6</sup> Carlie's score over the preceding six months was 389, an increase from six months to one year ago when her score was 325, and an even greater increase from one to two years ago, when her score was 147. It is often helpful to patients to see by numerical indication that there has been increased stress. Carlie was quite surprised and very impressed with her score. Dr. Clack and I felt at the time that this test helped her to make connections between her stress and her physical complaints.

Carlie's MMPI results yielded a profile that indicates that Carlie is not psychotic; rather, her dysfunctional behavior was related to neurotic or personality processes. For those who are familiar with the MMPI, Carlie's profile is coded by the Welsh system as 3<sup>+</sup>4217/6 80-/9:5 F-L/K. These results are typical of patients who are psychologically immature and egocentric. These patients tend to resist the idea that psychological factors are involved in their physical problems and lack insight into the origins of their own behavior. In fact, they tend to blame other people or circumstances for their difficulties. Carlie's MMPI results indicate considerable hostility and an inability to discharge that hostility directly. Her results point to the presence of significant family problems. She re-

ported both marital and family discord with very little understanding of her own role in them. In fact, it would be typical for a person with this pattern to irritate other individuals into attacking them in some manner. Finally, Carlie's MMPI results are consistent with those of people who under stress develop physical complaints with obvious secondary gain characteristics.

Carlie's history and testing are both consistent with the diagnosis of conversion disorder. Conversion disorder is described in the revised third edition of the *Diagnostic and Statistics Manual of Mental Disorders (DSM-III-R)*<sup>7</sup> as "an alteration or loss of physical functioning that suggests physical disorder, but that is apparently an expression of a psychological conflict or need." The *la belle indifférence*, in which the patient's attitude suggests a lack of concern that is inconsistent with the severity of the problem, is particularly classic of this disorder. Conversion disorders in which an actual paralysis occurs are extremely rare. Years ago, hysteria and conversion disorders appear to have been more common. The word *hysteria* comes from a Greek word meaning *womb* because the diagnosis has been more common in women and was thought to result from a misplacement or wandering of the womb. Today a conversion disorder more often presents as pseudo-seizures or as sensory abnormalities such as a "gloved hand" in which sensation to the hand and fingers is lost.

As with malingering or factitious illness, conversion disorders are not really diagnoses as much as they are ways to describe the manner in which the patient responds to stressors. For example, in this case one of the interesting factors was that Carlie's paralysis occurred when she was on her way to take care of her child. It seems obvious that the conversion substitutes physical symptoms for repressed instinctual impulses not acceptable to the patient. The paralysis then alleviates the need for her to address her conflict specifically. In addition, conversion reaction is thought to be a way to seek the sick role, which Carlie did periodically throughout her entire relationship with Dr. Clack. Conversions can be a nonverbal means of communicating distress in the physician-patient relationship. It is not necessarily a matter of a physician not being able to respond so much as the patient being unable to communicate.

Carlie's diagnoses also include dependent personality, possibly with passive-aggressive tendencies. Unfortunately people with this kind of psychological makeup do not have a good prognosis in terms of being able to handle things better in the future. The combination of conversion disorder with dependent personality puts her at risk of having numerous extensive diagnostic workups for her physical complaints.

Questions have been raised about how to approach such a patient. Because it is important to avoid extensive diagnostic testing when the patient presents with new symptoms, one possibility would be to do the medical workup very slowly. Another approach would be to make concrete suggestions to the patient that relate to antici-

pating the next symptom and then dealing with it. These new symptom possibilities and their related coping strategies should be specific and should be done in concert with any medical tests. It may be useful to use her suggestibility in a treatment mode such as hypnosis.

Patients with conversion disorders present an excellent opportunity in which to convene the family, which can help alleviate the patient's need to use the physical complaints as a way to gain attention.

DR. PETER GOODWIN (*Family Practice Faculty*): How fixed are the patterns on the MMPI? How likely might they be a temporary finding given the situation?

DR. COMMERFORD: The MMPI scores definitely fluctuate; however, what you tend to see is a moderation of the peaks and valleys, rather than an overall change in the pattern.

DR. CLACK: Carlie did fairly well after Dr. Commerford and I discussed the results of the MMPI with her. She had occasional visits for minor illnesses during the winter and early spring of 1987. Both Lee and Carlie were unemployed. As Meagan's eye tumor did not shrink as much as anticipated, enucleation was being considered. In late February amitriptyline was prescribed for Carlie, and improvement was noted in her depression over the ensuing weeks. The social situation improved after the family moved in with Lee's father and stepmother. Lee began a vocational rehabilitation training program and obtained part-time work.

Late in the spring Carlie confided to me that she felt she was the cause of Meagan's disease because she had been on drugs during the pregnancy. She admitted feeling guilty about not taking the child to the ophthalmologist sooner and was anxious about my impending graduation from the residency, which would require her to have a new primary care physician. At that time she also complained of light-headedness and had several witnessed episodes of seizure-like activity. Currently she is in the process of being evaluated for these with an electroencephalogram (EEG) and CT scan, and we have discussed the possibility that these episodes are also stress related in keeping with her diagnosis of conversion disorder.

DR. JOHN SAULTZ (*Assistant Professor of Family Medicine and Residency Director*): The adjustment of patients to a change in physicians is an important issue in all residency programs each June when third-year residents graduate. Dr. Clack has spent a lot of time with this family, and her leaving will represent a major stress to them. This case also had an emotional impact on the physicians involved, which in turn can alter many aspects of the physician-patient relationship.

DR. CLACK: Each time I saw the family during the first six months of Meagan's life, I stressed the need to keep the ophthalmology consultation appointments, but they didn't do it. It took almost six months to work through blaming myself for not personally taking the child to the ophthalmologist. I am sure this caused the parents to feel even worse.

continued on page 626

# NIX FOR LICE®

## CREME RINSE

### permethrin 1%

Rx  
 Nix  
 Disp 2 fl. oz  
 Sig. as  
 directed on bottle  
 label  
 Tom Smith, MD

**PEDICULICIDAL/OVICIDAL ACTIVITIES:** *In vitro* data indicate that permethrin has pediculicidal and ovicidal activity against *Pediculus humanus var. capitis*. The high cure rate (97-99%) of Nix in patients with head lice demonstrated at 14 days following a single application is attributable to a combination of its pediculicidal and ovicidal activities and its residual persistence on the hair which may also prevent reinfestation.

**INDICATIONS AND USAGE:** Nix is indicated for the single-application treatment of infestation with *Pediculus humanus var. capitis* (the head louse) and its nits (eggs). Retreatment for recurrences is required in less than 1% of patients since the ovicidal activity may be supplemented by residual persistence in the hair. If live lice are observed after at least seven days following the initial application, a second application can be given.

**CONTRAINDICATIONS:** Nix is contraindicated in patients with known hypersensitivity to any of its components, to any synthetic pyrethroid or pyrethrin, or to chrysanthemums.

**WARNING:** If hypersensitivity to Nix occurs, discontinue use.

#### PRECAUTIONS:

**General:** Head lice infestation is often accompanied by pruritus, erythema, and edema. Treatment with Nix may temporarily exacerbate these conditions.

**Information for Patients:** Patients with head lice should be advised that itching, redness, or swelling of the scalp may occur after application of Nix. If irritation persists, they should consult their physician. Nix is not irritating to the eyes; however, patients should be advised to avoid contact with eyes during application and to flush with water immediately if Nix gets in the eyes. In order to prevent accidental ingestion by children, the remaining contents of Nix should be discarded after use.

Combing of nits following treatment with Nix is not necessary for effective treatment. However, patients may do so for cosmetic or other reasons. The nits are easily combed from the hair treated with Nix after drying.

**Carcinogenesis, Mutagenesis, Impairment of Fertility:** Six carcinogenicity bioassays were evaluated with permethrin, three each in rats and mice. No tumorigenicity was seen in the rat studies. However, species-specific increases in pulmonary adenomas, a common benign tumor of mice of high spontaneous background incidence, were seen in the three mouse studies. In one of these studies there was an increased incidence of pulmonary alveolar-cell carcinomas and benign liver adenomas only in female mice when permethrin was given in their food at a concentration of 5000 ppm. Mutagenicity assays, which give useful correlative data for interpreting results from carcinogenicity bioassays in rodents, were negative. Permethrin showed no evidence of mutagenic potential in a battery of *in vitro* and *in vivo* genetic toxicity studies. Permethrin did not have any adverse effect on reproductive function at a dose of 180 mg/kg/day orally in a three-generation rat study.

**Pregnancy: Teratogenic Effects:** Pregnancy Category B: Reproduction studies have been performed in mice, rats, and rabbits (200-400 mg/kg/day orally) and have revealed no evidence of impaired fertility or harm to the fetus due to permethrin. There are, however, no adequate and well-controlled studies in pregnant women. Because animal reproduction studies are not always predictive of human response, this drug should be used during pregnancy only if clearly needed.

**Nursing Mothers:** It is not known whether this drug is excreted in human milk. Because many drugs are excreted in human milk and because of the evidence for tumorigenic potential of permethrin in animal studies, consideration should be given to discontinuing nursing temporarily or withholding the drug while the mother is nursing.

**Pediatric Use:** Nix is safe and effective in children two years of age and older. Safety and effectiveness in children less than two years of age have not been established.

**ADVERSE REACTIONS:** The most frequent adverse reaction to Nix is pruritus. This is usually a consequence of head lice infestation itself, but may be temporarily aggravated following treatment with Nix. 5.9% of patients in clinical studies experienced mild temporary itching; 3.4% experienced mild transient burning/stinging, tingling, numbness, or scalp discomfort; and 2.1% experienced mild transient erythema, edema, or rash of the scalp.

#### DOSAGE AND ADMINISTRATION:

**Adults and Children:** Nix is intended for use after the hair has been washed with shampoo, rinsed with water and towel dried. Apply a sufficient volume of Nix to saturate the hair and scalp. Nix should remain on the hair for 10 minutes before being rinsed off with water. A single treatment is sufficient to eliminate head lice infestation. Combing of nits is not required for therapeutic efficacy, but may be done for cosmetic or other reasons.

#### SHAKE WELL BEFORE USING.

**HOW SUPPLIED:** Nix (Permethrin) 1% (wt./wt.) Creme Rinse is supplied in plastic squeeze bottles that contain 2 fl. oz. weighing 56 g. (NDC-0081-0780-81)  
 Store at 15°-25°C (59°-77°F).

1. Davies J, Dedia H, Morgade C, et al: Lindane poisonings, *Arch Dermatol* 1983;119:142-144.
2. Taplin D, Meinking T, Castillero P, et al: Permethrin 1% creme rinse for the treatment of *pediculus humanus var capitis* infestation. *Pediatr Dermatol* 1986;3:344-348.
3. Taplin D, Meinking T: Pyrethrins and pyrethroids for the treatment of scabies and pediculosis. *Semin Dermatol* 1987;6:125-135.



**Burroughs Wellcome Co.**  
 3030 Cornwallis Road  
 Research Triangle Park, NC 27709

## RETINOBLASTOMA AND FAMILY CRISIS

continued from page 624

**DR. SAULTZ:** How did you present the idea of doing a CT scan and an EEG to this patient to avoid reinforcing her behavior?

**DR. CLACK:** I actually told her that I thought the workup would be negative. She said that was fine, but she needed to reassure her husband. She believes that these episodes are stress related.

**DR. SAULTZ:** When one reviews the various problems that have occurred over an 18-month period with these three people and their physicians, it is reductionistic to simply call this a "case of retinoblastoma." Most of this Grand Rounds was spent discussing family issues, which were of great importance to caring for this family. We have not been able to delve into the pattern of drug and alcohol abuse in the parents, which is clearly important, and we have only briefly touched on the many social problems confronting this family. Indeed, the whole focus of this presentation has moved away from retinoblastoma and has instead been directed on the effect of this problem on the family and the effect of the family's dysfunction on Meagan's health care. Finally, it is clear that Dr. Clack has become an integral part of this family's ability to cope with both stress and illness, emphasizing the intimate role of the family physician within the family system.

#### References

1. Behrman RE, Vaughan VC: Nelson Textbook of Pediatrics, ed 12. Philadelphia, WB Saunders, 1983
2. Gilbert F: Retinoblastoma and cancer genetics. *N Engl J Med* 1986; 314:1248-1250
3. Schulman JA, Peyman GA, Mafee MF, et al: The use of magnetic resonance imaging in the evaluation of retinoblastoma. *J Pediatr Ophthalmol Strabismus* 1986; 23(3):144-147
4. Cavenee WK, Murphree AL, Shull MM, et al: Prediction of familial predisposition to retinoblastoma. *N Engl J Med* 1986; 314:1201-1207
5. Holmes TH, Rahe RH: The social readjustment rating scale. *J Psychosom Res* 1967; 11:213-218
6. Rahe RH, McKeen JD, Arthur RJ: A longitudinal study of life change and illness patterns. *J Psychosom Res* 1967; 10:355-366
7. Diagnostic and Statistical Manual of Mental Disorders, ed 3 (revised). Washington DC, American Psychiatric Association, 1987