

Fire Ants: The Death March

Meyer P. Schwartz, MD

Augusta, Georgia

Fire ants, virtually indestructible insects able to wreak havoc on everything from human and animal life to highway systems and farm machinery, are on the move in the United States. Since arriving in this country some time before World War II, they have spread across more than 150 million acres in 13 states, from Florida to Texas (Figure 1), with sightings also reported in New Mexico, Arizona, and California. For humans, the consequences of fire ant bites range from an annoying burning sensation to anaphylaxis and death.

Case Report

A 31-year-old man arrived at the emergency department 30 minutes after suffering one fire ant bite on the right thumb. The patient stated that 2 to 3 minutes after the bite, he noted a metallic taste in his mouth and a sudden onset of the "worst headache of my life," bitemporal and "spreading out." Shakiness, paresthesia, and tachycardia to 140 beats per minute developed. The patient also noted flushing. At no time did respiratory compromise occur. Since the patient had some medical knowledge, he took 30 mL of Dimetapp and called a friend to take him to the hospital.

Neither the patient nor his family had any known hypersensitivities. He had lived his entire life in the Midwest, except for 1 year as an infant (during which time, he later learned, he had his first fire ant exposure). There was no personal or family history of headaches, heart disease, or diabetes. The patient was in good health before the sting.

On presentation, the patient's vital signs were stable (blood pressure, 150/90 mm Hg, pulse, 115 beats per minute, respiration rate, 20 breaths per minute, temper-

ature, 37.8°C [100°F]). Physical examination was unremarkable except for a 2-mm indurated area on the right thumb. The neurologic examination was normal. Since the risk of acute intracranial hemorrhage was in the differential, a lumbar puncture (LP) and a computed tomography (CT) scan were obtained. The LP had a slightly elevated opening pressure of 232 mm H₂O and slightly elevated protein of 56 mg/dL (normal, 15 to 45 mg/dL). Neither of these were ever explained. There were no white blood cells, red blood cells, or organisms in the cerebrospinal fluid, however, and the glucose level was normal. The CT scan of the head was within normal limits. The diagnosis of fire ant hypersensitivity was made, and the patient was observed in the hospital overnight.

The patient underwent intradermal allergy testing for fire ant sensitivity at 4 weeks postexposure. He reacted at 1:1 million (wt/vol) for fire ant whole-body extract (a typical reaction level for patients with systemic symptoms), but declined testing for cross-reactivity for other stinging insects (*Hymenoptera*). The patient underwent desensitization and maintenance therapy. He has suffered one further bite, approximately 1 year after the initial reaction, which resulted in only local erythema. No treatment was needed.

Discussion

Two imported species of the fire ant (Figure 2) have been introduced into the United States: the black imported fire ant, *Solenopsis richteri* (native to Argentina and Uruguay), and the red imported fire ant, *Solenopsis invicta* (native to Paraguay and Brazil). Both entered by ship through the port city of Mobile, Alabama, early in this century.¹⁻³ In the 1950s, the US Department of Agriculture issued regulations to limit the spread of fire ants.⁴ Nevertheless, fire ants now cover between 160 and 250 million acres in 13 southern states.^{2,3} The imported fire ants have overwhelmed the two native groups, *Solenopsis geminata* and *Solenopsis xyloni*, which are primarily forest-

Submitted, revised, August 6, 1991.

From the Department of Family Medicine, Medical College of Georgia, and the Department of Emergency Medicine, Humana Hospital, Augusta, Georgia. Requests for reprints should be addressed to Meyer P. Schwartz, MD, Department of Family Medicine, Medical College of Georgia, Augusta, GA 30912.

continued from page 406

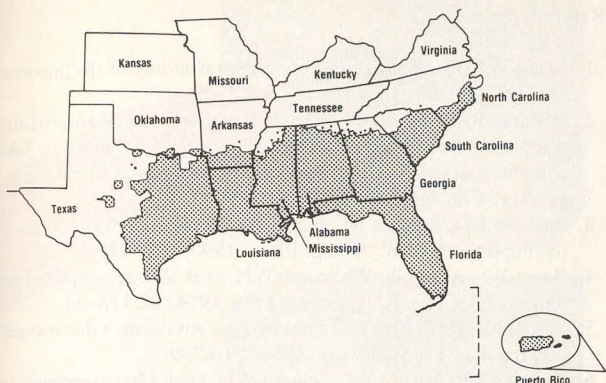


Figure 1. Distribution of imported fire ants in the United States (US Department of Agriculture).

dwelling ants,⁵ are nonaggressive, and generally do not represent a significant risk to man or animal.⁶ *S. invicta* now accounts for 90% of all ants in heavily infested areas.²

The imported fire ants have exploited newly constructed areas. Ants build mounds (Figure 3) in yards, playgrounds, and open fields in concentrations as high as 400 mounds per acre.⁷ On farms they can damage equipment, and the tunnels under their mounds can collapse roads. Imported fire ants kill other ground-dwelling insects and many small animals and birds. They are less active in winter, but their colonies are perennial.⁸

The average fire ant mound is from 0.25 to 0.38 m (10 to 15 in.) high, although it can be 0.9 m (3 ft) above ground and extend 0.9 to 1.5 m (3 to 5 ft) underground, radiating 39 m (130 ft).³

Chemical control has been extremely difficult because fire ants rapidly reproduce and replenish their colonies. Several thousand queens are produced by each




Figure 2. A fire ant.

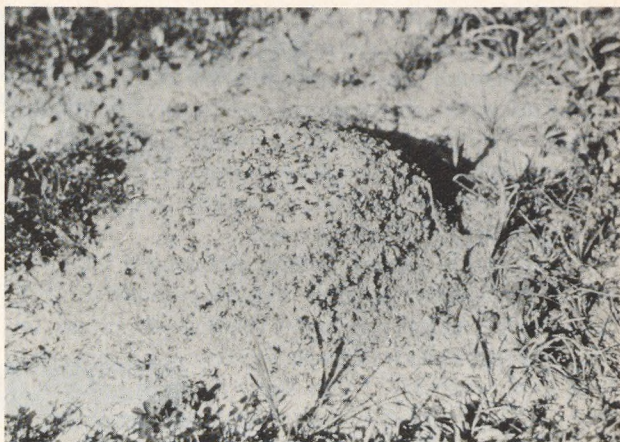

Figure 3. A fire ant mound.

colony, many of which are fertile, thus increasing the colony's resistance to natural threats and pesticides.⁹

Currently, Andro (American Cyanamid) is the best legally available chemical for destroying fire ants.⁵ Treating individual mounds gives only temporary relief. "Broadcast treatment," which uses attractant baits of soybean oil, grits, and a chemical agent that the ants take deep into the mound to the queen, appears to be more capable of clearing large areas.³

Between 30% and 60% of the population in infested areas are stung each year.¹⁰ Stings are more common among children. A recent study² found that victims who had died from fire ant bites ranged in age from infancy to 65 years. Most deaths were caused by fewer than five stings.

The imported fire ant grasps the intended victim with its jaws. It then pivots about its head, stinging multiple sites in a circular fashion with its abdominal stinger. The stinger is a modified ovapositor with a venom gland.^{6,11} Almost all persons stung will develop a wheal-and-flare reaction, which resolves within 30 minutes to 1 hour.¹² This then evolves into a sterile pustule at the site of the sting within 24 hours. The fire ant is the only insect in the United States whose sting produces this type of pustule.⁶ No treatment has been shown to prevent or resolve pustules.³

Between 17% and 56% of patients have large local reactions (painful, pruritic swelling at least 5 cm in diameter⁸) at the sting site. Topical corticosteroid ointments, local anesthetic creams, and oral antihistamines may be useful.

It is estimated that anaphylaxis occurs as a result of between 0.6% and 4% of stings.¹³ Anaphylaxis may occur up to several hours after a sting.⁵ Anaphylaxis to imported fire ant stings is treated as are other types of

anaphylaxis: respiratory and cardiac support is provided as needed and as is appropriate.

The natural history of sensitivity to imported fire ants is unknown; therefore, the indications for immunotherapy to prevent sting-related anaphylaxis are unclear.³ It is impossible, however, for sensitized persons who live in infested areas to completely avoid fire ants; therefore, desensitization is commonly used.

The venom protein (which makes up 0.1% of the venom by weight) induces immunoglobulin E (IgE) responses in allergic persons.³ Whole-body extract immunotherapy (which contains the venom protein) has a high level of efficacy.¹⁴ One study reported that 65 patients suffered anaphylaxis as a result of fire ant stings, demonstrated IgE response by skin testing, and underwent immunotherapy with whole-body extract.¹⁵ Forty-seven (72%) were unexpectedly stung by fire ants after treatment; only one had anaphylaxis. In a control group of 11 patients allergic to fire ants who elected not to undergo immunotherapy, six had unexpected stings; all six had anaphylaxis.¹⁵

As fire ants spread, possibly covering one quarter of the land area of the United States,³ more and more people will be exposed to this pesky, irritating, and potentially lethal insect. Further research into venom immunotherapy and control of the insects must be undertaken.

Key words. Ants; insect bites and stings.

Acknowledgment

The author wishes to thank Martha Anne Tudor and Chester Stafford, MD, for their suggestions for this manuscript, and Barbara Miller for typing the manuscript.

References

1. Buren WF. Revisionary studies on the taxonomy of the imported fire ants. *J Ga Entomol Soc* 1972; 7:1-25.
2. Rhoades RB, Stafford CT, James FK. Survey of fatal anaphylactic reactions to imported fire ant stings: report of the Fire Ant Subcommittee of the American Academy of Allergy and Immunology. *J Allergy Clin Immunol* 1989; 84:159-62.
3. deShazo RD, Butcher BT, Banks WA. Reactions to the stings of the imported fire ant. *N Engl J Med* 1990; 323:462-6.
4. Buren WF, Allen GE, Whitcomb WH, et al. Zoogeography of the imported fire ants. *J NY Entomol Soc* 1974; 82:113-24.
5. Bloom FL, DeMastro PR. Imported fire ant death: a documented case report. *J Fla Med Assoc* 1984; F1:87-9.
6. Rhoades RB, Schafer WL, Schmid WH, et al. Hypersensitivity to the imported fire ant. *J Allergy Clin Immunol* 1975; 56:84-93.
7. Conniff R. You never know what a fire ant is going to do next. *Smithsonian* 1990; 21:48-57.
8. Stafford CT, Hoffman DR, Rhoades RB. Allergy to imported fire ants. *South Med J* 1989; 82:1520-7.
9. Glancy BM, Craig CH, Stringer LE, et al. Multiple fertile queens in colonies of the imported fire ant, *Solenopsis invicta*. *J Ga Entomol Soc* 1973; 8:237-8.
10. Clemmer DI, Serfling RE. The imported fire ant: dimensions of the urban problem. *South Med J* 1975; 68:1113-8.
11. Rhoades RB, Schafer WL, Newman M, et al. Hypersensitivity to the imported fire ant in Florida: report of 104 cases. *J Fla Med Assoc* 1977; 64:247-54.
12. deShazo RD, Griffing C, Kuan TH, et al. Dermal hypersensitivity reactions to imported fire ants. *J Allergy Clin Immunol* 1984; 74:841-7.
13. Triplett RF. The imported fire ant: health hazard or nuisance? *South Med J* 1976; 69:258-9.
14. Stafford CT, Rhoades RB, Bunker-Soler AL, et al. Survey of whole body-extract immunotherapy for imported fire ant—and other hymenoptera-sting allergy: report to the Fire Ant Subcommittee of the American Academy of Allergy and Immunology. *J Allergy Clin Immunol* 1989; 83:1107-11.
15. Hylander RD, Ortez AA, Freeman TM, et al. Imported fire ant immunotherapy: effectiveness of whole body extracts [abstract]. *J Allergy Clinical Immunol* 1989; 83:232.