

# Follow-up Papanicolaou Smear for Cervical Atypia: Are We Missing Significant Disease?

## A HARNET\* Study

David C. Slawson, MD; Joshua H. Bennett, MD; and James M. Herman, MD, MSPH

Harrisburg and Hershey, Pennsylvania

**Background.** The presence of cervical atypia on the Papanicolaou (Pap) smear may be an indicator of significant cervical disease. Many investigators recommend that colposcopy be performed in these women. We wished to determine the prevalence of undetected cervical intraepithelial neoplasia (CIN) among women identified as having cervical atypia by cytologic testing in a primary care setting.

**Methods.** Pap smears were performed on all women (N = 7458) attending six family practice offices for a health maintenance examination from August 1989 through February 1991. Cytologic specimens were obtained using an endocervical Cytobrush and wooden spatula. Consenting subjects with cervical atypia underwent repeat Pap smear testing immediately before a colposcopic examination after a 4- to 6-month waiting period.

**Results.** One hundred fifty-nine women identified as

having cervical atypia consented to having a colposcopic examination. Of these, 96 (60%) demonstrated abnormalities on biopsy, including 40 with condyloma, 41 with CIN I, and 15 with CIN II to III. The false-negative rate of the follow-up Pap smear for detecting these cases of condyloma and CIN was 57%.

**Conclusions.** One third of the women with cervical atypia identified on an initial Pap smear in this primary care community setting had CIN after colposcopic biopsy. The single follow-up Pap smear obtained with the endocervical Cytobrush and wooden spatula failed to detect one half of the cases of biopsy-proven CIN. Further studies regarding the use of additional screening methods for follow-up are necessary.

**Key words.** Cervical atypia; cervical intraepithelial neoplasia; Papanicolaou smear.

*J Fam Pract* 1993; 36:289-293.

The presence of cervical atypia on the Papanicolaou (Pap) smear is common yet problematic. Reported incidence rates range from 4 to 6 cases per 100 patients per year.<sup>1-3</sup> Recent investigators report, however, steadily increasing incidence rates.<sup>4</sup>

Although usually a benign finding, cervical atypia may represent the presence of more severe disease. Several investigators have described colposcopic findings in subjects with cervical atypia on Pap smear.<sup>1-7</sup> In general, 20% to 35% of these women have cervical intraepithelial

neoplasia (CIN) on biopsy. The remaining women have either persistent atypia or no abnormality at all. In addition, repeat Papanicolaou smears fail to detect any abnormality, including atypia, in over 10% of women found by colposcopic biopsy to have CIN. For these reasons, many investigators recommend colposcopy for all women identified with cervical atypia.<sup>1,3,6,7</sup>

These data may be misleading, however, for two reasons. First, women with cervical atypia who are at increased risk of CIN or cervical cancer are more likely to be referred for colposcopy. Such women include smokers, and those who have a history of multiple sexual partners, other sexually transmitted diseases, prior cervical disease, or persistent cervical atypia. The incidence of undetected CIN in a referred population might therefore be higher than in the unscreened, primary care setting.

Second, all previous reports used the cotton-tipped swab and the wooden spatula to obtain the Pap smear.

\*HARNET denotes Harrisburg Area Research Network. For a list of members, see the Acknowledgment.

Submitted, revised, November 16, 1992.

From the Department of Family Practice, Harrisburg Hospital, Harrisburg, Pennsylvania, and the Department of Family and Community Medicine, Milton S. Ebersole Medical Center, Pennsylvania State University, Hershey. Requests for reprints should be addressed to David C. Slawson, MD, 205 S Front St, Harrisburg, PA 17105.

Recent studies of cytologic smears obtained with the Cytobrush have demonstrated improved recovery of endocervical cells.<sup>8-10</sup> No additional reports have indicated whether the initial or follow-up Pap smear obtained using the Cytobrush can more accurately predict which women with cervical atypia are at an increased risk of more significant disease.

Earlier reports may also overestimate the risk of undetected CIN among women with atypia because of a relatively recent change in the cytologic diagnosis system. Previously, evidence of a human papillomavirus (HPV) infection without dysplasia was reported as koilocytotic atypia. Atypical cytologic findings consistent with HPV infections are associated with a higher risk of progression to CIN.<sup>11</sup> Under the current Bethesda System, similar cytology findings are now reported as low-grade squamous intraepithelial lesions (SIL). The risk in women with cervical atypia and no evidence of an HPV infection or dysplasia, now called *atypia of undetermined significance*, is uncertain.

We wished to determine (1) the prevalence of undetected CIN among women in primary care settings with a Pap smear showing atypia of undetermined significance, and (2) the accuracy of a single follow-up Pap smear performed with an endocervical Cytobrush and a wooden spatula in identifying those women subsequently found to have biopsy-proven CIN.

## Methods

The Harrisburg Area Research Network (HARNET) consists of six practices in the Harrisburg metropolitan area. Two practices are training sites for a family practice residency program. The remaining four are private practices. HARNET's patient population includes persons living in urban, suburban, and semirural areas.

All women (N = 7458) who had Pap smears performed in HARNET offices from August 1989 to February 1991 were eligible for entry into the study. Exclusion criteria included pregnancy; history of atypia, squamous intraepithelial lesions (SIL), or invasive cervical cancer; age over 45 years; and prior treatment of the cervix, including cryotherapy, laser vaporization, or cone biopsy.

A Pap smear was obtained from each subject by sampling the endocervix with a Cytobrush and scraping the ectocervix with a wooden spatula. Slides made from these preparations were immediately fixed with ethanol. A cytologic evaluation was performed by a qualified cytotechnologist, and abnormal smears were reviewed by a board-certified pathologist at either SmithKline Bio-Science Laboratory (Philadelphia) or Harrisburg Hospi-

tal. Neither cytology laboratory personnel nor the pathologists were aware that a study was being conducted.

Women whose Pap smears showed SIL underwent immediate colposcopy. Consenting subjects with a Pap smear on which atypia of undetermined significance was found underwent colposcopy after a 4- to 6-month waiting period. Subjects with koilocytotic atypia were reclassified as having low-grade SIL in accordance with the Bethesda System for cytologic reporting. All suspected infections were appropriately treated. A repeat Pap smear was performed immediately before colposcopy on all consenting women with cervical atypia.

Colposcopy and directed biopsies were performed by clinicians with training and certification in performing colposcopic technique. Endocervical curettage was performed on all subjects. Colposcopic biopsies were reviewed by board-certified pathologists at Harrisburg Hospital who were not informed of the research protocol.

Sensitivity, specificity, predictive values, and their associated confidence intervals were calculated using standard techniques.

## Results

The mean age of the women was 25 years (range 15 to 45 years). Of the 7458 women who had initial cytologic screening, 442 (6%) had a Pap smear demonstrating atypia of undetermined significance (Figure). Of these, 207 were ineligible and did not undergo colposcopy. One hundred four of the ineligible women were over 45 years of age, 54 had a history of cryotherapy, 41 had a history of either atypia or SIL, and 8 were pregnant. Seventy-six women refused colposcopy or were lost to follow-up. Subjects accepting and refusing colposcopy were compared. There were no statistically significant differences between these groups with respect to age or race/ethnicity.

The 159 remaining subjects agreed to colposcopy. Of these, 37 women requested colposcopy without further delay. Abnormalities were found on biopsies in 29 (78%) of these 37 women, including 14 with condyloma and 15 with CIN I. One hundred twenty-one women agreed to wait 4 to 6 months for a follow-up Pap smear before undergoing a colposcopic examination. Abnormalities were found on biopsies in 67 (55%) of these 121 women, including 26 with condyloma, 26 with CIN I, and 15 with CIN II to III.

In summary, 96 (60%) of the 159 women with cervical atypia who consented to colposcopy had condyloma or CIN on biopsy. The 56 cases of CIN represented

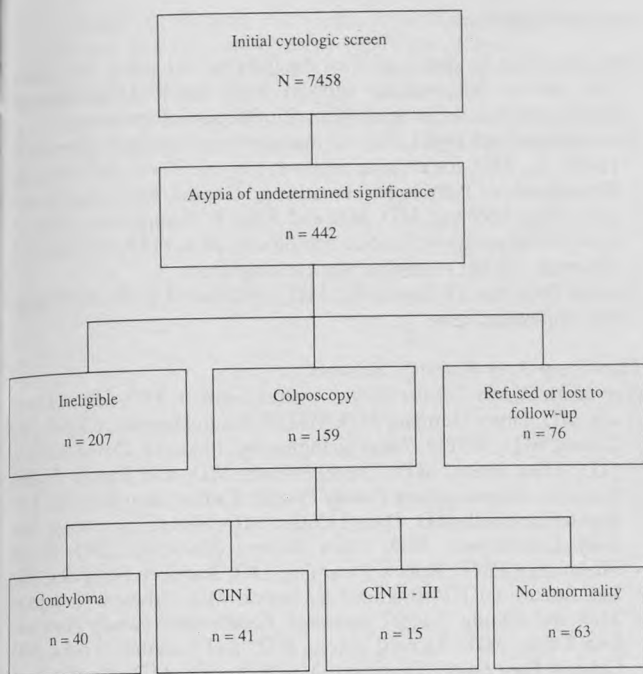


Diagram of research architecture for a sample of 7458 women who had a screening Pap smear test (August 1989 through February 1991).

35% of the 159 women with cervical atypia who consented to colposcopy.

No difference was found when comparing the rate of undetected condyloma or CIN in the two residency practice sites in an urban and semirural setting (60%) with the rate in the four private practice sites in suburban and semirural settings (60%).

Of the 121 women who agreed to wait 4 to 6 months for a follow-up Pap smear, 75 had a follow-up Pap smear that showed neither atypia nor SIL (Table 1). Abnormalities were found on biopsies in 38 (51%) of these 75 women, including 17 with condyloma, 16 with CIN I, and 5 with CIN II to III. Forty-six women had a follow-up Pap smear that showed either persistent atypia

Table 1. Colposcopic Results Categorized by Follow-up Pap Findings (n = 121)

Colposcopic Biopsy Results	Follow-up Pap Smear	
	Negative* (n = 75)	Abnormal† (n = 46)
Condyloma	17	9
CIN I	16	10
CIN II-III	5	10
Total abnormal biopsies	38 (51%)	29 (63%)

\*No atypia or squamous intraepithelial lesion.  
 †Atypia or squamous intraepithelial lesion present.  
 CIN denotes cervical intraepithelial neoplasia.

Table 2. Detection Accuracy for CIN or Condyloma of a Single Follow-up Pap Smear (95% CI)

Sensitivity	.43	(.31 - .55)
Specificity	.69	(.56 - .81)
Positive predictive value	.63	(.49 - .77)
Negative predictive value	.49	(.38 - .61)

CIN denotes cervical intraepithelial neoplasia.

or SIL. Abnormalities were found on biopsies in 29 (63%) of these 46 women, including 9 with condyloma, 10 with CIN I, and 10 with CIN II to III. Sensitivity, specificity, predictive values, and their associated confidence intervals for the follow-up Pap smear are noted in Table 2.

## Discussion

Sixty percent of the women in this study whose screening Pap smear demonstrated atypia of undetermined significance were found to have condyloma or CIN after colposcopy. The prevalence of CIN (35%) among this group of women in a primary care setting is comparable to previous reports.<sup>1-7</sup> This was true despite selecting a low-risk group by excluding women with a prior history of atypia or any other cervical disease. The false-negative rate of a single follow-up Pap smear performed with an endocervical Cytobrush and a wooden spatula after a 4- to 6-month waiting period is 57%.

If clinicians participating in the study were more likely to enroll women at higher risk of CIN, or if women who considered themselves to be at high risk were more likely to consent to colposcopy, selection bias might have caused an overestimation of risk. In our study women who requested colposcopy without further delay had a higher rate of abnormal biopsies. Presumably, these women were uncomfortable with any further delay in evaluation and treatment. If it is assumed, however, that all 76 eligible but nonconsenting subjects had a normal colposcopic examination, the rate of occurrence of condyloma or CIN would be 40%, and the prevalence of CIN would be 23%. These results would still be consistent with published data.

A study site consisting of women at significantly increased risk compared with other sites could skew the overall result. However, we did not find such differences among our sites.

Finally, an unusually high prevalence of cervical disease in our sample population could also bias the results. The overall prevalence of atypia in our population (6%) is comparable to that reported elsewhere.<sup>1-3</sup> In

addition, as reported earlier, the prevalence of CIN (3%) in our population is comparable to national reports.<sup>12</sup>

Failure of the follow-up Pap smear to identify 21 cases of CIN, including one third of the high-grade lesions, is disturbing. Many clinicians may be falsely reassured by a negative report. Thus, they may not pursue further work-up of the patient or counsel about smoking cessation, safe sex practices, or additional follow-up.

The 1991 Bethesda workshop further clarifies atypia of undetermined significance by emphasizing the responsibility of the cytopathologist to note whether a reactive or a premalignant or malignant process is present.<sup>13</sup> Further work investigating whether this addition to the cytologic evaluation will accurately predict those women at risk for undetected CIN is important.

The majority of women identified with cervical atypia had relatively benign lesions on colposcopic biopsy (condyloma or CIN I). Controversy exists regarding the management of these patients. Some authors recommend surveillance with repeat cytologic testing or colposcopy, while others recommend immediate treatment.<sup>14-18</sup> In our study, no women in the group requesting colposcopy without further delay were found to have CIN II to III, while 15 women in the group who waited 4 to 6 months for colposcopy were identified with CIN II to III. These results suggest that cervical disease may have progressed during this waiting period. Alternatively, the higher rate of abnormal biopsies in the first group (colposcopy without delay) may indicate that normal reparative healing was not allowed to occur. Colposcopy was not performed both initially and after a 4- to 6-month waiting period on all women. Describing the natural history of cervical atypia was therefore not possible. Future studies performed in the primary care setting that evaluate the progression or regression of cervical atypia will be important.

Evaluation of additional screening methods such as cervicography, speculoscopy, HPV DNase probe testing, and a naked-eye examination after an acetic acid wash may improve reliability for identifying CIN in women with cervical atypia. Until these methods are adequately evaluated with randomized, controlled trials, careful follow-up of women with cervical atypia is warranted.

We currently recommend colposcopy for all women identified with atypia of undetermined significance. For those women who initially refuse further evaluation, we recommend repeat cytologic examinations at 4- to 6-month intervals for 1 to 2 years. Colposcopy is recommended after any additional abnormal cytologic results.

## Acknowledgments

This study was funded in part by the George L. Lavery Foundation. The authors acknowledge support from International Cytobrush Incorporated and the SmithKline BioScience Laboratories. The authors thank Gail Leduc for manuscript preparation; Kenneth R. Harm, Jr., MD, for creative support; Him G. Kwee, MD, from the Department of Pathology, Harrisburg Hospital, for laboratory support; Alan Adelman, MD, MS, and Allen F. Shaughnessy, PharmD, for editorial assistance; and Judith Blouch, MA, HARNET Research Assistant, for her expert network management. The late Frederick D. Curcio III, MD, contributed to the study design and implementation.

## Harrisburg Area Research Network

*Harrisburg Family Practice Center:* Joshua Bennett, MD, Ellen Gemini, MD, James Herman, MD, MSPH, Susan Herman, CRNP, Julie Larson, MD, MSPH, Allen Shaughnessy, PharmD, David Slawson, MD, Ellen Smith, MD, Daniel Weber, MD, and Family Practice residents. *Mechanicsburg Family Practice Center:* Ann Bogdan, MD, Karen Campbell, MD, Daniel Coller, MD, Shou Ling Leong, MD, Gary Luttermoser, MD, Paula Scheetz Mackrides, DO, Pamela McAnich, CRNP, Robert Muscalus, DO, Kathleen Sempeles, MD, Lisa Stokes, CRNP, Bradford K. Strock, MD, Edward Thompson, MD, and Family Practice residents. *Cumberland Family Physicians:* Lisa Davis, MD, Richard Davis, MD, and Jonathan Tocks, MD. *Colonial Park Family Physicians:* Megan Borrer, MD, Monika Garg, MD, and Kevin Kelly, MD. *Good Hope Family Physicians:* Michael Gawlas, DO, Kenneth Harm, MD, Jane Rowehl, MD, Michael Riggleman, MD, and Cathleen Sangillo, MD. *Shepherdstown Family Practice:* Elizabeth Alwine, CRNP, Janet Cincotta, MD, Joseph Cincotta, MD, Geoffrey James, MD, and Gary Schwartz, MD.

## References

- Maier RC, Schultenour SJ. Evaluation of the atypical squamous cell Papanicolaou smear. *Int J Gynecol Pathol* 1986; 5:242-8.
- Davis GL, Hernandez E, Davis JL, Miyazawa K. Atypical squamous cells in Papanicolaou smears. *Obstet Gynecol* 1987; 69:43-6.
- Numoff JS. Atypia in cervical cytology as a risk factor for intraepithelial neoplasia. *Am J Obstet Gynecol* 1987; 156:628-31.
- August N. Cervicography for evaluating the "atypical" Papanicolaou smear. *J Reprod Med* 1991; 36:89-94.
- Soutter WP, Wisdom S, Brough AK, Monaghan JM. Should patients with mild atypia in a cervical smear be referred for colposcopy? *Br J Obstet Gynaecol* 1986; 93:70-4.
- Reiter RC. Management of initial atypical cervical cytology: a randomized, prospective study. *Obstet Gynecol* 1986; 68:237-40.
- Shaw CT. Colposcopic examination of patients with class II Papanicolaou smears. *J Am Osteopath Assoc* 1986; 86:355-9.
- Reissman S. Comparison of two Papanicolaou smear techniques in a family practice setting. *J Fam Pract* 1988; 26:525-9.
- Deckert J, Staten SF, Palermo V. Improved endocervical cell yield with the Cytobrush. *J Fam Pract* 1988; 26:639-41.
- Sheehan J. Evaluation and comparison of the spatula, the Cytobrush, and the cotton swab in the collection of endocervical cells and atypical cells in cervical smears. *Am J Clin Pathol* 1988; 89:436.
- Mitchell H, Drake M, Medly G. Prospective evaluation of the risk of cervical cancer after cytological evaluation of human papilloma virus infection. *Lancet* 1986; 1:573-5.
- Slawson DC, Bennett JH, Herman JM. Are Papanicolaou smears enough? Acetic acid washes of the cervix as adjunctive therapy: a HARNET study. *J Fam Pract* 1992; 35:271-7.
- Broder S. Rapid communication—The Bethesda System for reporting cervical/vaginal cytologic diagnoses—report of the 1991 Bethesda workshop. *JAMA* 1992; 267:1892.

14. Carmichael JA, Maskens PD. Cervical dysplasia and human papillomavirus. *Am J Obstet Gynecol* 1989; 160:916-8.
15. Walker P, Singer A. Colposcopy: who, when, where, and by whom? *Br J Obstet Gynaecol* 1987; 94:1011-3.
16. Richart RM, Barron BA. A follow-up study of patients with cervical dysplasia. *Am J Obstet Gynecol* 1969; 105:386-93.
17. Campion MJ, McCance DJ, Cuzick J, Singer A. Progressive potential of mild cervical atypia; cytological, colposcopic, and virologic study. *Lancet* 1986; 2:237-40.
18. Nasiell K, Roger V, Nasiell M. Behavior of mild cervical dysplasia during long-term follow-up. *Obstet Gynecol* 1986; 67:665-9.