

Vas Deferens Occlusion During No-Scalpel Vasectomy

Ronald D. Reynolds, MD

New Richmond, Ohio

The increasing popularity of the no-scalpel vasectomy (NSV) technique in the United States is driven by patient demand for surgical procedures presumed to be less invasive and by the somewhat lower complication rate of the NSV technique. The NSV technique addresses vasal delivery but not vasal occlusion. Intraluminal red-hot wire cautery with sheath closure over the inguinal end of the cut vas (Schmidt's method) has the lowest failure rate of all reasonable vas occlusion methods. The anatomical relationships of scrotal layers can be unclear during the NSV technique. Accurate identification of the sheath layer is critical to sheath interruption if this

method of occlusion is to be used. Placement of an absorbable purse-string suture for sheath interruption during the NSV procedure is described. Special attention must be given to placement of one suture bite in the deep (posterior) sheath wall. The vasal occlusion technique described in this paper blends a refined method of vasal delivery (NSV) with the most effective method of vasal occlusion (cautery with sheath interruption).

Key words. Vasectomy; no-scalpel vasectomy; vas deferens occlusion; cautery; sheath interruption.
(*J Fam Pract* 1994; 39:577-582)

The no-scalpel vasectomy (NSV) technique was developed in 1974 by Shunqiang Li, MD, of Sichuan Province, China.¹ Eight million NSV procedures were performed on Chinese men between 1974 and 1988.² The technique was unknown to physicians in the West until 1985, when a group of visiting physicians from the New York-based Association for Voluntary Surgical Contraception (AVSC) serendipitously viewed the procedure. Vasectomists in the United States have been learning the technique since 1988, when the AVSC began offering training seminars. The NSV technique is rapidly gaining popularity among both surgeons and patients.

The NSV technique is a refined method of delivering a loop of vas deferens (vas) outside the scrotal skin. A ring-tipped skin-fixation clamp firmly affixes the vas to the skin in the midline of the anterior upper third of the scrotum. A sharpened, curved dissecting forceps punctures the skin and stretches open a tract from the skin through all the intervening tissues to the vas. The vas is then skewered with the dissector and lifted through the

skin opening. Advantages of the NSV technique include shorter operative time, less tissue injury, less postoperative swelling and pain, and a lower complication rate.^{1,2}

The NSV technique, however, does not address vasal occlusion once the vas is delivered. Numerous methods of vasal occlusion have been attempted. Denniston³ has extensively reviewed failure rates after all known occlusion methods. Simple transection and simple ligature without division are associated with too high a failure rate to be used as the sole method of occlusion.³ Removal of a 4-cm length of vas has a 100% success rate but involves extensive operative dissection, increases the chance of bleeding and postoperative pain, and is not amenable to later vasovasostomy.³

Division of the vas with ligatures around each end, which is the most commonly used occlusion method, results in failure approximately 1.5% of the time.³ Ligatures around the vas cause ischemia of its muscular wall, which may lead to transmural necrosis and sloughing of tissue distal to the ligature. Subsequent sperm leakage increases the potential for granuloma formation and spontaneous recanalization.⁴ Moss³ has replaced ligatures with one or two metal clips across the vas for occlusion. His failure rate was 1.2% with one clip and 0% with two clips.

Submitted, revised, September 26, 1994.

From New Richmond Family Practice, New Richmond, Ohio. Requests for reprints should be addressed to Ronald D. Reynolds, MD, New Richmond Family Practice, 1050 Old U.S. 52, New Richmond, OH 45157.

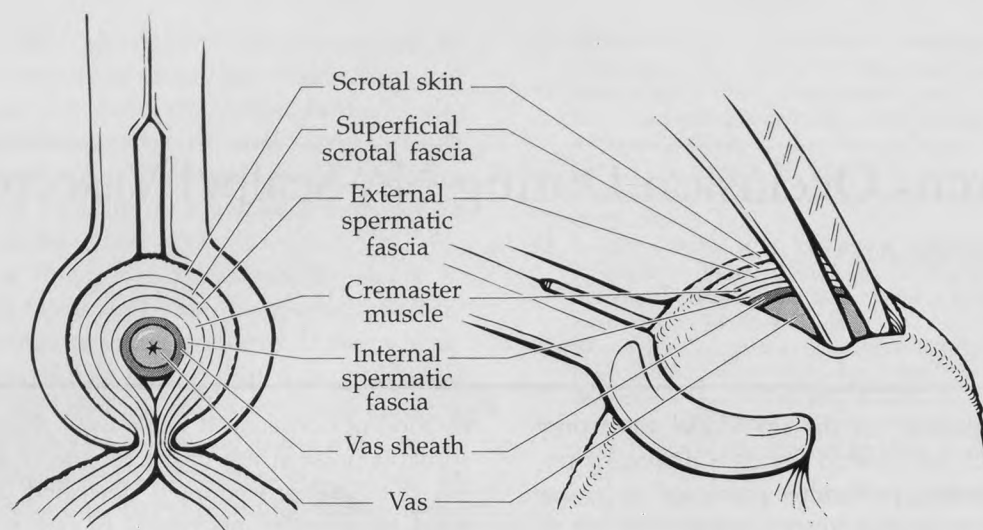


Figure 1. Detail of scrotal tissue layers during no-scalpel dissection. Drawings reproduced with permission of Jef Dirig.

Many vasectomists, including Moss, have adopted Schmidt's intraluminal cautery as the preferred method of vasal occlusion.³⁻⁵ According to Schmidt, leakage of sperm into the scrotal tissues causes spermatic granuloma.⁴ Epithelialized tubules within the granuloma can bridge the gap between the cut ends and effectively recanalize the vas. Schmidt found the rate of spermatic granuloma to be lowest when using cautery to seal the vas.^{4,5} The cautery tip is inserted into the vasal lumen and gradually withdrawn while the instrument is activated. This provides varying degrees of mucosal and muscular necrosis. In principle, there will be some point along the cauterized vas where sufficient scarring will completely occlude the lumen.

Schmidt initially used *electrocautery* but later demonstrated in an elegant pathological study that red-hot wire cautery provides superior results.⁶ Apparently, intraluminal hot cautery causes a third-degree burn of the vasal mucosa, inciting fibroblastic scarring that closes the vasal lumen. In contrast, electrocautery energy follows the path of least resistance and may at times spark through the vasal wall, creating a necrotic perforation that may not be obvious intraoperatively.⁶

In 1924, Rolnick⁷ reported that the canine vas can regenerate over long distances by endothelialization of its sheath. Strode⁸ first noted that interruption of the continuity of the sheath is critical to successful vasal occlusion. If the sheath is not interrupted, it can act as a conduit between the two cut ends of the vas, leading to spontaneous recanalization. Building on this knowledge, Schmidt developed a method of vasal occlusion that blends intraluminal cautery with interruption of the sheath. A purse-string suture closes the sheath over the

inguinal side of the vasal transection.⁵ Many vasectomists have adopted Schmidt's method of vasal occlusion. Schmidt has reported having no failures in 5000 cases using this method.⁹ Esho and Cass¹⁰ have had no failures in 820 cases, and Denniston³ has had a 0.25% failure rate in 2500 cases.

As an AVSC instructor in no-scalpel vasectomy, I have had the unique opportunity to closely observe many vasectomists' occlusion techniques. It is my perception that often little thought is given to what will occur at the operative site once it is replaced in the scrotum and the vas no longer forms an extracutaneous loop. For instance, efforts to secure the testicular end outside the sheath may result in the end either simply pulling back into the sheath or becoming strangulated and necrosing. It is also quite common for vasectomists to unwittingly use tissue layers other than the sheath to cover the inguinal end of the vas. The sheath is not interrupted by these attempts, although it may appear so while viewing the extracutaneous vasal loop.

Careful study of the mechanism of vasal delivery during NSV shows that a loop of vas with its attached sheath is drawn out of a hole through the scrotal layers. As shown in Figure 1, these layers include the skin, superficial scrotal fascia, external spermatic fascia, cremaster muscle, and internal spermatic fascia. These scrotal tissue layers bunch up and surround the loop of vas just above the level of the skin, potentially confusing the vasectomist. Figure 2 shows how the layers appear distorted during vasal delivery.

In NSV dissection all the scrotal layers are opened to the vas. However, the sheath is an adventitial covering of the vas and is tightly adherent to it.¹¹ The loop of vas that

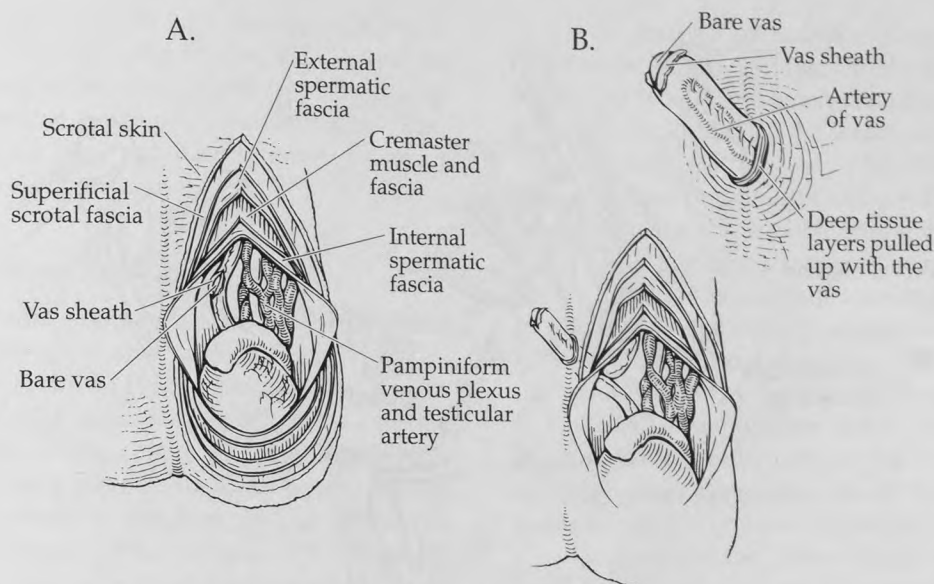


Figure 2. Scrotal layers as they relate to no-scalpel vasectomy. (A) Reflected tissue planes in the natural state are shown. (B) These tissue layers are all pulled out of the NSV dissection site to various degrees. Drawings reproduced with permission of Jef Dirig.

is delivered is mostly covered by attached sheath and is bare only at the apex. It may be helpful to visualize the native vas with its attached sheath as being a straight copper wire surrounded by plastic insulation. If a loop of this insulated wire is pulled up through a hole and the apex of the resulting wire loop has its insulation slit open, this schematizes NSV surgical anatomy.

The no-scalpel vasectomist must positively identify and accurately expose the sheath layer to accomplish appropriate sheath interruption. If other scrotal layers that appear distorted by the dissection are incorrectly assumed to be the sheath, the critical step of sheath interruption will not be accomplished. When this occurs, it is possible that enough postoperative inflammation will develop in the operative area to produce scarring that effectively closes the sheath. If so, the patient will not suffer the repercussions of a nonanatomical operation. In some cases, however, recanalizations occur because the vasectomist does not pay close enough attention to anatomical sheath interruption.

Further, if the more superficial layers, such as the external spermatic fascia, are incorporated during sheath interruption, the vas may become trapped in the wrong tissue layer. This complication has the potential to cause recurrent visceral pain from vasal traction every time the scrotum elongates.

There is no literature addressing the anatomical details of accurate sheath obliteration. All articles that mention sheath closure or "fascial interposition" assume that

readers will intuitively know how to close the sheath. My experience suggests that this is an erroneous assumption. I therefore suggest the following method of vasal occlusion and accurate anatomical sheath interruption during NSV.

Operative Technique

Preparatory Steps

A loop of vas is delivered through a skin puncture by the usual NSV technique. Its apex is held firmly by fully encircling the vas with the ring forceps rather than by grasping it with the tips of the ring. To ensure that there is no tamponade of the loop by the skin or tissue layers, the artery of the vas is identified before proceeding. If the artery of the vas cannot be identified, a curved extra-delicate mosquito hemostat (eg, Miltex 7-10, Miltex Instrument Co, Inc, Lake Success, NY) is used to further stretch the constricting skin or tissue layers or both. If this brief precaution is taken, all subsequent bleeders will be readily identified intraoperatively, potentially reducing the hematoma rate.

At this point, usual NSV technique employs the dissecting forceps to sharply puncture through the tissue under the apex of the loop in the vas, then strip away the attached tissue layers by opening the tips. Using this method, it may be difficult to identify the sheath layer.

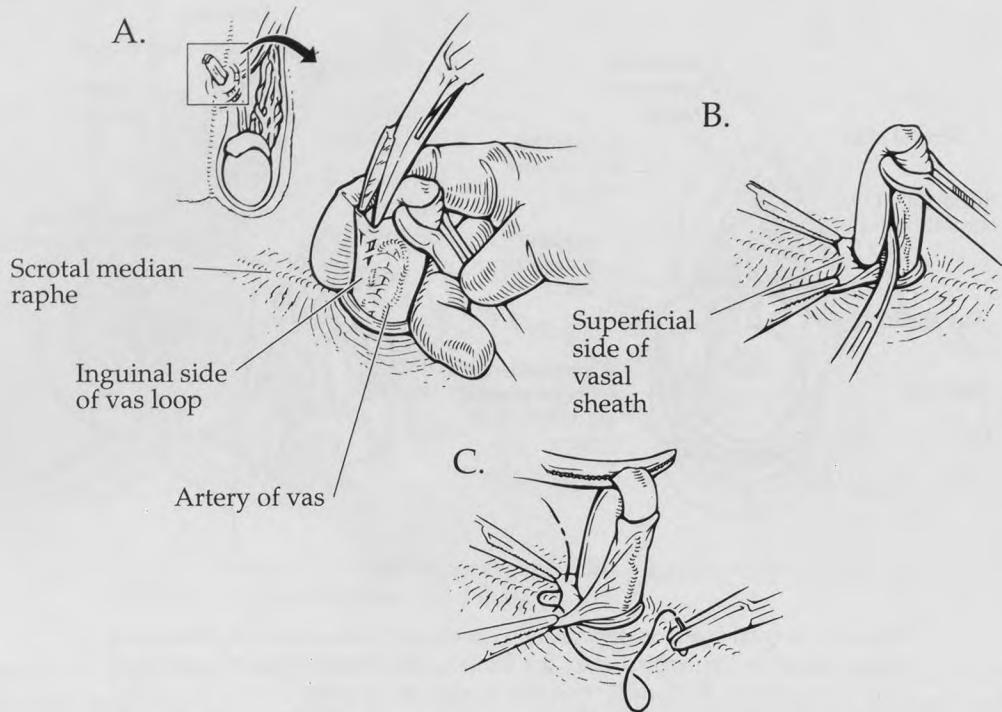


Figure 3. Exposure of the anterior sheath layer. (A) A dissecting forceps frees the anterior (initially most superficial) sheath from the vas. This layer is grasped with two straight extra-delicate mosquito hemostats. (B) The posterior (initially deepest) sheath is stripped off the vas. (C) Using 5-O Vicryl on a taper-point needle, the first two bites of sheath interruption triangulation are placed. Drawings reproduced with permission of Jef Dirig.

Therefore, careful sheath layer identification is the next recommended step.

Accurate Sheath Identification and Dissection

The NSV dissecting forceps is used to dissect the adherent delicate sheath off the loop of vas in the inguinal direction. As shown in Figure 3A, the initially most superficial (anterior) side of the sheath at the top of the loop has often already been opened during vasal delivery. If not, the usual single-blade puncture and double-blade stretch of the NSV technique are used to open the sheath at the apex of the vasal loop. The closed tips of the dissecting forceps are carefully advanced in the plane between the sheath and bare vas. The tips are then spread slightly to free the anterior sheath from the vas.

The delicate sheath layer is then grasped at the 10 and 2 o'clock positions (considering a horizontal plane through the vertical inguinal side of the vasal loop, with the patient's head at 12 o'clock) with the tips of two straight extra-delicate mosquito hemostats (eg, Miltex 7-8). Loupe magnification is not a necessity, but it may aid visualization of this process.

An extra-delicate curved mosquito hemostat (eg,

Miltex 7-10) is next used to bluntly dissect around the vas. This opens the tissue plane between the bare vas and the initially deepest (posterior) side of the sheath that is still adherent to it (Figure 3B). The closed hemostat tips are placed at the 9-o'clock position in the plane between the sheath and vas. A curving open-close motion is used to bluntly dissect along the vas-sheath plane between the 9 and 3 o'clock positions. The hemostat tips are then opened widely to strip the inguinal side of the vas loop bare of its sheath.

The curved mosquito hemostat is then applied across the vas at the apex of the loop to secure the vas. The ring forceps is removed.

Clips vs Suture for Sheath Interruption

Many NSV practitioners have adopted the use of metal clips for sheath interruption. I have tried them but find them unsatisfactory for two reasons. First, I find it difficult to apply clips accurately to anatomically close the sheath without involving other tissue layers. Second, the clips tend to hang up on superficial tissue layers in the dissection tract as the vas is being replaced into the scrotum,

potentially resulting in chronic pain. If excessive manipulation is used to free the hung-up vas, the clip may be dislodged, resulting in loss of sheath interruption. Recognizing these potential problems, I have become disenchanted with metal clips and have returned to suture technique for sheath interruption.

Sheath Purse-string Suture Placement

A purse-string suture to close the sheath is placed in two separate steps; 5-0 Vicryl on a small taper-point (gastrointestinal) needle (Ethicon J433H, Ethicon, Inc, Somerville, NJ) is used. The taper-point needle has no cutting surfaces along the needle's curve that might slit open a blood vessel if a bite is taken immediately next to it. Bites are placed in the anterior sheath at the tips of the two mosquito hemostats, as shown in Figure 3C. The needle is then reloaded in the needle holder backwards (with the tip pointing away from the vasectomist) and put down while intraluminal cautery is done.

Cautery and Transection

The vas is hemi-transected in two places using blunt-tipped Steven's tenotomy scissors, allowing access to the lumen without losing control of the vas. One hemi-transection site is immediately to the testicular side of the curved mosquito hemostat that holds the apex of the loop. Sometimes an opening in the wall of the vas was created here by vasal delivery and can be used for this "hemi-transection." The second hemi-transection site is to the inguinal side of the hemostat, slightly above the level of the suture in the sheath. Five millimeters of intraluminal hot cautery is applied at each hemi-transection site (in the inguinal direction at the inguinal site and in the testicular direction at the testicular site). Care is taken to keep the hot cautery tip away from gauze pads, which are flammable.¹² The inguinal transection is then completed.

The Critical Third Suture Bite

After complete transection, the inguinal end of the vas will usually retract slightly, just dropping into its surrounding sheath. Gentle traction on the testicular vas, accomplished by clockwise rotating and lifting the curved mosquito hemostat that has been at the apex, will now identify critical sheath anatomy. The edges of the original opening in the anterior side of the sheath will rise as delicate tissue layers on each side of the field. They course between the tips of the straight mosquito hemostats and go around behind the testicular vas as shown in Figure 4A. Returning to the wire analogy, these layers are represented by the edges of the slit in the insulation at the apex of the loop.

If the final suture bites are placed in these anterior edges of the sheath opening, the sheath will not be interrupted. To do so would simply close the hole in the anterior side of the sheath, sealing the sheath closed but not obliterating its continuity. The author has observed vasectomists placing metal clips across this anterior sheath opening, erroneously thinking they are obliterating sheath continuity.

To properly close the sheath over the inguinal end of the vas and obliterate sheath continuity, the third suture bite must be placed in the posterior sheath. The posterior sheath is identified as a glistening surface in the bottom of the hollow formed by the anterior sheath edges. As shown in Figure 4A, the posterior sheath courses between the inguinal and testicular ends of the vas. To use the wire analogy again, the posterior sheath is represented by the insulation on the opposite side of the wire from the slit.

To complete the purse-string suture placement, a small segment of the posterior sheath is grasped with an Adson dressing forceps and lifted up slightly. The third and final bite is placed at the tip of the forceps. Care is taken to avoid the artery of the vas and other vascular structures that are close to the sheath in this area.

The purse-string suture will now interrupt sheath continuity by pulling the anterior sheath down onto the posterior sheath as shown in Figure 4B. After the straight mosquito hemostats are removed from the anterior sheath, the purse-string suture is tied and "tagged" with a hemostat.

Completion of the Operation

Transection is completed at the testicular hemi-transection site. The 5-mm to 7-mm segment of vas, a portion of which has been crushed and devitalized by the curved mosquito hemostat, is discarded (Figure 4C). Leaving this portion of vas in place would result in tissue inflammation with subsequent pain and swelling. The vasectomist should leave all structures at the operative site with good blood supply.

The vasectomist then drops the operative site back through the skin briefly while holding the tagged suture. The vas is brought back up to make sure there is no bleeding. Close attention should be paid to the sheath edge surrounding the testicular end. It is the author's experience that most bleeding originates from this location. While traction is applied to the tagged suture, palpation to the left and right of the root of the penis is done. Feeling the tensed vas verifies that the correct side has been occluded. When it is certain that hemostasis has been accomplished, the tagged suture is cut (Figure 4D) and the operative site allowed to drop back into its original position in the scrotum.

To ensure that the vas returns to the proper layer of the scrotum, two maneuvers are performed. First, traction

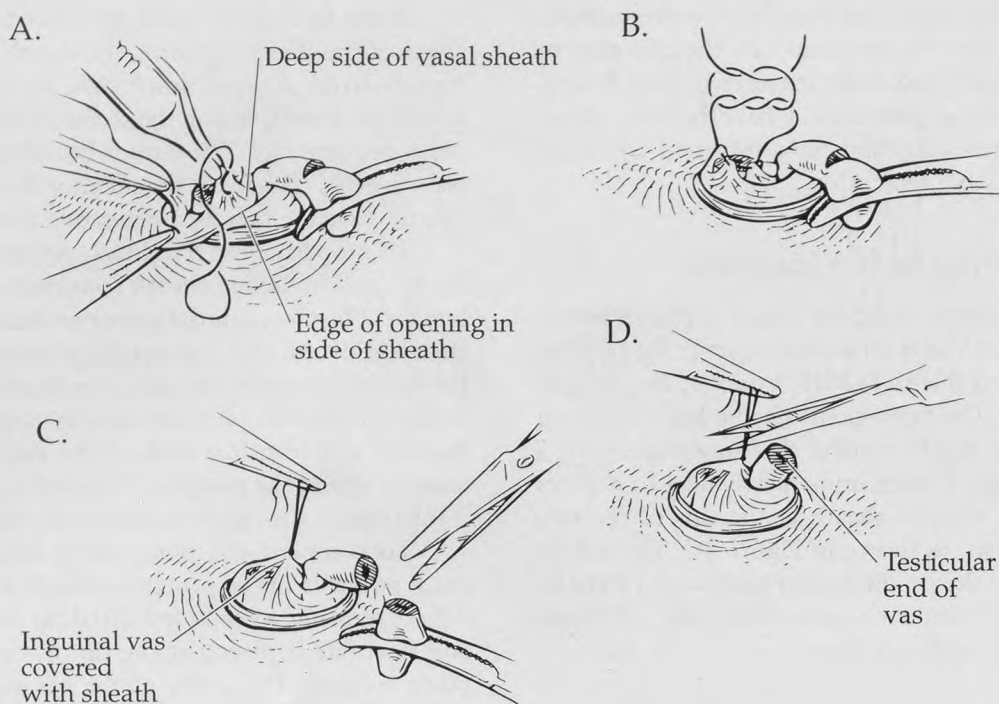


Figure 4. Completion of purse-string sheath interruption. Transection at the inguinal hemi-transection site has been completed. (A) Adson dressing forceps identify and lift the posterior sheath for placement of the third suture bite. (B) The purse-string suture is tied and "tagged" with a hemostat; (C) the vasal transection on the testicular side is completed; (D) the tagged suture is cut after inspection for hemostasis. Drawings reproduced with permission of Jef Dirig.

on the ipsilateral testis is applied. Second, the entire anterior wall of the scrotum is grasped between thumb and forefinger across the puncture site. This palpation ensures that the vas is free of the skin and scrotal septum.

Conclusions

The vasal occlusion method described blends the operative advantages of delivering the vas deferens by the no-scalpel vasectomy technique with the intraluminal cautery and sheath obliteration technique of vasal occlusion introduced by Schmidt.⁴ Accurate obliteration of sheath continuity can be accomplished using suture technique when anatomic details, particularly to the posterior sheath, receive close attention.

Acknowledgments

The author thanks Jef Dirig of Ohio State University in Columbus for superb illustrations; Melanie Slade of New Richmond Family Practice for transcription; and Tonya Hines of the University of Cincinnati and Todd Harper of Cincinnati for technical assistance.

References

1. Li S, Goldstein M, Zhu J, Huber D. The no-scalpel vasectomy. *J Urol* 1991; 145:341-4.
2. Goldstein M. Vasectomy and its reversal. *Hosp Med* 1989; Feb: 113-35.
3. Denniston GC. Vasectomy by electrocautery: outcomes in a series of 2500 patients. *J Fam Pract* 1985; 21:35-40.
4. Schmidt SS. Techniques and complications of elective vasectomy: the role of spermatic granuloma in spontaneous recanalization. *Fertil Steril* 1966; 17:467-82.
5. Schmidt SS. Prevention of failure in vasectomy. *J Urol* 1973; 109: 296-7.
6. Schmidt SS, Minckler TM. The vas after vasectomy: comparison of cauterization methods. *Urology* 1992; 40:468-70.
7. Rolnick HC. Regeneration of the vas deferens. *Arch Surg* 1924; 9:188-203.
8. Strode JE. A technique of vasectomy for sterilization. *J Urol* 1937; 37:733-6.
9. Schmidt SS. Vasectomy [editorial]. *JAMA* 1988; 259:3176.
10. Esho JO, Cass AS. Recanalization rate following methods of vasectomy using interposition of fascial sheath of vas deferens. *J Urol* 1978; 120:178-9.
11. Lipschultz LI, Benson GS. Vasectomy—1980. *Urol Clin North Am* 1980; 7:89-105.
12. Wood DK, Hollis R. Thermocautery causes gauze pad fire [letter]. *JAMA* 1993; 270:2299-300.