

## Colocutaneous Fistula as a Complication of PEG Tube Placement

Cliona Kilmartin, MD; Gregory L. Brotzman, MD; and Patrick Regan, MD

Milwaukee, Wisconsin

Individuals with prolonged swallowing difficulties may require enteral supplementation to maintain a healthy nutritional status. Until the advent of the percutaneous endoscopic gastrostomy (PEG) tube in 1980, feeding was usually accomplished by a nasogastric feeding tube. The initial insertion of a PEG tube requires endoscopic or radiologic guidance but has the advantages of being easy to care for and being a permanent or temporary ac-

cess site for enteral nutrition. Complications associated with PEG tube placement are relatively infrequent. We present a case of a percutaneous fistula as a rare complication associated with reinsertion of a PEG tube.

*Key words.* Enteral nutrition; percutaneous endoscopic gastrostomy tube; gastrostomy; fistula; cutaneous fistula; PEG. (*J Fam Pract* 1996; 43:76-78)

An increasing number of individuals with prolonged swallowing difficulties but an intact gut require enteral supplementation to maintain a healthy nutritional status.<sup>1</sup> Most of these patients required nasogastric tube feedings until the 1980 advent of the percutaneous endoscopic gastrostomy (PEG) tube.<sup>1</sup> Now this approach to enteral feedings is widely used: in 1993, there were 107,000 PEG tube placements reported in the United States.<sup>2</sup> Insertion of a PEG tube requires endoscopic guidance, but it offers the advantages of being easy to care for and being a permanent access site for enteral nutrition.<sup>3</sup> In the event of dislodgment, PEG tube replacement is generally uncomplicated but may warrant a repeat endoscopic procedure. The following case report describes a complication associated with nonendoscopic reinsertion of a PEG tube.

### Case Report

An 82-year-old woman had a PEG tube placed because of an inability to swallow related to severe Alzheimer's

dementia. The PEG tube had been functioning well until 1 week prior to admission when it began to leak through a crack on the outside of the cannula. The PEG tube was replaced in the outpatient department without apparent difficulty. Three days before admission, the patient experienced explosive diarrhea and feculent drainage through her PEG tube without associated fever, nausea, vomiting, or other systemic symptoms.

At the time of admission, the patient had stable vital signs. Mucous membranes were moist, and the abdomen was flat and nontender with hyperactive bowel sounds. The PEG tube was in place and was returning brown, foul-smelling fluid.

Gastrografin (meglumine diatrizoate) instilled through the PEG tube demonstrated that the PEG tube was located in the splenic flexure of the colon rather than in the stomach (Figures 1 and 2). There was no apparent free peritoneal leakage of contrast material. Esophagogastroduodenoscopy (EGD) demonstrated healing of the previous insertion site of the PEG tube on the greater curvature of the stomach. No feculent material was present within the stomach and there was no evidence of a gastrocolic fistula. The PEG tube was deflated and removed, and a No. 8 French feeding nasogastric tube was placed for nutritional support. The colocutaneous fistula healed spontaneously within 6 weeks.

Submitted, revised, March 22, 1996.

From Martin Luther King Heritage Health Center (C.K.), the Department of Family and Community Medicine, Medical College of Wisconsin (G.L.B.), and Columbia Hospital (P.R.), Milwaukee, Wisconsin. Requests for reprints should be addressed to Gregory L. Brotzman, MD, Columbia Family Care Center, 210 West Capitol Drive, Milwaukee, WI 53212. E-mail: [brotzman@post.its.mcw.edu](mailto:brotzman@post.its.mcw.edu)

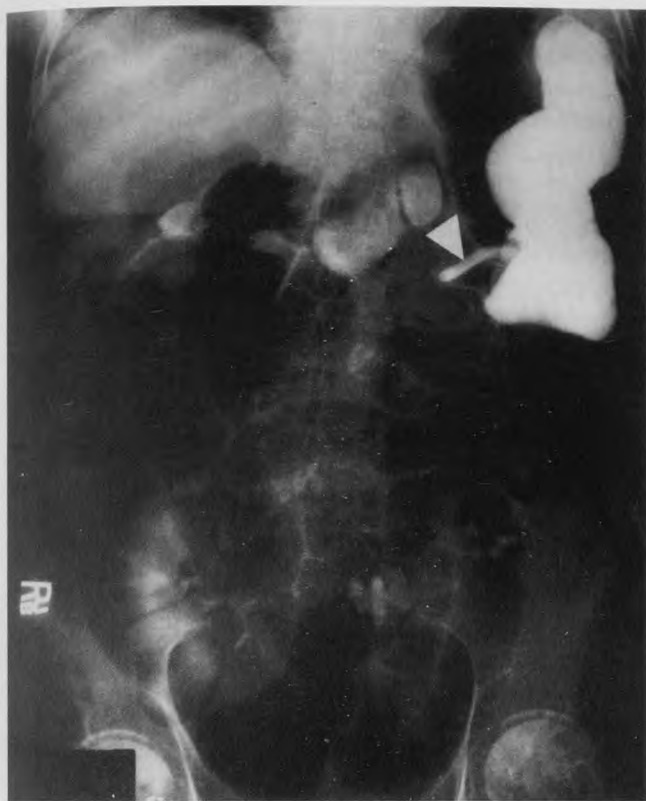

Figure 1. Radiographic study demonstrates filling of the colon rather than the stomach during instillation of Gastrografin. The PEG tube is indicated by the arrow.

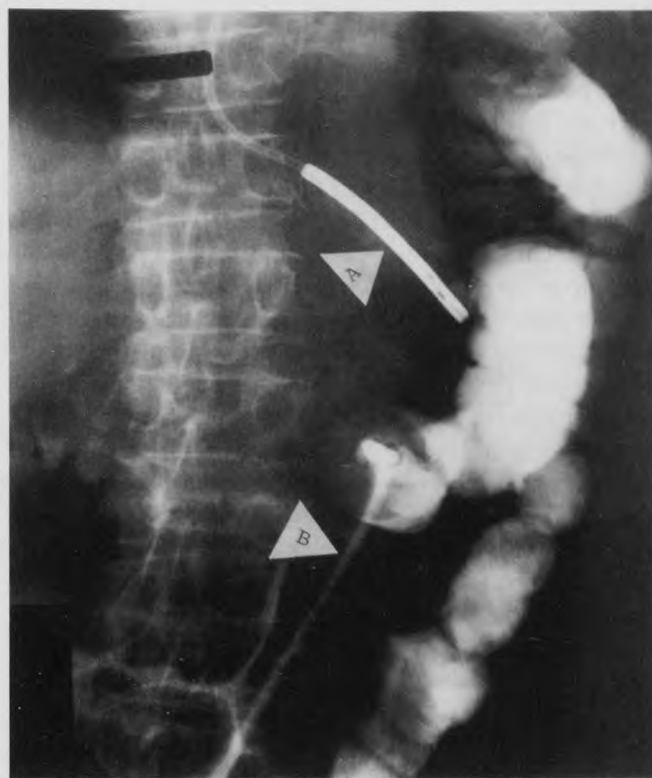


Figure 2. Nasogastric tube, indicated by arrow marked "A," is inserted in the stomach. PEG tube, indicated by arrow marked "B," is located on the colon. Gastrografin instilled through the PEG tube fills the colon rather than the stomach.

## Discussion

PEG tube placement is not without risk. Approximately 4% of patients experience major complications, such as gastric perforation, gastric bleeding, hematoma, aspiration, and death, and another 13% may experience relatively minor complications, such as wound infection, tube dislodgment, aspiration, stomal leak, fever, or ileus.<sup>4</sup> A percutaneous fistula is a rare complication of PEG tube placement.<sup>5,6</sup>

A previous case report described a colocolocutaneous fistula that developed 3 days after the PEG insertion. In this case, the PEG tube had been placed in the transverse colon.<sup>5</sup> At the time of laparotomy (10 days after the insertion procedure), no evidence of stomach wall puncture was noted, and there were no previous connections found between the stomach and the colon. Even when injury to the stomach occurs during EGD, resulting in a traumatic gastric perforation, the majority of these cases resolve spontaneously without the development of peritonitis and without evidence of gastric wall injury at laparotomy.<sup>5,7,8</sup>

A review of the literature revealed two cases similar to ours. The first one involved a PEG tube that was in place

for 8 months before becoming dislodged. In this case, the tube was promptly reinserted, followed by the development of profuse diarrhea.<sup>8</sup> The second report was of a case in which a PEG tube had been in place for 2 years when it was replaced. Following replacement, the PEG tube aspirate contained fecal material.<sup>7</sup> Both of these cases were considered to have represented long-standing cologastrocutaneous fistulae that remained asymptomatic until the PEG tubes were reinserted.

There is usually a 1- to 3-month delay between PEG tube placement and the onset of symptoms of a developing colocolocutaneous fistula.<sup>7</sup> During PEG tube placement, there may be unintentional perforation of the splenic flexure of the colon between the abdominal wall and the stomach.<sup>8</sup> The original tube is inserted through the colon into the stomach, but the replacement tube is advanced only as far as the colon.<sup>8</sup> The holes in the stomach and colon do not leak because the stomach is opposed to the colon and the colon is decompressed by the PEG tube.<sup>5</sup>

In a patient with a functioning PEG tube, development of feculent emesis and severe diarrhea without peritoneal signs should alert the clinician to include the possibility of a colocolocutaneous fistula in the differential diagnosis.<sup>9</sup> A lax mesentery in our patient may have al-

lowed the colon to drift anterior to the stomach and be pierced during the PEG tube reinsertion procedure.<sup>8</sup> Another possible explanation is that the PEG tube migrated after placement, leading to perforation and a fistulous connection.<sup>8</sup>

A mature fistulous tract usually develops by approximately 2 to 4 weeks after PEG tube placement. If there is dislodgment of the PEG tube after this time, it is usually possible to carefully reinsert a replacement tube blindly.<sup>3</sup> Should dislodgment occur less than 2 weeks after initial PEG tube placement, however, the fistulous track may not be well developed. A blindly inserted tube may be placed inadvertently into the peritoneal cavity rather than in the stomach, leading to disastrous results for the patient. In the event of an early postinsertion dislodgment, no attempt should be made to reinsert the PEG tube blindly. It is recommended that the tube be left out to allow the tract to heal. A repeat endoscopic insertion can be attempted 7 days later.<sup>3</sup>

In addition to complications associated with PEG tube placement, there are also potential problems related to incorrect PEG tube removal techniques. Physicians should be familiar with the type of PEG tube they are removing and the recommended removal method; ie, is it adequate to simply pull the tube out or is an endoscopic procedure required to remove the internal bumper, as with some older PEG tubes.<sup>10</sup> Attention to these details should prevent such removal complications.

Instillation of contrast material through the PEG tube may give a false-negative result. Although it was not done in this case, performing a barium enema is the test of choice for diagnosing a colocutaneous fistula.<sup>7</sup> Prevention of colocutaneous fistula formation in patients undergoing PEG tube placement consists mainly of taking a careful history before abdominal surgery.<sup>7</sup> Adhesions may hinder close approximation of the stomach to the abdominal wall.<sup>8</sup> Use of a needle inserted through the abdominal

wall at a well-transilluminated site perpendicular to the abdomen will decrease the likelihood of inadvertent colonic intubation.<sup>7</sup>

Management of a colocutaneous fistula is nonsurgical, unless peritonitis is present.<sup>5,7</sup> In the absence of peritonitis, the PEG tube is removed and the site is allowed to heal. Feeding is accomplished by means of a nasogastric feeding tube. Once healing has occurred, another PEG tube can be placed with EGD guidance, if possible.<sup>3,6</sup> Clinicians should consider colocutaneous fistula formation in their differential diagnosis as a possible cause of profuse diarrhea in a patient with a PEG tube.<sup>5</sup>

#### References

1. Gauderer M, Ponsky J, Izant R. Gastrostomy without laparotomy: a percutaneous endoscopic technique. *J Pediatr Surg* 1980; 15: 872-5.
2. Detailed diagnosis and procedures, National Hospital Discharge Survey, 1993. Vital and Health Statistics. US Department of Health and Human Services, October 1995, series 13, No.122:124.
3. Marshall J, Bodnarchuk G, Barthel J. Early accidental dislodgment of PEG tubes. *J Clin Gastroenterol* 1994; 18:210-2.
4. Larson D, Burton D, Schroeder K, DiMaggio E. Percutaneous endoscopic gastrostomy. Indications, success, complications, and mortality in 314 consecutive patients. *Gastroenterology* 1987; 93: 48-52.
5. Scapa E, Brode E, Slutzki S, Halvey A. Colocutaneous fistula. A rare complication of percutaneous endoscopic gastrostomy. *Surg Laparosc Endosc* 1993; 3:430-2.
6. Chia-Sing H, Yee A. Complications of surgical and percutaneous nonendoscopic gastrostomy. Review of 233 patients. *Gastroenterology* 1988; 95:1206-9.
7. Minocha A, Rupp T, Jagggers T, Rahal P. Silent cologastrocutaneous fistula as a complication of PEG. *Am J Gastroenterol* 1994; 89: 2243-4.
8. Saltzberg D, Anand K, Juvan P, Joffe I. Colocutaneous fistula: an unusual complication of PEG. *J Parenter Enteral Nutr* 1987; 11: 86-7.
9. Stefan M, Holcomb G III, Ross A III. Cologastric fistula as a complication of percutaneous endoscopic gastrostomy. *J Parenter Enteral Nutr* 1989; 13:554-6.
10. Mutabagani K, Townsend M, Arnold M. PEG ileus. A preventable complication. *Surg Endosc* 1994; 8:694-7.