

Why are there delays in the diagnosis of endometriosis?

👉 As leaders in women's health care, we can do much more to improve the timely diagnosis of endometriosis in women with pelvic pain



Robert L. Barbieri, MD

Editor in Chief, OBG MANAGEMENT
Chair, Obstetrics and Gynecology
Brigham and Women's Hospital, Boston, Massachusetts
Kate Macy Ladd Professor of Obstetrics,
Gynecology and Reproductive Biology
Harvard Medical School, Boston

Endometriosis is a common gynecologic problem in adolescents and women. It often presents with pelvic pain, an ovarian endometrioma, and/or subfertility. In a prospective study of 116,678 nurses, the incidence of a new surgical diagnosis of endometriosis was greatest among women aged 25 to 29 years and lowest among women older than age 44.¹ Using the incidence data from this study, the calculated prevalence of endometriosis in this large cohort of women of reproductive age was approximately 8%.

Although endometriosis is known to be a very common gynecologic problem, many studies report that there can be long delays between onset of pelvic pain symptoms and the diagnosis of endometriosis (FIGURE 1, page 10).²⁻⁶ Combining the results from 5 studies, involving 1,187 women, the mean age of onset of pelvic pain symptoms was 22.1 years, and the mean age at the diagnosis of endometriosis was 30.7 years. This is a difference of 8.6 years between the age of symptom onset and age at diagnosis.²⁻⁶

their clinician if endometriosis could be the cause of their severe dysmenorrhea and were told, "No."^{7,8}

Of interest, the reported delay in the diagnosis of endometriosis is much shorter for women who present with infertility than for women who present with pelvic pain. In one study from the United States, the delay to diagnosis was 3.13 years for women who presented with infertility and 6.35 years for women who presented with severe pelvic pain.³ This suggests that clinicians and patients more rapidly pursue the diagnosis of endometriosis in women with infertility, but not pelvic pain.

Instant Poll



Our readers want to know:
What are your clinical pearls for the timely diagnosis of endometriosis?

Tell us at
rbarbieri@frontlinemedcom.com
Please include your name and city and state.



What factors contribute to the diagnosis delay?

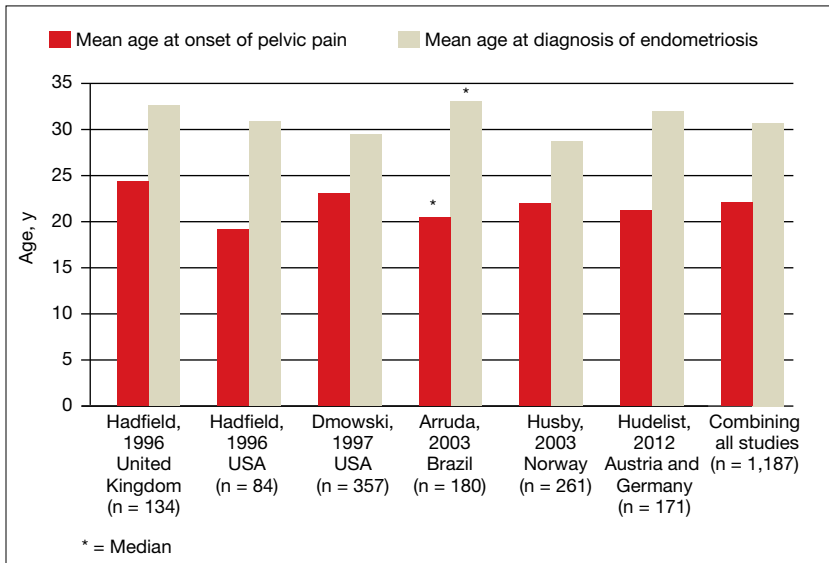
Both patient and physician factors contribute to the reported lengthy delay between symptom onset and endometriosis diagnosis.^{7,8} Differentiating dysmenorrhea due to primary and secondary causes is difficult for both patients and physicians. Women may conceal the severity of menstrual pain to avoid both the embarrassment of drawing attention to themselves and being stigmatized as unable to cope. Most disappointing is that many women with endometriosis reported that they asked

Initial treatment of pelvic pain with NSAIDs and estrogen–progestin contraceptives

Many women with undiagnosed endometriosis present with pelvic pain symptoms including moderate to severe dysmenorrhea. These women are often empirically treated with nonsteroidal anti-inflammatory drugs (NSAIDs) and combination estrogen–progestin contraceptives in either a cyclic or continuous manner.^{9,10} Since many women with endometriosis

CONTINUED ON PAGE 10

FIGURE 1 Women with pelvic pain and endometriosis report lengthy delays between the onset of symptoms of pelvic pain and the diagnosis of endometriosis²⁻⁶



will have a reduction in their pelvic pain with NSAID and contraceptive treatment, diagnosis of their endometriosis may be delayed until their disease progresses years after their initial presentation. It is important to gently alert these women to the possibility that they have undiagnosed endometriosis as the cause of their pain symptoms and encourage them to report any worsening pain symptoms in a timely manner.

Sometimes women with pelvic pain are treated with NSAIDs and contraceptives but no significant reduction in pain symptoms occurs. For these women, speedy consideration should be given to offering a laparoscopy to determine the cause of their pain.

Diagnosing endometriosis relies on identifying flags in the patient's history

The gold standard for endometriosis diagnosis is surgical visualization of endometriosis lesions, most often with laparoscopy, plus histologic

confirmation of endometriosis on a tissue biopsy.^{9,10} A key to reducing the time between onset of symptoms and diagnosis of endometriosis is identifying adolescents and women who are at high risk for having the disease. These women should be offered a laparoscopy procedure. In women with moderate to severe pelvic pain of at least 6 months duration, medical history, physical examination, and imaging studies can be helpful in identifying those at increased risk for endometriosis.

Items from the patient history that might raise the likelihood of endometriosis include:

- abdominopelvic pain, dysmenorrhea, menorrhagia, subfertility, dyspareunia and/or postcoital bleeding¹¹
- symptoms of dysmenorrhea and/or dyspareunia that are not responsive to NSAIDs or estrogen-progestin contraceptives¹²
- symptoms of dysmenorrhea and/or dyspareunia associated with absenteeism from school or work¹³
- multiple visits to the emergency

department for severe dysmenorrhea

- endometriosis in the patient's mother or sister
- subfertility with regular ovulation, patent fallopian tubes, and a partner with a normal semen analysis
- urinary frequency, urgency, and/or pain on urination
- diarrhea, constipation, nausea, dyschezia, bowel cramping, abdominal distention, and early satiety.

A daunting clinical challenge is that symptoms of endometriosis overlap with other gynecologic and nongynecologic problems including pelvic infection, adhesions, ovarian cysts, fibroids, irritable bowel syndrome, inflammatory bowel disease, interstitial cystitis, myofascial pain, depression, and history of sexual abuse.

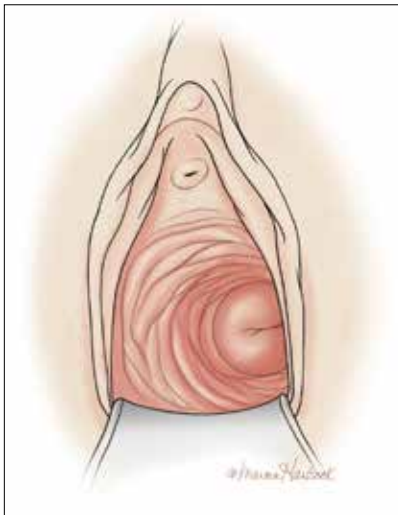
Diagnosing endometriosis relies on identifying flags on physical exam

Physical examination findings that raise the likelihood that the patient has endometriosis include:

- fixed and retroverted uterus
- adnexal mass
- lesions of the cervix or posterior fornix that visually appear to be endometriosis
- uterosacral ligament abnormalities, including tenderness, thickening, and/or nodularity^{14,15}
- lateral displacement of the cervix (FIGURE 2)^{16,17}
- severe cervical stenosis.

In one study of 57 women with a surgical diagnosis of endometriosis, uterosacral ligament abnormalities, lateral displacement of the cervix, and cervical stenosis were observed in 47%, 28%, and 19% of the women, respectively.¹⁷ In this same study 22 women had none of these findings, but 8 had a complex ovarian

FIGURE 2 Lateral displacement of the cervix



Lateral displacement of the cervix, which can be documented by visual examination of the cervix on speculum examination or by digital examination, is probably caused by the asymmetric involvement of one uterosacral ligament by endometriosis, causing one ligament to shorten and pull the cervix to that side of the body.

mass consistent with endometriosis.

The possibility of endometriosis increases as the number of history and physical examination findings suggestive of endometriosis increase.

When transvaginal ultrasound can aid diagnosis

Most women with endometriosis have normal transvaginal ultrasonography (TVUS) results because ultrasound cannot detect small

Key points for primary care physicians and patients

- Endometriosis is a common gynecologic disease. Approximately 8% of women of reproductive age have the condition.
- Many patients report lengthy delays between the onset of symptoms of pelvic pain and the diagnosis of endometriosis.
- Both patients and clinicians contribute to the delay in the diagnosis of endometriosis: Women are often reluctant to report the severity of their pelvic pain symptoms, and clinicians often under-respond to a patient's report of severe pelvic pain symptoms.
- First-line therapy for the treatment of moderate to severe dysmenorrhea is nonsteroidal anti-inflammatory drugs and estrogen-progestin contraceptives.
- Increasing vigilance for endometriosis will shorten the time between onset of symptoms and definitive diagnosis.
- Reducing the time between the onset of symptoms and diagnosis of endometriosis will improve the quality of life of women with the disease because they will receive timely treatment.

isolated peritoneal lesions of endometriosis present in Stage I disease, the most common stage of endometriosis. However, ultrasound is useful in detecting both ovarian endometriomas and nodules of deep infiltrating endometriosis (DIE).¹⁸ TVUS has excellent sensitivity (>90%) and specificity (>90%) for the detection of ovarian endometriomas because these cysts have characteristic, homogenous, low-level internal echoes.^{19,20} For the diagnosis of DIE of the uterosacral ligaments and rectovaginal septum, TVUS has fair sensitivity (>50%) and excellent specificity (>90%).²¹ In most studies, magnetic resonance imaging performs no better than TVUS for imaging ovarian endometriomas and DIE. Hence, TVUS is the preferred imaging modality for detecting endometriosis.²²

This is a practice gap we can close

Clinicians take great pride in accurately solving patient problems in a timely and efficient manner. Substantial research indicates that we can improve the timeliness of our diagnosis of endometriosis. By acknowledging patients' pain symptoms and recognizing the myriad symptoms and physical examination and imaging findings that are associated with endometriosis, we will close the gap and make this diagnosis with greater speed. 📌

RBARBIERI@FRONTLINEMEDCOM.COM

Dr. Barbieri reports no financial relationships relevant to this article.

References

1. Missmer SA, Hankinson SE, Spiegelman D, Barbieri RL, Marshall LM, Hunter DJ. Incidence of laparoscopically confirmed endometriosis by demographic, anthropometric, and lifestyle factors. *Am J Epidemiol.* 2004;160(8):784–796.
2. Hadfield R, Mardon H, Barlow D, Kennedy S. Delay in the diagnosis of endometriosis: a survey of women from the USA and UK. *Hum Reprod.* 1996;11(4):878–880.
3. Dmowski WP, Lesniewicz R, Rana N, Pepping P, Noursalehi M. Changing trends in the diagnosis of endometriosis: a comparative study of women with pelvic endometriosis presenting with chronic pelvic pain or infertility. *Fertil Steril.* 1997;67(2):238–243.
4. Arruda MS, Petta CA, Abrão MS, Benetti-Pinto CL. Time elapsed from onset of symptoms to diagnosis of endometriosis in a cohort study of Brazilian women. *Hum Reprod.* 2003;18(4):756–759.
5. Husby GK, Haugen RS, Moen MH. Diagnostic delay in women with pain and endometriosis. *Acta Obstet Gynecol Scand.* 2003;82(7):649–653.
6. Hudelist G, Fritzer N, Thomas A, et al. Diagnostic delay for endometriosis in Austria and Germany: causes and possible consequences. *Hum Reprod.* 2012;27(12):3412–3416.
7. Ballard K, Lowton K, Wright J. What's the delay?

CONTINUED ON PAGE 16

- A qualitative study of women's experiences of reaching a diagnosis of endometriosis. *Fertil Steril*. 2006;86(5):1296–1301.
8. Seear K. The etiquette of endometriosis: stigmatisation, menstrual concealment and the diagnostic delay. *Soc Sci Med*. 2009;69(8):1220–1227.
 9. Falcone T, Lebovic DI. Clinical management of endometriosis. *Obstet Gynecol*. 2011;118(3):691–705.
 10. American College of Obstetricians and Gynecologists. Practice Bulletin No. 114: Management of endometriosis. *Obstet Gynecol*. 2010;116(1):223–236.
 11. Ballard KD, Seaman HE, de Vries CS, Wright JT. Can symptomatology help in the diagnosis of endometriosis? Findings from a national case-control study—Part 1. *BJOG*. 2008;115(11):1382–1391.
 12. Steenberg CK, Tanbo TG, Qvigstad E. Endometriosis in adolescence: predictive markers and management. *Acta Obstet Gynecol Scand*. 2013;92(5):491–495.
 13. Zannoni L, Giorgi M, Spagnolo E, Montanari G, Villa G, Seracchioli R. Dysmenorrhea, absenteeism from school, and symptoms suspicious for endometriosis in adolescents. *J Pediatr Adolesc Gynecol*. 2014;27(5):258–265.
 14. Cheewadhanaraks S, Peeyananjarasri K, Dhana-woravibul K, Liabsuetrakul T. Positive predictive value of clinical diagnosis of endometriosis. *J Med Assoc Thai*. 2004;87(7):740–744.
 15. Guerriero S, Ajossa S, Gerada M, Virgilio B, Angioni S, Melis GB. Diagnostic value of transvaginal 'tenderness-guided' ultrasonography for the prediction of location of deep endometriosis. *Hum Reprod*. 2008;23(11):2452–2457.
 16. Propst AM, Storti K, Barbieri RL. Lateral cervical displacement is associated with endometriosis. *Fertil Steril*. 1998;70(3):568–570.
 17. Barbieri RL, Propst AM. Physical examination findings in women with endometriosis: uterosacral ligament abnormalities, lateral cervical displacement and cervical stenosis. *J Gynecol Techniques*. 1999;5:157–159.
 18. Guerriero S, Condous G, van den Bosch T, et al. Systematic approach to sonographic evaluation of the pelvis in women with suspected endometriosis, including terms, definitions and measurements: a consensus opinion from the International Deep Endometriosis Analysis (IDEA) group. *Ultrasound Obstet Gynecol*. 2016;48(3):318–332.
 19. Nisenblat V, Bossuyt PM, Farquhar C, Johnson N, Hull ML. Imaging modalities for the non-invasive diagnosis of endometriosis. *Cochrane Database Syst Rev*. 2016;2:CD009591.
 20. Somigliana E, Vercellini P, Vigano P, Benaglia L, Crosignani PG, Fedele L. Non-invasive diagnosis of endometriosis: the goal or own goal? *Hum Reprod*. 2010;25(8):1863–1868.
 21. Guerriero S, Ajossa S, Minguez JA, et al. Accuracy of transvaginal ultrasound for diagnosis of deep endometriosis in uterosacral ligaments, rectovaginal septum, vagina and bladder: systematic review and meta-analysis. *Ultrasound Obstet Gynecol*. 2015;46(5):534–545.
 22. Benacerraf BR, Groszmann Y. Sonography should be the first imaging examination done to evaluate patients with suspected endometriosis. *J Ultrasound Med*. 2012;31(4):651–653.